

# Guidelines for the Management of Traumatic Dental Injuries: 1. Fractures and Luxations of Permanent Teeth

## Originating Group

International Association of Dental Traumatology

## Endorsed by the American Academy of Pediatric Dentistry

2013

Anthony J. DiAngelis\*<sup>1</sup> • Jens O. Andreasen\*<sup>2</sup> • Kurt A. Ebeleseder\*<sup>3</sup> • David J. Kenny\*<sup>4</sup> • Martin Trope\*<sup>5</sup> • Asgeir Sigurdsson\*<sup>6</sup> • Lars Andersson<sup>7</sup> • Cecilia Bourguignon<sup>8</sup> • Marie Therese Flores<sup>9</sup> • Morris Lamar Hicks<sup>10</sup> • Antonio R. Lenzi<sup>11</sup> • Barbro Malmgren<sup>12</sup> • Alex J. Moule<sup>13</sup> • Yango Pohl<sup>14</sup> • Mitsuhiro Tsukiboshi<sup>15</sup>

**Abstract:** Traumatic dental injuries (TDIs) of permanent teeth occur frequently in children and young adults. Crown fractures and luxations are the most commonly occurring of all dental injuries. Proper diagnosis, treatment planning and followup are important for improving a favorable outcome. Guidelines should assist dentists and patients in decision making and for providing the best care effectively and efficiently. The International Association of Dental Traumatology (IADT) has developed a consensus statement after a review of the dental literature and group discussions. Experienced researchers and clinicians from various specialties were included in the group. In cases where the data did not appear conclusive, recommendations were based on the consensus opinion of the IADT board members. The guidelines represent the best current evidence based on literature search and professional opinion. The primary goal of these guidelines is to delineate an approach for the immediate or urgent care of TDIs. In this first article, the IADT Guidelines for management of fractures and luxations of permanent teeth will be presented. (*Dental Traumatology* 2012;28:2-12; doi: 10.1111/j.1600-9657.2011.01103.x) Accepted January 7, 2012.

KEYWORDS: CONSENSUS, FRACTURE, LUXATION, REVIEW, TRAUMA, TOOTH

<sup>1</sup>Department of Dentistry, Hennepin County Medical Center and University of Minnesota School of Dentistry, Minneapolis, MN, USA; <sup>2</sup>Center of Rare Oral Diseases, Department of Oral and Maxillofacial Surgery, Copenhagen University Hospital, Rigshospitalet, Denmark; <sup>3</sup>Department of Conservative Dentistry, Medical University Graz, Graz, Austria; <sup>4</sup>Hospital for Sick Children and University of Toronto, Toronto, Canada; <sup>5</sup>Department of Endodontics, School of Dentistry, University of Pennsylvania, Philadelphia, PA, USA; <sup>6</sup>Department of Endodontics, UNC School of Dentistry, Chapel Hill, NC, USA; <sup>7</sup>Department of Surgical Sciences, Faculty of Dentistry, Health Sciences Center Kuwait University, Kuwait City, Kuwait; <sup>8</sup>Private Practice, Paris, France; <sup>9</sup>Pediatric Dentistry, Faculty of Dentistry, Universidad de Valparaiso, Valparaiso, Chile; <sup>10</sup>Department of Endodontics, University of Maryland School of Dentistry, Baltimore, MD, USA; <sup>11</sup>Private Practice, Rio de Janeiro, Brazil; <sup>12</sup>Department of Clinical Sciences Intervention and Technology, Division of Pediatrics, Karolinska University Hospital, Stockholm, Sweden; <sup>13</sup>Private Practice, University of Queensland, Brisbane, Australia; <sup>14</sup>Department of Oral Surgery, University of Bonn, Bonn, Germany; <sup>15</sup>Private Practice, Amagun, Aichi, Japan.

Correspondence to Anthony J DiAngelis, DMD, MPH, Hennepin County Medical Center, 701 Park Avenue South, Minneapolis, MN 55415, USA.

Tel.: 612-873-6275.

Fax: 612-904-4234

e-mail: anthony.diangelis@hmed.org

\* Members of the Task Group.

Whenever referring to IADT Guidelines, the original article, (*Dent Traumatol* 2012;28:2-12) should always be used as reference.

Traumatic dental injuries (TDIs) occur with great frequency in preschool, school-age children, and young adults comprising 5% of all injuries for which people seek treatment (1, 2). A 12-year review of the literature reports that 25% of all school children experience dental trauma and 33% of adults have experienced trauma to the permanent dentition, with the majority of injuries occurring before age nineteen (3). Luxation injuries are the most common TDIs in the primary dentition, whereas crown fractures are more commonly reported for the permanent dentition (1, 4, 5) TDIs present a challenge to clinicians worldwide. Consequently, proper diagnosis, treatment planning and follow up are critical to assure a favorable outcome.

Guidelines, among other things, should assist dentists, other healthcare professionals, and patients in decision making. Also, they should be credible, readily understandable, and practical with the aim of delivering appropriate care as effectively and efficiently as possible.

The following guidelines by the International Association of Dental Traumatology (IADT) represent an updated set of guidelines based on the original guidelines published in 2007 (6-8). The update was accomplished by doing a review of the current dental literature using EMBASE, MEDLINE, and PUBMED searches from 1996 to 2011 as well as a search of the journal of Dental Traumatology from 2000 to 2011. Search words included tooth fractures, root fractures, tooth luxation, lateral luxation and permanent teeth, intruded permanent teeth, and luxated permanent teeth.

The primary goal of these guidelines is to delineate an approach for the immediate or urgent care of TDIs. It is understood that subsequent treatment may require secondary and tertiary interventions involving specialist consultations, services, and/or materials/methods not always available to the primary treating clinician.

The IADT published its first set of guidelines in 2001 and updated them in 2007 (6–13). As with the previous guidelines, the working group included experienced investigators and clinicians from various dental specialties and general practice. This revision represents the best evidence based on the available literature and expert professional judgment. In cases where the data did not appear conclusive, recommendations are based on the consensus opinion of the working group followed by review by the members of the IADT Board of Directors. It is understood that guidelines are to be applied with evaluation of the specific clinical circumstances, clinicians' judgment, and patients' characteristics, including but not limited to compliance, finances, and understanding of the immediate and long-term outcomes of treatment alternatives versus non-treatment. The IADT cannot and does not guarantee favorable outcomes from strict adherence to the Guidelines, but believe that their application can maximize the chances of a favorable outcome.

Guidelines undergo periodic updates. These 2012 Guidelines in this journal will appear in three parts:

Part I: Fractures and luxations of permanent teeth

Part II: Avulsion of permanent teeth

Part III: Injuries in the primary dentition

Guidelines offer recommendations for diagnosis and treatment of specific TDIs; however, they do not provide the comprehensive nor detailed information found in textbooks, the scientific literature, and, most recently, the Dental Trauma Guide (DTG) that can be accessed on <http://www.dentaltraumaguide.org>. Additionally, the DTG, also available on the IADT's web page <http://www.iadt-dentaltrauma.org>, provides a visual and animated documentation of treatment procedures as well as estimations of prognosis for the various TDIs.

## General recommendations/considerations

### Clinical examination

Detailed description of protocols, methods, and documentation for clinical assessment of TDIs can be found in current textbooks (1, 14, 15).

### Radiographic examination

Several projections and angulations are routinely recommended, but the clinician should decide which radiographs are required for the individual. The following are suggested:

- Periapical radiograph with a 90° horizontal angle with central beam through the tooth in question.
- Occlusal view.
- Periapical radiograph with lateral angulations from the mesial or distal aspect of the tooth in question.

Emerging imaging modalities such as cone-beam computerized tomography (CBCT) provide enhanced visualization of TDIs, particularly root fractures and lateral luxations, monitoring of healing, and complications. Availability is limited, and its use not currently considered routine; however, specific information is available in the scientific literature (16, 17).

## Splinting type and duration

Current evidence supports short-term, non-rigid splints for splinting of luxated, avulsed, and root-fractured teeth. While neither the specific type of splint nor the duration of splinting for root-fractured and luxated teeth are significantly related to healing outcomes, it is considered best practice to maintain the repositioned tooth in correct position, provide patient comfort and improved function (18, 19).

## Use of antibiotics

There is limited evidence for use of systemic antibiotics in the management of luxation injuries and no evidence that antibiotic coverage improves outcomes for root-fractured teeth. Antibiotic use remains at the discretion of the clinician as TDI's are often accompanied by soft tissue and other associated injuries, which may require other surgical intervention. In addition, the patient's medical status may warrant antibiotic coverage (19, 20).

## Sensibility tests

Sensibility testing refers to tests (cold test and/or electric pulp test) attempting to determine the condition of the pulp. At the time of injury, sensibility tests frequently give no response indicating a transient lack of pulpal response. Therefore, at least two signs and symptoms are necessary to make the diagnosis of necrotic pulp. Regular follow up controls are required to make a pulpal diagnosis.

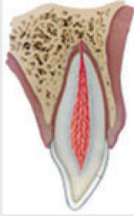

## Immature versus mature permanent teeth

Every effort should be made to preserve pulpal vitality in the immature permanent tooth to ensure continuous root development. The vast majority of TDIs occur in children and teenagers where loss of a tooth has lifetime consequences. The immature permanent tooth has considerable capacity for healing after traumatic pulp exposure, luxation injury, and root fractures. Pulp exposures secondary to TDIs are amenable to proven conservative pulp therapies that maintain vital pulp tissue and allow for continued root development (21–24). In addition, emerging therapies have demonstrated the ability to revascularize/regenerate vital tissue in canals of immature permanent teeth with necrotic pulps (25–30). Teeth frequently sustain a combination of several injuries. Studies have demonstrated that crown-fractured teeth with or without pulp exposure and associated luxation injury experience a greater frequency of pulp necrosis (31). The mature permanent tooth that sustains a severe TDI after which pulp necrosis is anticipated is amenable to preventive pulpectomy as root development is substantially completed.



## Pulp canal obliteration

Pulp canal obliteration (PCO) occurs more frequently in teeth with open apices which have suffered a severe luxation injury. It usually indicates ongoing pulpal vitality. Extrusion, intrusion, and lateral luxation injuries have high rates of PCO (32, 33). Subluxated and crown-fractured teeth also may exhibit PCO, although with less frequency (34). Additionally, PCO is a common occurrence following root fractures (35, 36).


Permanent teeth

1. Treatment guidelines for fractures of teeth and alveolar bone				Follow-up procedures for fractures of teeth and alveolar bone <sup>1</sup>	Favorable and unfavorable outcomes include some, but not necessarily all, of the following	
	Clinical findings	Radiographic findings	Treatment	Follow up	Favorable outcome	Unfavorable outcome
<p><b>Infraction</b></p> 	<ul style="list-style-type: none"> <li>An incomplete fracture (crack) of the enamel without loss of tooth structure</li> <li>Not tender. If tenderness is observed evaluate the tooth for a possible luxation injury or a root fracture</li> </ul>	<ul style="list-style-type: none"> <li>No radiographic abnormalities</li> <li>Radiographs recommended: a periapical view. Additional radiographs are indicated if other signs or symptoms are present</li> </ul>	<ul style="list-style-type: none"> <li>In case of marked infractions, etching and sealing with resin to prevent discoloration of the infraction lines; otherwise, no treatment is necessary</li> </ul>	<ul style="list-style-type: none"> <li>No follow up is generally needed for infraction injuries unless they are associated with a luxation injury or other fracture types</li> </ul>	<ul style="list-style-type: none"> <li>Asymptomatic</li> <li>Positive response to pulp testing</li> <li>Continuing root development in immature teeth</li> </ul>	<ul style="list-style-type: none"> <li>Symptomatic</li> <li>Negative response to pulp testing</li> <li>Signs of apical periodontitis</li> <li>No continuing root development in immature teeth</li> <li>Endodontic therapy appropriate for stage of root development is indicated</li> </ul>
<p><b>Enamel fracture</b></p> 	<ul style="list-style-type: none"> <li>A complete fracture of the enamel</li> <li>Loss of enamel. No visible sign of exposed dentin</li> <li>Not tender. If tenderness is observed, evaluate the tooth for a possible luxation or root fracture injury</li> <li>Normal mobility</li> <li>Sensibility pulp test usually positive</li> </ul>	<ul style="list-style-type: none"> <li>Enamel loss is visible</li> <li>Radiographs recommended: periapical, occlusal, and eccentric exposures. They are recommended in order to rule out the possible presence of a root fracture or a luxation injury</li> <li>Radiograph of lip or cheek to search for tooth fragments or foreign materials</li> </ul>	<ul style="list-style-type: none"> <li>If the tooth fragment is available, it can be bonded to the tooth</li> <li>Contouring or restoration with composite resin depending on the extent and location of the fracture</li> </ul>	<p>6–8 weeks C<sup>++</sup> 1 year C<sup>++</sup></p>	<ul style="list-style-type: none"> <li>Asymptomatic</li> <li>Positive response to pulp testing</li> <li>Continuing root development in immature teeth</li> <li>Continue to next evaluation</li> </ul>	<ul style="list-style-type: none"> <li>Symptomatic</li> <li>Negative response to pulp testing</li> <li>Signs of apical periodontitis</li> <li>No continuing root development in immature teeth</li> <li>Endodontic therapy appropriate for stage of root development is indicated</li> </ul>

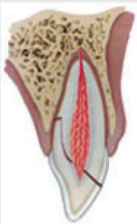
(Continued)

1. Treatment guidelines for fractures of teeth and alveolar bone				Follow-up procedures for fractures of teeth and alveolar bone <sup>1</sup>	Favorable and unfavorable outcomes include some, but not necessarily all, of the following	
	Clinical findings	Radiographic findings	Treatment	Follow up	Favorable outcome	Unfavorable outcome
<p><b>Enamel–dentin fracture</b></p> 	<ul style="list-style-type: none"> <li>• A fracture confined to enamel and dentin with loss of tooth structure, but not exposing the pulp</li> <li>• Percussion test: not tender. If tenderness is observed, evaluate the tooth for possible luxation or root fracture injury</li> <li>• Normal mobility</li> <li>• Sensibility pulp test usually positive</li> </ul>	<ul style="list-style-type: none"> <li>• Enamel–dentin loss is visible</li> <li>• Radiographs recommended: periapical, occlusal, and eccentric exposure to rule out tooth displacement or possible presence of root fracture</li> <li>• Radiograph of lip or cheek lacerations to search for tooth fragments or foreign materials</li> </ul>	<ul style="list-style-type: none"> <li>• If a tooth fragment is available, it can be bonded to the tooth. Otherwise, perform a <i>provisional treatment</i> by covering the exposed dentin with glass ionomer or a more permanent restoration using a bonding agent and composite resin, or other accepted dental restorative materials</li> <li>• If the exposed dentin is within 0.5 mm of the pulp (pink, no bleeding), place calcium hydroxide base and cover with a material such as a glass ionomer</li> </ul>	<p>6–8 weeks C<sup>++</sup> 1 year C<sup>++</sup></p>	<ul style="list-style-type: none"> <li>• Asymptomatic</li> <li>• Positive response to pulp testing</li> <li>• Continuing root development in immature teeth</li> <li>• Continue to next evaluation</li> </ul>	<ul style="list-style-type: none"> <li>• Symptomatic</li> <li>• Negative response to pulp testing</li> <li>• Signs of apical periodontitis</li> <li>• No continuing root development in immature teeth</li> <li>• Endodontic therapy appropriate for stage of root development is indicated</li> </ul>
<p><b>Enamel–dentin–pulp fracture</b></p> 	<ul style="list-style-type: none"> <li>• A fracture involving enamel and dentin with loss of tooth structure and exposure of the pulp.</li> <li>• Normal mobility</li> <li>• Percussion test: not tender. If tenderness is observed, evaluate for possible luxation or root fracture injury</li> <li>• Exposed pulp sensitive to stimuli</li> </ul>	<ul style="list-style-type: none"> <li>• Enamel–dentin loss visible</li> <li>• Radiographs recommended: periapical, occlusal, and eccentric exposures to rule out tooth displacement or possible presence of root fracture</li> <li>• Radiograph of lip or cheek lacerations to search for tooth fragments or foreign materials</li> </ul>	<ul style="list-style-type: none"> <li>• In young patients with immature, still developing teeth, it is advantageous to preserve pulp vitality by pulp capping or partial pulpotomy. Also, this treatment is the choice in young patients with completely formed teeth</li> <li>• Calcium hydroxide is a suitable material to be placed on the pulp wound in such procedures</li> <li>• In patients with mature apical development, root canal treatment is usually the treatment of choice, although pulp capping or partial pulpotomy also may be selected</li> <li>• If tooth fragment is available, it can be bonded to the tooth</li> <li>• Future treatment for the fractured crown may be restoration with other accepted dental restorative materials</li> </ul>	<p>6–8 weeks C<sup>++</sup> 1 year C<sup>++</sup></p>	<ul style="list-style-type: none"> <li>• Asymptomatic</li> <li>• Positive response to pulp testing</li> <li>• Continuing root development in immature teeth</li> <li>• Continue to next evaluation</li> </ul>	<ul style="list-style-type: none"> <li>• Symptomatic</li> <li>• Negative response to pulp testing</li> <li>• Signs of apical periodontitis</li> <li>• No continuing root development in immature teeth</li> <li>• Endodontic therapy appropriate for stage of root development is indicated</li> </ul>



(Continued)

1. Treatment guidelines for fractures of teeth and alveolar bone				Follow-up procedures for fractures of teeth and alveolar bone <sup>1</sup>	Favorable and unfavorable outcomes include some, but not necessarily all, of the following	
	Clinical findings	Radiographic findings	Treatment	Follow up	Favorable outcome	Unfavorable outcome
<p>Crown-root fracture without pulp exposure</p> 	<ul style="list-style-type: none"> <li>• A fracture involving enamel, dentin, and cementum with loss of tooth structure, but not exposing the pulp</li> <li>• Crown fracture extending below gingival margin</li> <li>• Percussion test: tender</li> <li>• Coronal fragment mobile</li> <li>• Sensibility pulp test usually positive for apical fragment</li> </ul>	<ul style="list-style-type: none"> <li>• Apical extension of fracture usually not visible</li> <li>• Radiographs recommended: periapical, occlusal, and eccentric exposures. They are recommended to detect fracture lines in the root</li> </ul>	<p>Emergency treatment</p> <ul style="list-style-type: none"> <li>• As an emergency treatment, a temporary stabilization of the loose segment to adjacent teeth can be performed until a definitive treatment plan is made</li> </ul> <p>Non-emergency treatment alternatives</p> <ul style="list-style-type: none"> <li>• Fragment removal only</li> <li>• Removal of the coronal crown-root fragment and subsequent restoration of the apical fragment exposed above the gingival level</li> <li>• Fragment removal and gingivectomy (sometimes ostectomy)</li> <li>• Removal of the coronal crown-root segment with subsequent endodontic treatment and restoration with a post-retained crown. This procedure should be preceded by a gingivectomy, and sometimes ostectomy with osteoplasty</li> <li>• Orthodontic extrusion of apical fragment</li> <li>• Removal of the coronal segment with subsequent endodontic treatment and orthodontic extrusion of the remaining root with sufficient length after extrusion to support a post-retained crown</li> <li>• Surgical extrusion</li> <li>• Removal of the mobile fractured fragment with subsequent surgical repositioning of the root in a more coronal position</li> <li>• Root submergence</li> <li>• Implant solution is planned</li> <li>• Extraction</li> <li>• Extraction with immediate or delayed implant-retained crown restoration or a conventional bridge.</li> </ul> <p>Extraction is inevitable in crown-root fractures with a severe apical extension, the extreme being a vertical fracture</p>	<p>6–8 weeks C<sup>++</sup> 1 year C<sup>++</sup></p>	<ul style="list-style-type: none"> <li>• Asymptomatic</li> <li>• Positive response to pulp testing</li> <li>• Continuing root development in immature teeth</li> <li>• Continue to next evaluation</li> </ul>	<ul style="list-style-type: none"> <li>• Symptomatic response to pulp testing</li> <li>• Signs of apical periodontitis</li> <li>• No continuing root development in immature teeth</li> <li>• Endodontic therapy appropriate for stage of root development is indicated</li> </ul>




(Continued)

1. Treatment guidelines for fractures of teeth and alveolar bone				Follow-up procedures for fractures of teeth and alveolar bone <sup>1</sup>	Favorable and unfavorable outcomes include some, but not necessarily all, of the following	
	Clinical findings	Radiographic findings	Treatment	Follow up	Favorable outcome	Unfavorable outcome
<p>Crown-root fracture with pulp exposure</p> 	<ul style="list-style-type: none"> <li>• A fracture involving enamel, dentin, and cementum and exposing the pulp</li> <li>• Percussion test: tender</li> <li>• Coronal fragment mobile</li> </ul>	<ul style="list-style-type: none"> <li>• Apical extension of fracture usually not visible</li> <li>• Radiographs recommended: periapical and occlusal exposure</li> </ul>	<p>Emergency treatment</p> <ul style="list-style-type: none"> <li>• As an emergency treatment a temporary stabilization of the loose segment to adjacent teeth</li> <li>• In patients with open apices, it is advantageous to preserve pulp vitality by a partial pulpotomy. This treatment is also the choice in young patients with completely formed teeth. Calcium hydroxide compounds are suitable pulp capping materials. In patients with mature apical development, root canal treatment can be the treatment of choice</li> </ul> <p>Non-Emergency Treatment Alternatives</p> <ul style="list-style-type: none"> <li>• Fragment removal and gingivectomy (sometimes ostectomy) Removal of the coronal fragment with subsequent endodontic treatment and restoration with a post-retained crown. This procedure should be preceded by a gingivectomy and sometimes ostectomy with osteoplasty. This treatment option is only indicated in crown-root fractures with palatal subgingival extension</li> <li>• Orthodontic extrusion of apical fragment Removal of the coronal segment with subsequent endodontic treatment and orthodontic extrusion of the remaining root with sufficient length after extrusion to support a post-retained crown</li> <li>• Surgical extrusion Removal of the mobile fractured fragment with subsequent surgical repositioning of the root in a more coronal position</li> <li>• Root submergence An implant solution is planned, the root fragment may be left <i>in situ</i></li> <li>• Extraction Extraction with immediate or delayed implant-retained crown restoration or a conventional bridge. Extraction is inevitable in very deep crown-root fractures, the extreme being a vertical fracture</li> </ul>	<p>6–8 weeks C<sup>++</sup> 1 year C<sup>++</sup></p>	<ul style="list-style-type: none"> <li>• Asymptomatic</li> <li>• Positive response to pulp testing</li> <li>• Continuing root development in immature teeth</li> <li>• Continue to next evaluation</li> </ul>	<ul style="list-style-type: none"> <li>• Symptomatic</li> <li>• Negative response to pulp testing</li> <li>• Signs of apical periodontitis</li> <li>• No continuing root development in immature teeth</li> <li>• Endodontic therapy appropriate for stage of root development is indicated</li> </ul>


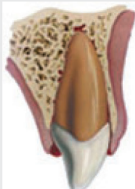
(Continued)

2. Treatment guidelines for luxation injuries				Follow-up procedures for luxated permanent teeth	Favorable and unfavorable outcomes include some, but not necessarily all, of the following <sup>2</sup>	
	Clinical findings	Radiographic findings	Treatment	Follow up	Favorable outcome	Unfavorable outcome
<p>Root fracture</p> 	<ul style="list-style-type: none"> <li>The coronal segment may be mobile and may be displaced</li> <li>The tooth may be tender to percussion</li> <li>Bleeding from the gingival sulcus may be noted</li> <li>Sensibility testing may give negative results initially, indicating transient or permanent neural damage</li> <li>Monitoring the status of the pulp is recommended</li> <li>Transient crown discoloration (red or gray) may occur</li> </ul>	<ul style="list-style-type: none"> <li>The fracture involves the root of the tooth and is in a horizontal or oblique plane</li> <li>Fractures that are in the horizontal plane can usually be detected in the regular periapical 90° angle film with the central beam through the tooth. This is usually the case with fractures in the cervical third of the root</li> <li>If the plane of fracture is more oblique, which is common with apical third fractures, an occlusal view or radiographs with varying horizontal angles is more likely to demonstrate the fracture including those located in the middle third</li> </ul>	<ul style="list-style-type: none"> <li>Reposition, if displaced, the coronal segment of the tooth as soon as possible</li> <li>Check position radiographically</li> <li>Stabilize the tooth with a flexible splint for 4 weeks. If the root fracture is near the cervical area of the tooth, stabilization is beneficial for a longer period of time (up to 4 months)</li> <li>It is advisable to monitor healing for at least 1 year to determine pulpal status</li> <li>If pulp necrosis develops, root canal treatment of the coronal tooth segment to the fracture line is indicated to preserve the tooth</li> </ul>	<p>4 weeks S<sup>+</sup>, C<sup>++</sup>                      6–8 weeks C<sup>++</sup>                      4 months S<sup>++</sup>, C<sup>++</sup>                      6 months C<sup>++</sup>                      1 year C<sup>++</sup>                      5 years C<sup>++</sup></p>	<ul style="list-style-type: none"> <li>Positive response to pulp testing (false negative possible up to 3 months)</li> <li>Signs of repair between fractured segments</li> <li>Continue to next evaluation</li> </ul>	<ul style="list-style-type: none"> <li>Symptomatic</li> <li>Negative response to pulp testing (false negative possible up to 3 months)</li> <li>Extrusion of the coronal segment</li> <li>Radiolucency at the fracture line</li> <li>Clinical signs of periodontitis or abscess associated with the fracture line</li> <li>Endodontic therapy appropriate for stage of root development is indicated</li> </ul>
<p>Alveolar fracture</p> 	<ul style="list-style-type: none"> <li>The fracture involves the alveolar bone and may extend to adjacent bone</li> <li>Segment mobility and dislocation with several teeth moving together are common findings</li> <li>An occlusal change because of misalignment the fractured alveolar segment is often noted</li> <li>Sensibility testing may or may not be positive</li> </ul>	<ul style="list-style-type: none"> <li>Fracture lines may be located at any level, from the marginal bone to the root apex</li> <li>In addition to the 3 angulations and occlusal film, additional views such as a panoramic radiograph can be helpful in determining the course and position of the fracture lines</li> </ul>	<ul style="list-style-type: none"> <li>Reposition any displaced segment and then splint</li> <li>Suture gingival laceration if present</li> <li>Stabilize the segment for 4 weeks</li> </ul>	<p>4 weeks S<sup>+</sup>, C<sup>++</sup>                      6–8 weeks C<sup>++</sup>                      4 months C<sup>++</sup>                      6 months C<sup>++</sup>                      1 year C<sup>++</sup>                      5 years C<sup>++</sup></p>	<ul style="list-style-type: none"> <li>Positive response to pulp testing (false negative possible up to 3 months)</li> <li>No signs of apical periodontitis</li> <li>Continue to next evaluation</li> </ul>	<ul style="list-style-type: none"> <li>Symptomatic</li> <li>Negative response to pulp testing (false negative possible up to 3 months)</li> <li>Signs of apical periodontitis or external inflammatory root resorption</li> <li>Endodontic therapy appropriate for stage of root development is indicated</li> </ul>

(Continued)

2. Treatment guidelines for luxation injuries				Follow-up procedures for luxated permanent teeth	Favorable and unfavorable outcomes include some, but not necessarily all, of the following <sup>2</sup>	
	Clinical findings	Radiographic findings	Treatment	Follow up	Favorable outcome	Unfavorable outcome
<p><b>Concussion</b></p> 	<ul style="list-style-type: none"> <li>The tooth is tender to touch or tapping; it has not been displaced and does not have increased mobility</li> <li>Sensibility tests are likely to give positive results</li> </ul>	<ul style="list-style-type: none"> <li>No radiographic abnormalities</li> </ul>	<ul style="list-style-type: none"> <li>No treatment is needed</li> <li>Monitor pulpal condition for at least 1 year</li> </ul>	<p>4 weeks C<sup>++</sup> 6–8 weeks C<sup>++</sup> 1 year C<sup>++</sup></p>	<ul style="list-style-type: none"> <li>Asymptomatic</li> <li>Positive response to pulp testing</li> <li>False negative possible up to 3 months</li> <li>Continuing root development in immature teeth</li> <li>Intact lamina dura</li> </ul>	<ul style="list-style-type: none"> <li>Symptomatic</li> <li>Negative response to pulp testing</li> <li>False negative possible up to 3 months</li> <li>No continuing root development in immature teeth, signs of apical periodontitis</li> <li>Endodontic therapy appropriate for stage of root development is indicated</li> </ul>
<p><b>Subluxation</b></p> 	<ul style="list-style-type: none"> <li>The tooth is tender to touch or tapping and has increased mobility; it has not been displaced</li> <li>Bleeding from gingival crevice may be noted</li> <li>Sensibility testing may be negative initially indicating transient pulpal damage</li> <li>Monitor pulpal response until a definitive pulpal diagnosis can be made</li> </ul>	<ul style="list-style-type: none"> <li>Radiographic abnormalities are usually not found</li> </ul>	<ul style="list-style-type: none"> <li>Normally no treatment is needed; however, a flexible splint to stabilize the tooth for patient comfort can be used for up to 2 weeks</li> </ul>	<p>2 weeks S<sup>+</sup>, C<sup>++</sup> 4 weeks C<sup>++</sup> 6–8 weeks C<sup>++</sup> 6 months C<sup>++</sup> 1 year C<sup>++</sup></p>	<ul style="list-style-type: none"> <li>Asymptomatic</li> <li>Positive response to pulp testing</li> <li>False negative possible up to 3 months</li> <li>Continuing root development in immature teeth</li> <li>Intact lamina dura</li> </ul>	<ul style="list-style-type: none"> <li>Symptomatic</li> <li>Negative response to pulp testing</li> <li>False negative possible up to 3 months</li> <li>External inflammatory resorption</li> <li>No continuing root development in immature teeth, signs of apical periodontitis</li> <li>Endodontic therapy appropriate for stage of root development is indicated</li> </ul>
<p><b>Extrusive luxation</b></p> 	<ul style="list-style-type: none"> <li>The tooth appears elongated and is excessively mobile</li> <li>Sensibility tests will likely give negative results</li> </ul>	<ul style="list-style-type: none"> <li>Increased periodontal ligament space apically</li> </ul>	<ul style="list-style-type: none"> <li>Reposition the tooth by gently re-inserting it into the tooth socket</li> <li>Stabilize the tooth for 2 weeks using a flexible splint</li> <li>In mature teeth where pulp necrosis is anticipated or if several signs and symptoms indicate that the pulp of mature or immature teeth became necrotic, root canal treatment is indicated</li> </ul>	<p>2 weeks S<sup>+</sup>, C<sup>++</sup> 4 weeks C<sup>++</sup> 6–8 weeks C<sup>++</sup> 6 months C<sup>++</sup> 1 year C<sup>++</sup> Yearly 5 years C<sup>++</sup></p>	<ul style="list-style-type: none"> <li>Asymptomatic</li> <li>Clinical and radiographic signs of normal or healed periodontium</li> <li>Positive response to pulp testing (false negative possible up to 3 months)</li> <li>Marginal bone height corresponds to that seen radiographically after repositioning</li> <li>Continuing root development in immature teeth</li> </ul>	<ul style="list-style-type: none"> <li>Symptoms and radiographic sign consistent with apical periodontitis</li> <li>Negative response to pulp testing (false negative possible up to 3 months)</li> <li>If breakdown of marginal bone, splint for an additional 3–4 weeks</li> <li>External inflammatory root resorption</li> <li>Endodontic therapy appropriate for stage of root development is indicated</li> </ul>

(Continued)

2. Treatment guidelines for luxation injuries				Follow-up procedures for luxated permanent teeth	Favorable and unfavorable outcomes include some, but not necessarily all, of the following <sup>2</sup>	
	Clinical findings	Radiographic findings	Treatment	Follow up	Favorable outcome	Unfavorable outcome
 <p><b>Lateral Luxation</b></p> <ul style="list-style-type: none"> <li>The tooth is displaced, usually in a palatal/lingual or labial direction</li> <li>It will be immobile and percussion usually gives a high, metallic (ankylotic) sound</li> <li>Fracture of the alveolar process present</li> <li>Sensibility tests will likely give negative results</li> </ul>	<ul style="list-style-type: none"> <li>The widened periodontal ligament space is best seen on eccentric or occlusal exposures</li> </ul>	<ul style="list-style-type: none"> <li>Reposition the tooth digitally or with forceps to disengage it from its bony lock and gently reposition it into its original location</li> <li>Stabilize the tooth for 4 weeks using a flexible splint</li> <li>Monitor the pulpal condition</li> <li>If the pulp becomes necrotic, root canal treatment is indicated to prevent root resorption</li> </ul>	<ul style="list-style-type: none"> <li>2 weeks S<sup>+</sup>, C<sup>++</sup></li> <li>4 weeks C<sup>++</sup></li> <li>6–8 weeks C<sup>++</sup></li> <li>6 months C<sup>++</sup></li> <li>1 year C<sup>++</sup></li> <li>Yearly for 5 years C<sup>++</sup></li> </ul>	<ul style="list-style-type: none"> <li>Asymptomatic</li> <li>Clinical and radiographic signs of normal or healed periodontium</li> <li>Positive response to pulp testing (false negative possible up to 3 months)</li> <li>Marginal bone height corresponds to that seen radiographically after repositioning</li> <li>Continuing root development in immature teeth</li> </ul>	<ul style="list-style-type: none"> <li>Symptoms and radiographic signs consistent with apical periodontitis</li> <li>Negative response to pulp testing (false negative possible up to 3 months)</li> <li>If breakdown of marginal bone, splint for an additional 3–4 weeks</li> <li>External inflammatory root resorption or replacement resorption</li> <li>Endodontic therapy appropriate for stage of root development is indicated</li> </ul>	
 <p><b>Intrusive luxation</b></p> <ul style="list-style-type: none"> <li>The tooth is displaced axially into the alveolar bone</li> <li>It is immobile, and percussion may give a high, metallic (ankylotic) sound</li> <li>Sensibility tests will likely give negative results</li> </ul>	<ul style="list-style-type: none"> <li>The periodontal ligament space may be absent from all or part of the root</li> <li>The cemento-enamel junction is located more apically in the intruded tooth than in adjacent non-injured teeth, at times even apical to the marginal bone level</li> </ul>	<p>Teeth with incomplete root formation</p> <ul style="list-style-type: none"> <li>Allow eruption without intervention</li> <li>If no movement within few weeks, initiate orthodontic repositioning</li> <li>If tooth is intruded more than 7 mm, reposition surgically or orthodontically</li> </ul> <p>Teeth with complete root formation</p> <ul style="list-style-type: none"> <li>Allow eruption without intervention if tooth intruded less than 3 mm. If no movement after 2–4 weeks, reposition surgically or orthodontically before ankylosis can develop</li> <li>If tooth is intruded beyond 7 mm, reposition surgically</li> <li>The pulp will likely become necrotic in teeth with complete root formation. Root canal therapy using a temporary filling with calcium hydroxide is recommended and treatment should begin 2–3 weeks after surgery</li> <li>Once an intruded tooth has been repositioned surgically or orthodontically, stabilize with a flexible splint for 4–8 weeks</li> </ul>	<ul style="list-style-type: none"> <li>2 weeks S<sup>+</sup>, C<sup>++</sup></li> <li>4 weeks C<sup>++</sup></li> <li>6–8 weeks C<sup>++</sup></li> <li>6 months C<sup>++</sup></li> <li>1 year C<sup>++</sup></li> <li>Yearly for 5 years C<sup>++</sup></li> </ul>	<ul style="list-style-type: none"> <li>Tooth in place or erupting</li> <li>Intact lamina dura</li> <li>No signs of resorption</li> <li>Continuing root development in immature teeth</li> </ul>	<ul style="list-style-type: none"> <li>Tooth locked in place/ankylotic tone to percussion</li> <li>Radiographic signs of apical periodontitis</li> <li>External inflammatory root resorption or replacement resorption</li> <li>Endodontic therapy appropriate for stage of root development is indicated</li> </ul>	

C<sup>++</sup>, clinical and radiographic examination; S<sup>+</sup>, splint removal; S<sup>++</sup>, splint removal in cervical third fractures.

<sup>1</sup>For crown-fractured teeth with concomitant luxation injury, use the luxation follow-up schedule.

<sup>2</sup>Whenever there is evidence of external inflammatory root resorption, root canal therapy should be initiated immediately, with the use of calcium hydroxide as an intra-canal medication.

### Patient instructions

Patient compliance with follow-up visits and home care contributes to better healing following a TDI. Both patients and parents of young patients should be advised regarding care of the injured tooth/teeth for optimal healing, prevention of further injury by avoidance of participation in contact sports, meticulous oral hygiene, and rinsing with an antibacterial such as chlorhexidine gluconate 0.1% alcohol free for 1–2 weeks.

### Additional resources

Besides the general recommendations mentioned earlier, clinicians are encouraged to access the DTG, the journal *Dental Traumatology*, and other journals for information pertaining to treatment delay (37), intrusive luxations (38–47), root fractures (48–52), pulpal management of fractured and luxated teeth (34, 53–64, splinting (18, 39, 65–68), and antibiotics (69).

### Acknowledgements

IADT is grateful to the team of Dental Trauma Guide [www.dentaltraumaguide.org](http://www.dentaltraumaguide.org) for kindly providing pictures to the article.

### References

- Andreasen JO, Andreasen FM, Andersson L. Textbook and color atlas of traumatic injuries to the teeth, 4th edn. Oxford, UK: Wiley-Blackwell; 2007.
- Petersson EE, Andersson L, Sorensen S. Traumatic oral vs non-oral injuries. *Swed Dent J* 1997;21:55–68.
- Glendor U. Epidemiology of traumatic dental injuries – a 12 year review of the literature. *Dent Traumatol* 2008;24:603–11.
- Flores MT. Traumatic injuries in the primary dentition. *Dent Traumatol* 2002;18:287–98.
- Kramer PF, Zembruski C, Ferreira SH, Feldens CA. Traumatic dental injuries in Brazilian preschool children. *Dent Traumatol* 2003;19:299–303.
- Flores MT, Andersson L, Andreasen JO, Bakland LK, Malmgren B, Barnett F et al. Guidelines for the management of traumatic dental injuries. 1. Fractures and luxations of permanent teeth. *Dent Traumatol* 2007;23:66–71.
- Flores MT, Andersson L, Andreasen JO, Bakland LK, Malmgren B, Barnett F et al. Guidelines for the management of traumatic dental injuries. 11. Avulsion of permanent teeth. *Dent Traumatol* 2007;23:130–6.
- Flores MT, Malmgren B, Andersson L, Andreasen JO, Bakland LK, Barnett F et al. Guidelines for the management of traumatic dental injuries. 111. Primary Teeth. *Dent Traumatol* 2007;23:196–202.
- Flores MT, Andreasen JO, Bakland LK, Feiglin B, Gutmann JL, Oikarinen K et al. Guidelines for the evaluation and management of traumatic dental injuries (part 1 of the series). *Dent Traumatol* 2001;17:1–4.
- Flores MT, Andreasen JO, Bakland LK, Feiglin B, Gutmann JL, Oikarinen K et al. Guidelines for the evaluation and management of traumatic dental injuries (part 2 of the series). *Dent Traumatol* 2001;17:49–52.
- Flores MT, Andreasen JO, Bakland LK, Feiglin B, Gutmann JL, Oikarinen K et al. Guidelines for the evaluation and management of traumatic dental injuries (part 3 of the series). *Dent Traumatol* 2001;17:97–102.
- Flores MT, Andreasen JO, Bakland LK, Feiglin B, Gutmann JL, Oikarinen K et al. Guidelines for the evaluation and management of traumatic dental injuries (part 4 of the series). *Dent Traumatol* 2001;17:145–8.
- Flores MT, Andreasen JO, Bakland LK, Feiglin B, Gutmann JL, Oikarinen K et al. Guidelines for the evaluation and management of traumatic dental injuries (part 5 of the series). *Dent Traumatol* 2001;17:193–8.
- Andreasen JO, Bakland LK, Flores MT, Andreasen FM. Traumatic dental injuries: a manual, 3rd edn. Chichester, West Sussex: Wiley-Blackwell; 2011.
- Pinkham JR, Casamassino PS, Fields HW Jr, McTigue DJ, Mowak A editors. *Pediatric dentistry*, 4th edn. St. Louis, MO: Elsevier Saunders; 2005.
- Cohenca M, Simon JH, Roges R, Morag Y, Malfax JM. Clinical Indications for digital imaging in dento-alveolar trauma. Part I: traumatic injuries. *Dent Traumatol* 2007;23:95–104.
- Cohenca N, Simon JH, Mathur A, Malfax JM. Clinical Indications for digital imaging in dento-alveolar trauma. Part 2: root resorption. *Dent Traumatol* 2007;23:105–13.
- Kahler B, Heithersay GS. An evidence-based appraisal of splinting luxated, avulsed and root-fractured teeth. *Dent Traumatol* 2008;24:2–10.
- Andreasen JO, Andreasen FM, Mejarić I, Cvek M. Healing of 400 intra-alveolar root fractures 2. Effect of treatment factors such as treatment delay, repositioning, splinting type and period and antibiotics. *Dent Traumatol* 2004;20:203–11.
- Hinckfuss SE, Messer LB. An evidence-based assessment of the clinical guidelines for replanted avulsed teeth. Part II: prescription of systemic antibiotics. *Dent Traumatol* 2009;25:158–64.
- Cvek M. A clinical report on partial pulpotomy and capping with calcium hydroxide in permanent incisors with complicated crown fractures. *J Endod* 1978;4:232–7.
- Fuks AB, Bielak S, Chosak A. Clinical and radiographic assessment of direct pulp capping and pulpotomy in young permanent teeth. *Pediatr Dent* 1982;4:240–4.
- Olsburgh S, Jacoby T, Krejci I. Crown fractures in the permanent dentition: pulpal and restorative considerations. *Dent Traumatol* 2002;18:103–15.
- Witherspoon DE. Vital pulp therapy with new materials: new directions and treatment perspectives – permanent teeth. *Pediatr Dent* 2008;30:220–4.
- Huang GT. A paradigm shift in endodontic management of immature teeth: conservation of stem cells for regeneration. *J Dent* 2008;36:379–86. Epub 16 April 2008.
- Chueh LH, Ho YC, Kuo TC, Lai WH, Chen YH, Chiang CP. Regenerative endodontic treatment for necrotic immature permanent teeth. *J Endod* 2009;35:160–4. Epub 12 December 2008.
- Bose R, Nummikoski P, Hargreaves K. A retrospective evaluation of radiographic outcomes in immature teeth with necrotic root canal systems treated with regenerative endodontic procedures. *J Endod* 2009;35:1343–9. Epub 15 August 2009.
- Thibodeau B, Trope M. Pulp revascularization of a necrotic infected immature permanent tooth: case report and review of the literature. *Pediatr Dent* 2007;29:47–50.
- Trope M. Treatment of the immature tooth with a non-vital pulp and apical periodontitis. *Dent Clin North Am* 2010;54:313–24.
- Jung IY, Lee SJ, Hargreaves KM. Biologically based treatment of immature permanent teeth with pulpal necrosis: a case series. *J Endod* 2008;34:876–87. Epub 16 May 2008.
- Robertson A, Andreasen FM, Andreasen JO, Noren JG. Long-term prognosis of crown-fractured permanent incisors. The effect of stage of root development and associated luxation injuries. *Int J Paediatr Dent* 2000;103:191–9.
- Holcomb JB, Gregory WB Jr. Calcific metamorphosis of the pulp; its incidence and treatment. *Oral Surg Oral Med Oral Pathol* 1967;24:825–30.
- Neto JJ, Gondim JO, deCarvalho FM, Giro EM. Longitudinal clinical and radiographic evaluations of severely intruded permanent incisors in a pediatric population. *Dent Traumatol* 2009;25:510–24.
- Robertson A. A retrospective evaluation of patients with uncomplicated crown fractures and luxation injuries. *Endod Dent Traumatol* 1998;14:245–56.

35. Amir FA, Gutmann JL, Witherspoon DE. Calcific metamorphosis: a challenge in endodontic diagnosis and treatment. *Quintessence Int* 2001;32:447–55.
36. Andreasen FM, Andreasen JO, Bayer T. Prognosis of root fractured permanent incisors; prediction of healing modalities. *Endod Dent Traumatol* 1989;5:11–22.
37. Andreasen JO, Andreasen FM, Skeie A, Hjørting-Hansen E, Schwartz O. Effect of treatment delay upon pulp and periodontal healing of traumatic dental injuries – a review article. *Dent Traumatol* 2002;18:116–28.
38. Andreasen JO, Bakland LK, Andreasen FM. Traumatic intrusion of permanent teeth. Part 3. A clinical study of the effect of treatment variables such as treatment delay, method of repositioning, type of splint, length of splinting and antibiotics on 140 teeth. *Dent Traumatol* 2006;22:99–111.
39. Kenny DJ, Barrett EJ, Casas MJ. Avulsions and Intrusions: the controversial displacement injuries. *J Can Dent Assoc* 2003;69:308–13.
40. Stewart C, Dawson M, Phillips J, Shafi I, Kinirons M, Welburg R. A study of the management of 55 traumatically intruded permanent incisor teeth in children. *Eur Arch Paediatr Dent* 2009;10:25–8.
41. Albadri S, Zaitoun H, Kinirons MJ. UK National Clinical Guidelines in Paediatric Dentistry: treatment of traumatically intruded permanent incisor teeth in children. *Int. J Pediatr Dent* 2010;20(Suppl 1):1–2.
42. Andreasen JO, Bakland LK, Matras RC, Andreasen FM. Traumatic intrusion of permanent teeth. Part 1. An epidermiological study of 216 intruded permanent teeth. *Dent Traumatol* 2006;22:83–9.
43. Andreasen JO, Bakland LK, Andreasen FM. Traumatic intrusion of permanent teeth. Part 2. A clinical study of the effect of preinjury and injury factors such as sex, age, stage of root development, tooth location and extent of injury including number of intruded teeth on 140 intruded permanent teeth. *Dent Traumatol* 2006;22:90–8.
44. Wiggen TI, Agnalt R, Jacobsen I. Intrusive luxation of permanent incisors in Norwegians aged 6–17 years: a retrospective study of treatment and outcome. *Dent Traumatol* 2008;24:612–8.
45. Ebeleseder KA, Santler G, Glockner K, Huller H, Perfl C, Quehenberger F. An analysis of 58 traumatically intruded and surgically extruded permanent teeth. *Dent Traumatol* 2000;16:34–9.
46. Humphrey JM, Kenny DJ, Barrett EJ. Clinical outcomes for permanent incisor luxations in a pediatric population. I. Intrusions. *Dent Traumatol* 2003;19:266–73.
47. Al Badri S, Kinirons M, Cole B, Welbury R. Factors affecting resorption in traumatically intruded permanent incisors in children. *Dent Traumatol* 2002;18:73–6.
48. Andreasen JO, Andreasen FM, Mejare I, Cvek M. Healing of 400 intra-alveolar root fractures. I. Effect of pre-injury and injury factors such as sex, age, stage of root development, fracture type, location of fracture and severity of dislocation. *Dent Traumatol* 2004;20:192–202.
49. Cvek M, Andreasen JO, Borum MK. Healing of 208 intra-alveolar root fractures in patients aged 7–17 years. *Dent Traumatol* 2001;17:53–62.
50. Welbury RR, Kinirons MJ, Day P, Humphreys K, Gregg TA. Outcomes for root-fractured permanent incisors; a retrospective study. *Pediatr Dent* 2002;24:98–102.
51. Cvek M, Mejare I, Andreasen JO. Healing and prognosis of teeth with intra-alveolar fractures involving the cervical part of the root. *Dent Traumatol* 2002;18:57–65.
52. Cvek M, Tsilingaridis G, Andreasen JO. Survival of 534 incisors after intra-alveolar root fracture in 7–17 years. *Dent Traumatol* 2008;24:379–87.
53. Farsi N, Alamoudi N, Balto K, Al Muskagy A. Clinical assessment of mineral trioxide aggregate (MTA) as direct pulp capping in young permanent teeth. *J Clin Pediatr Dent* 2006;31:72–6.
54. Moule AJ, Moule CA. The endodontic management of traumatized anterior teeth: a review. *Aust Dent J* 2007;52(Suppl 1):S122–37.
55. Bakland LK. Revisiting traumatic pulpal exposure: materials, management principles and techniques. *Dent Clin N Am* 2009;53:661–73.
56. Cavalleri G, Zerman N. Traumatic crown fractures in permanent incisors with immature roots: a follow-up study. *Endod Dent Traumatol* 1995;11:294–6.
57. Ferrazzini Pozzi EC, von Arx T. Pulp and periodontal healing of laterally luxated permanent teeth; results after 4 years. *Dent Traumatol* 2008;24:658–62.
58. Nikoui M, Kenny DJ, Barrett EJ. Clinical outcomes for permanent incisor luxation in a pediatric population. III. Lateral luxations. *Dent Traumatol* 2003;19:280–5.
59. Jackson NG, Waterhouse PJ, Maguire A. Factors affecting treatment outcomes following complicated crown fractures managed in primary and secondary care. *Dent Traumatol* 2006;22:179–85.
60. About I, Murray PE, Franquin JC, Remusat M, Smith AJ. The effect of cavity restoration variables on odontoblast cell numbers and dental repair. *J Dent* 2001;29:109–17.
61. Murray PE, Smith AJ, Windsor LJ, Mjor IA. Remaining dentine thickness and human pulp responses. *Int Endod J* 2003;36:33–43.
62. Subay RK, Demirci M. Pulp tissue reactions to a dentin bonding agent as a direct capping agent. *J Endod* 2005;31:201–4.
63. Bogen G, Kim JS, Bakland LK. Direct pulp capping with mineral trioxide aggregate: an observational study. *J Am Dent Assoc* 2008;139:305–15.
64. Cvek M, Mejare I, Andreasen JO. Conservative endodontic treatment in the middle or apical part of the root. *Dent Traumatol* 2004;20:261–9.
65. Hinckfuss S, Messer LB. Splinting duration and periodontal outcomes for replanted avulsed teeth, a systematic review. *Dent Traumatol* 2009;25:150–7.
66. Oikarinen K. Tooth Splinting – a review of the literature and consideration of the versatility of a wire-composite splint. *Endod Dent Traumatol* 1990;6:237–50.
67. VonArx T, Fillipi A, Lussi A. Comparison of a new dental trauma splint device (TTS) with three commonly used splinting techniques. *Dent Traumatol* 2001;17:266–74.
68. Berthold C, Thaler A, Petschelt A. Rigidity of commonly used dental trauma splints. *Dent Traumatol* 2009;25:248–55.
69. Andreasen JO, Storgaard Jensen S, Sae-Lim V. The role of antibiotics in presenting healing complications after traumatic dental injuries: a literature review. *Endod Topics* 2006;14:80–92.

## Corrigendum

### Dent Traumatol 2012;28:499

In DiAngelis et al. (1), the following corrections should be made:

Under the heading 'Follow up' for both lateral luxation and intrusion, the first two time periods should be read as:

- 2 weeks, C++ (not 2 weeks S+, C++)
- 4 weeks S+, C++ (not 4 weeks C++)

This makes splint removal at 4 weeks consistent with what is recommended under 'Treatment'.

Under 'Treatment', 'Teeth with complete root formation', there should be an additional second bullet to read as:

- if tooth is intruded 3–7 mm, reposition surgically or orthodontically

The last word in the fourth bulleted sentence should be repositioning instead of surgery.

The authors would like to apologize for these errors.

### Reference

1. DiAngelis AJ, Andreasen JO, Ebeleseder KA et al. International Association of Dental Traumatology guidelines for the management of traumatic dental injuries: 1. Fractures and luxations of permanent teeth. *Dent Traumatol* 2012; 28:2–12.