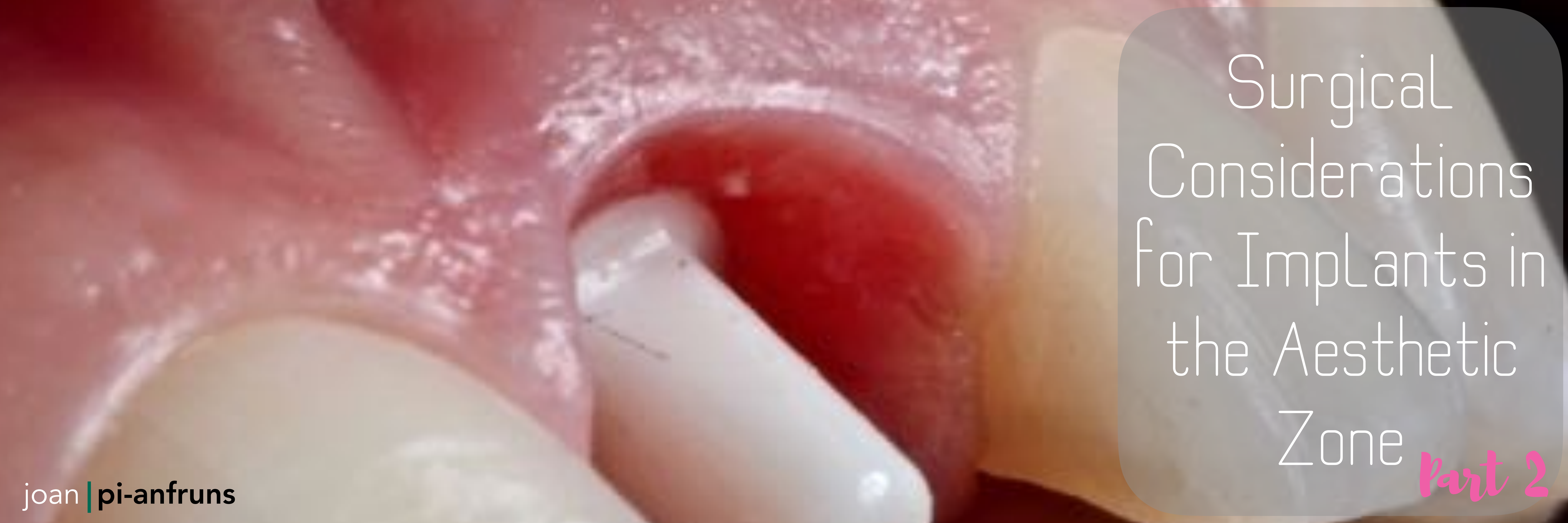



Surgical
Considerations
for Implants in
the Aesthetic
Zone
Part 2



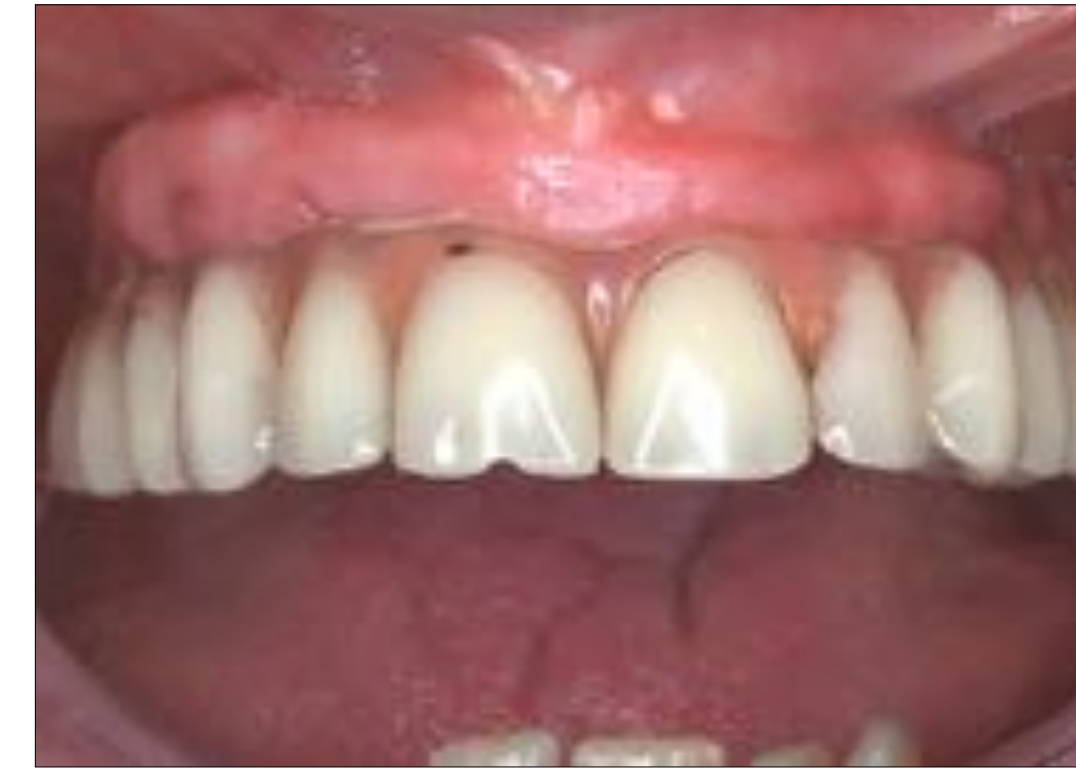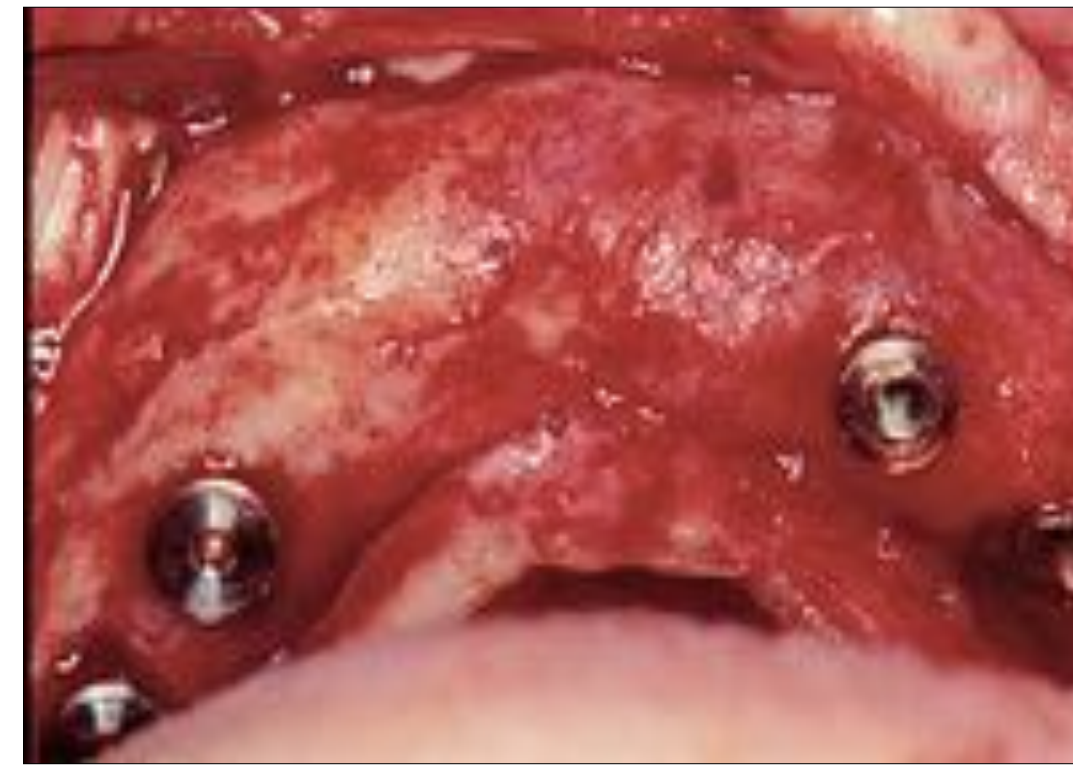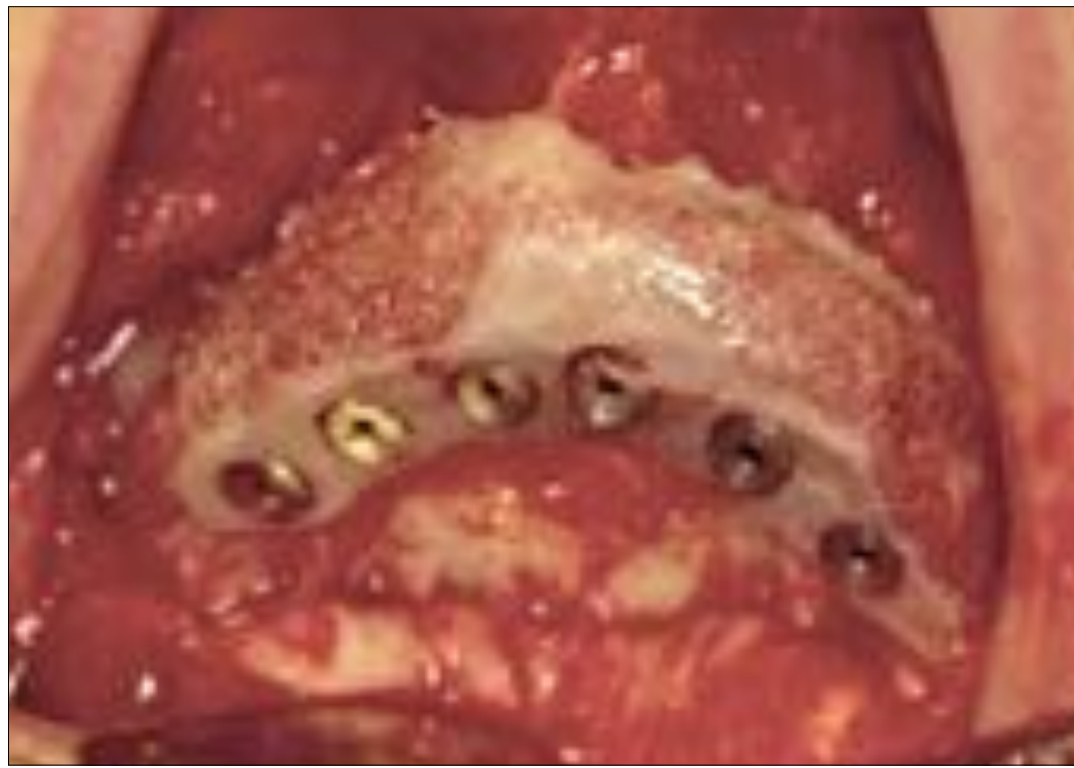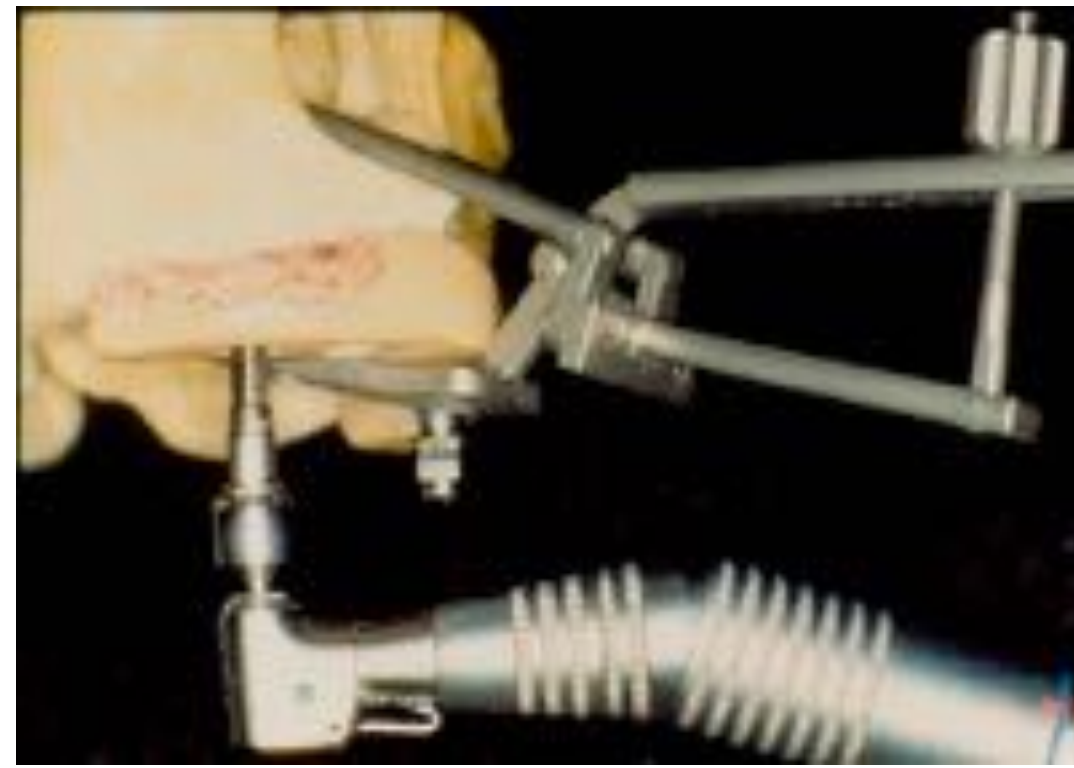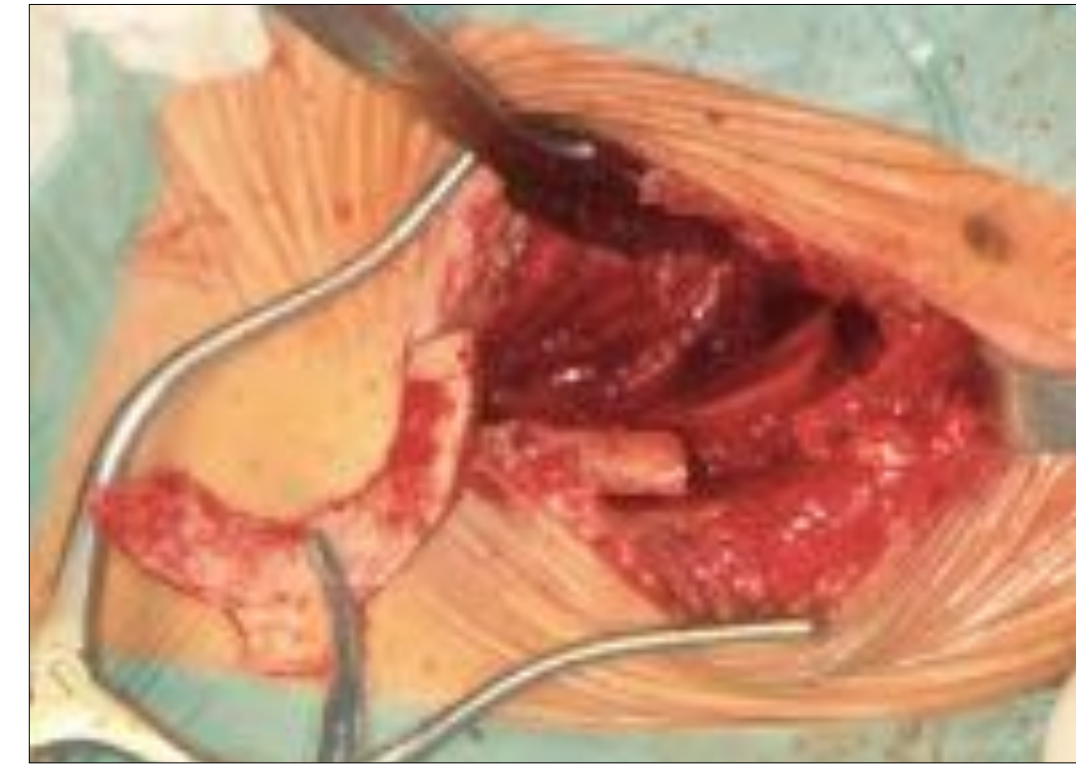
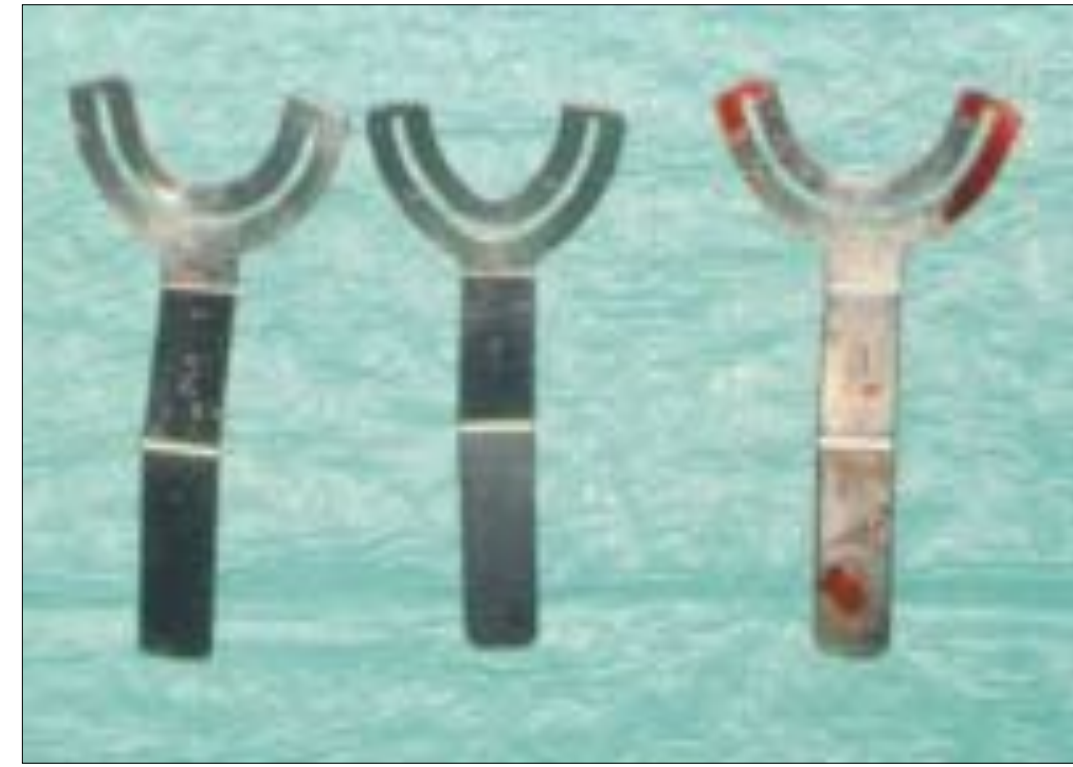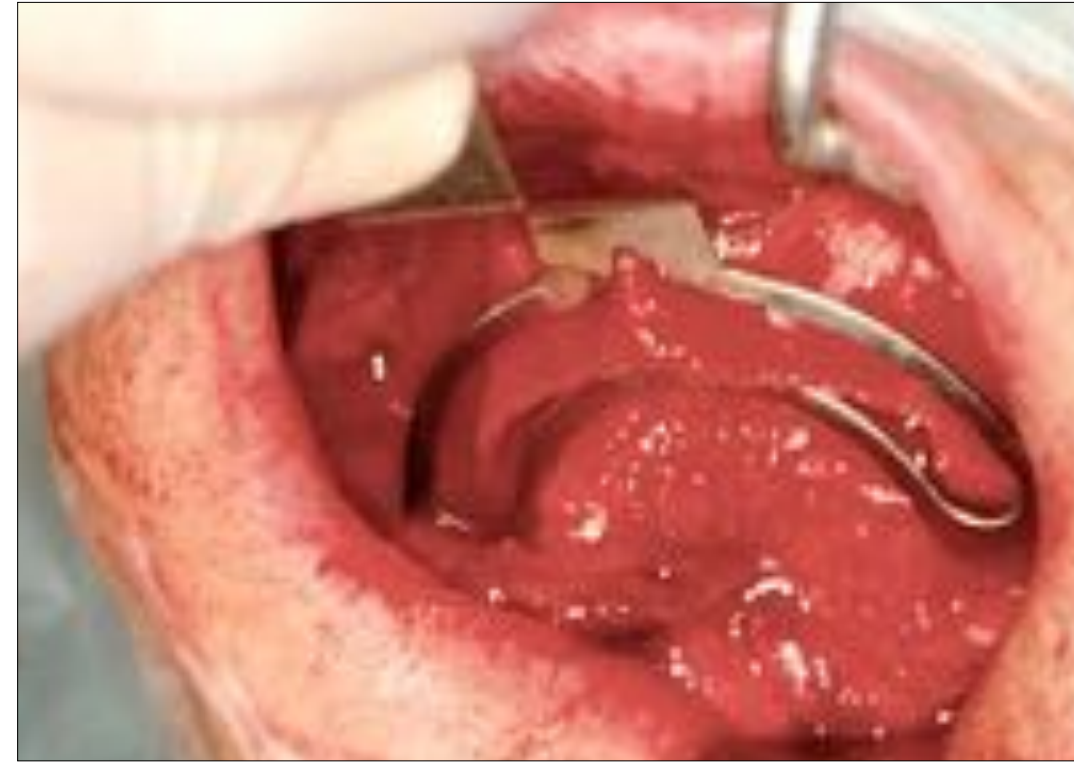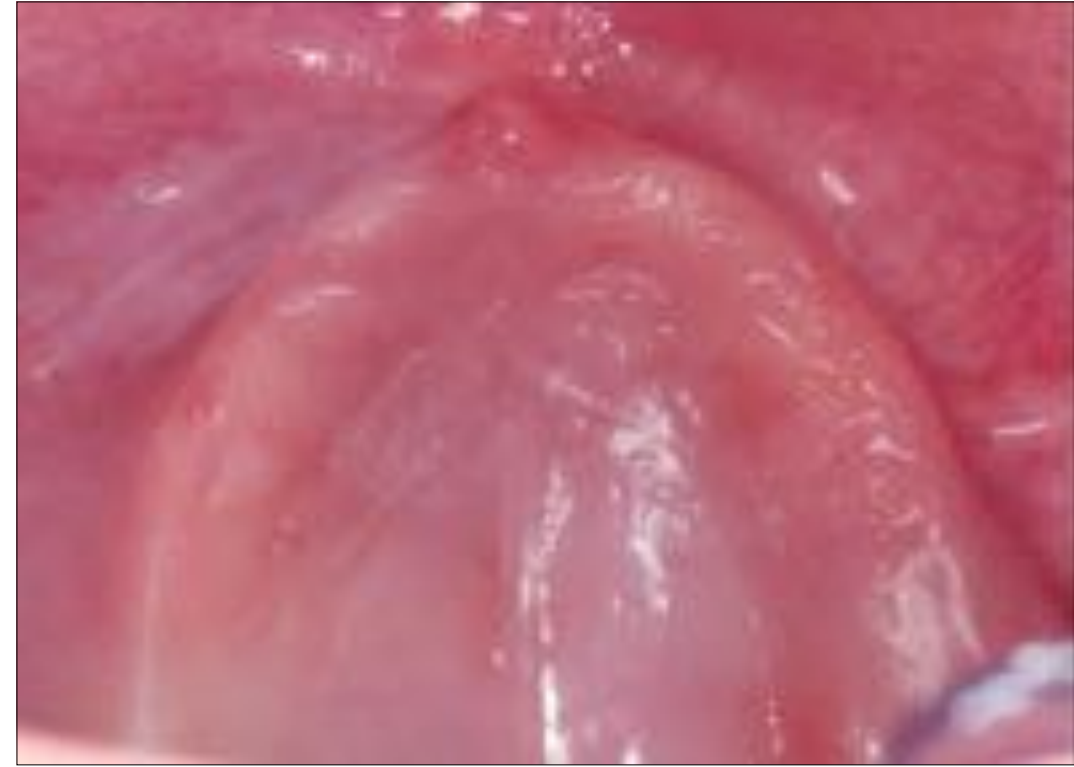#revolution

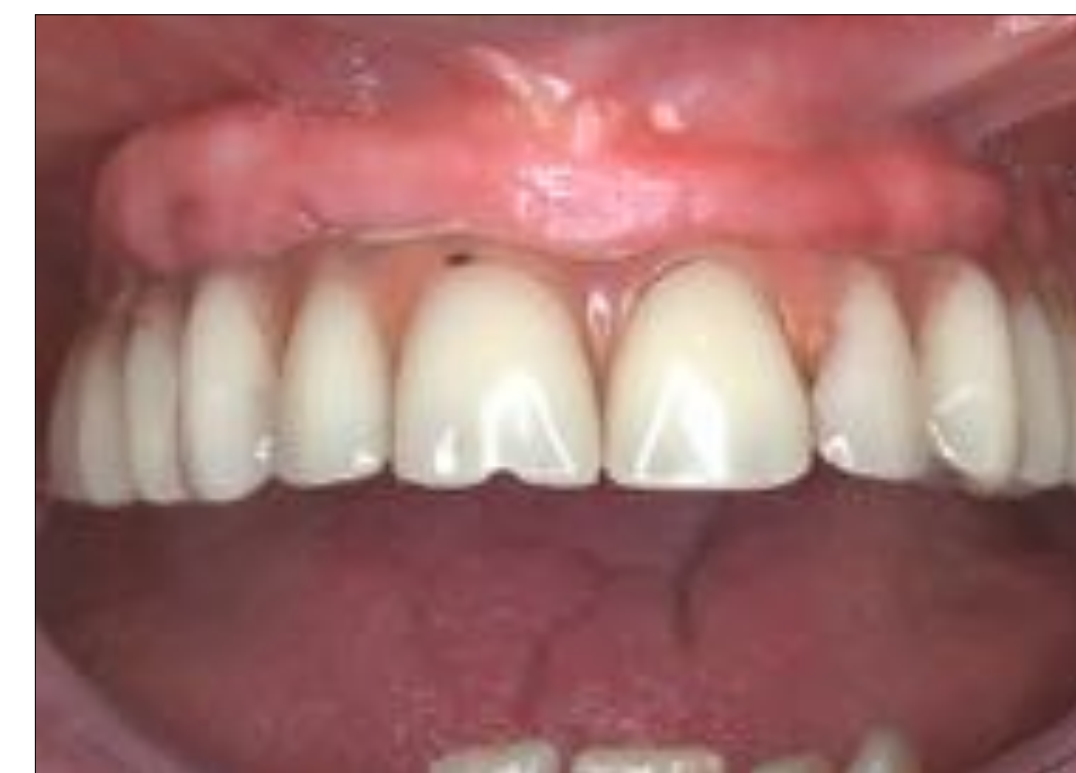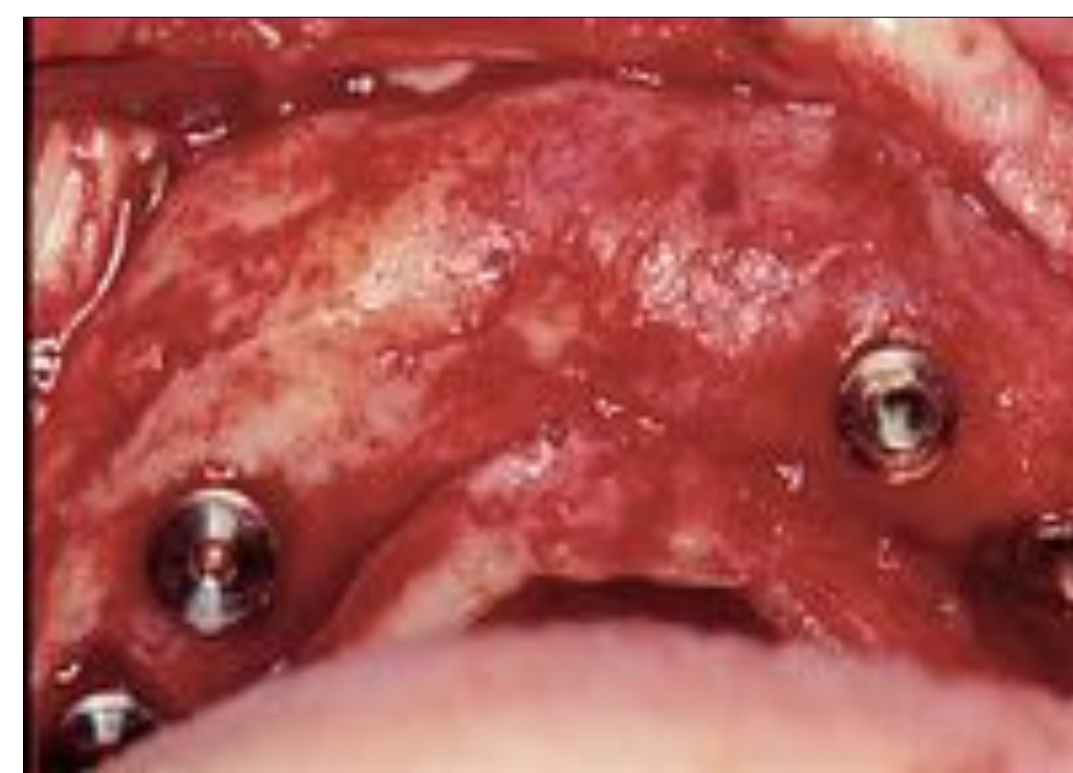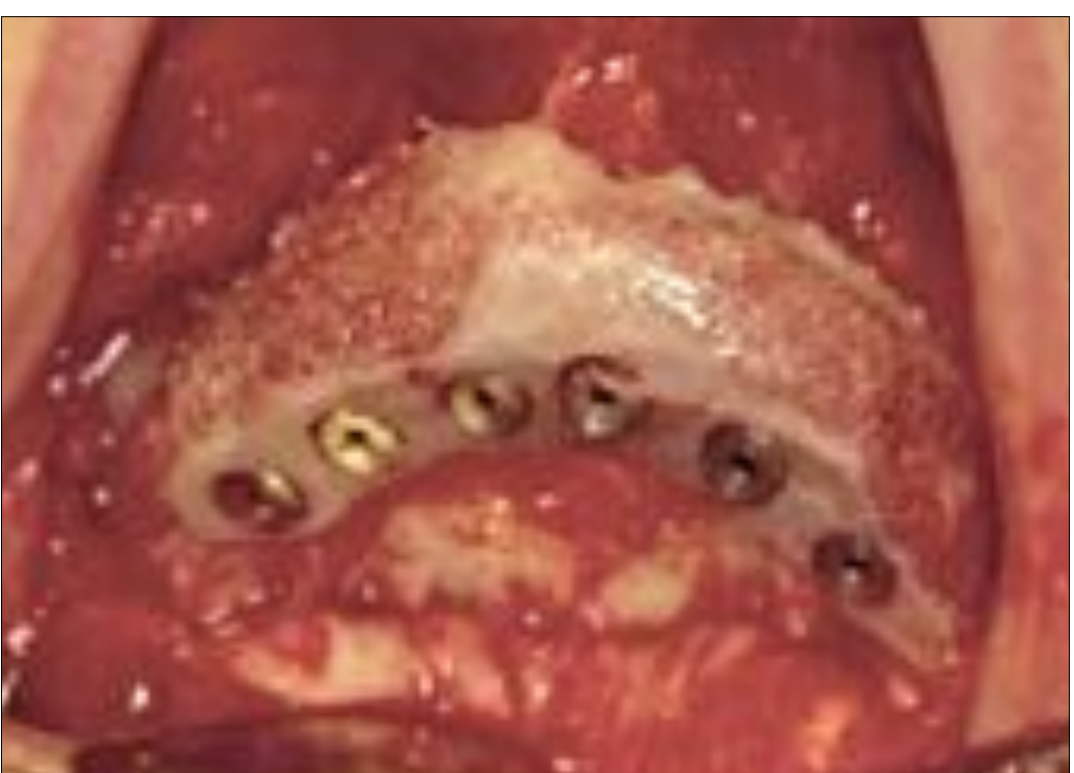
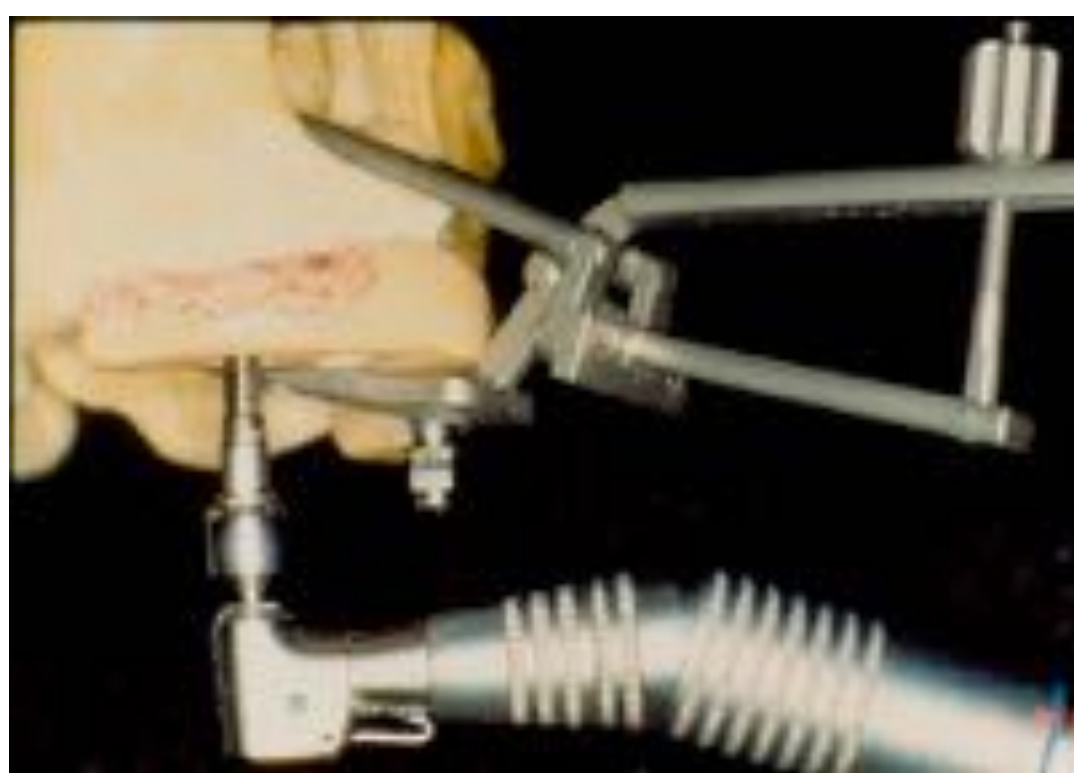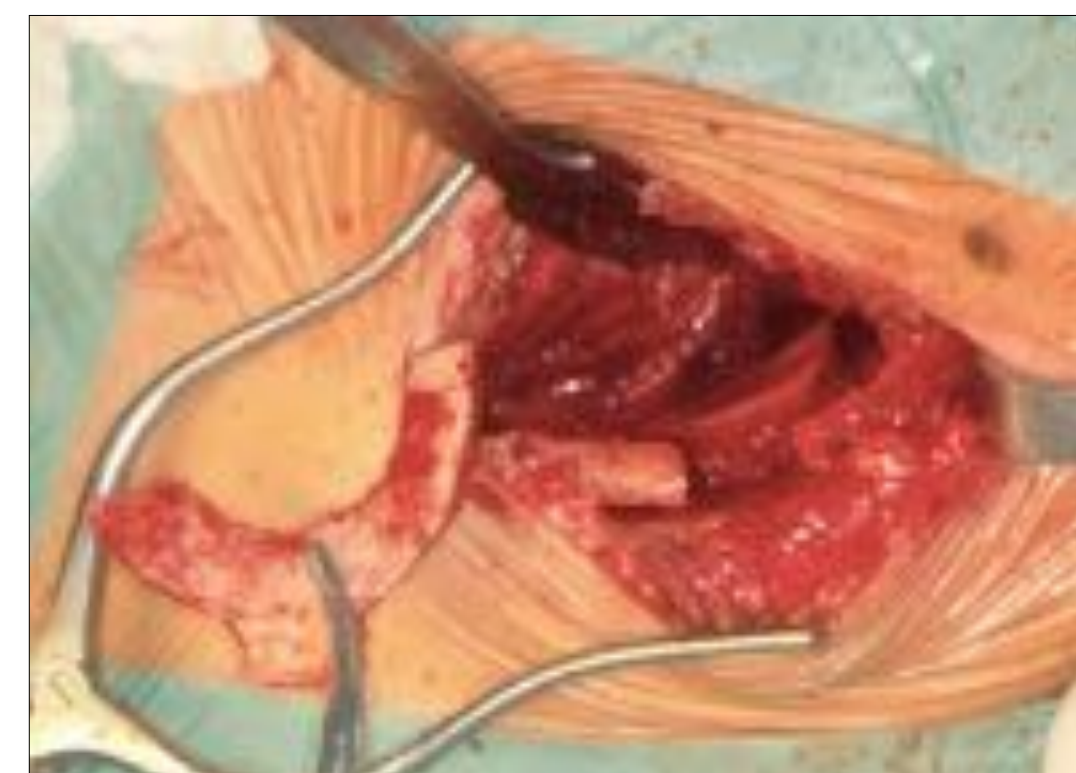
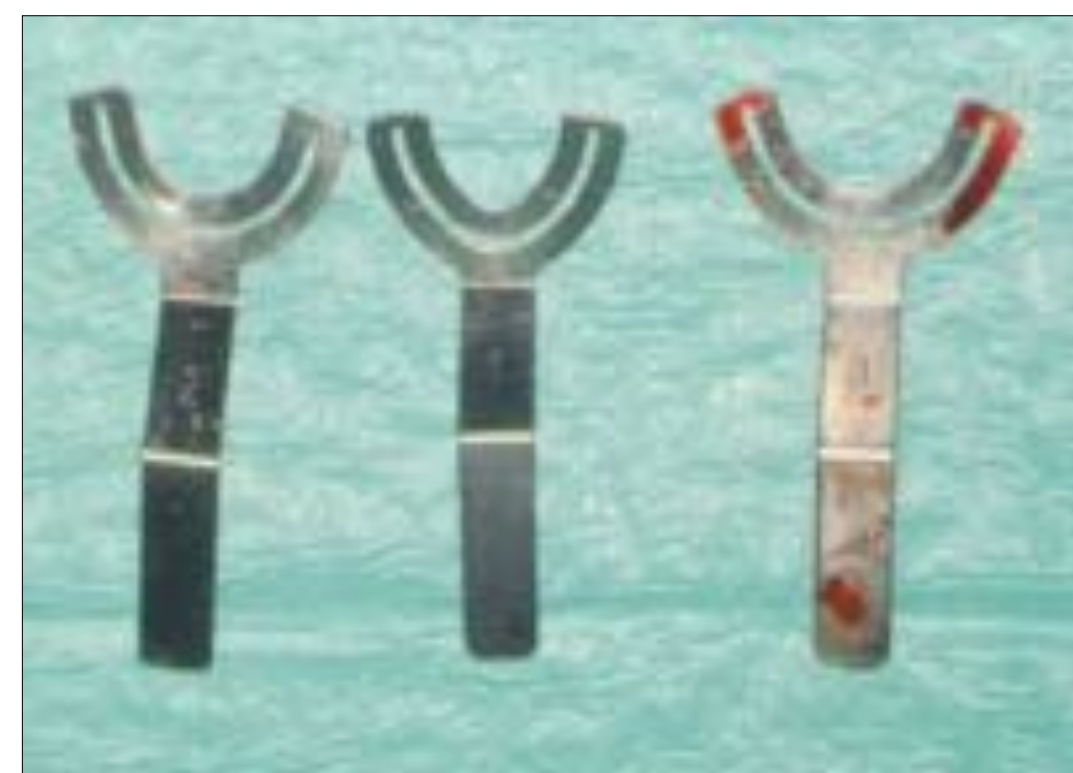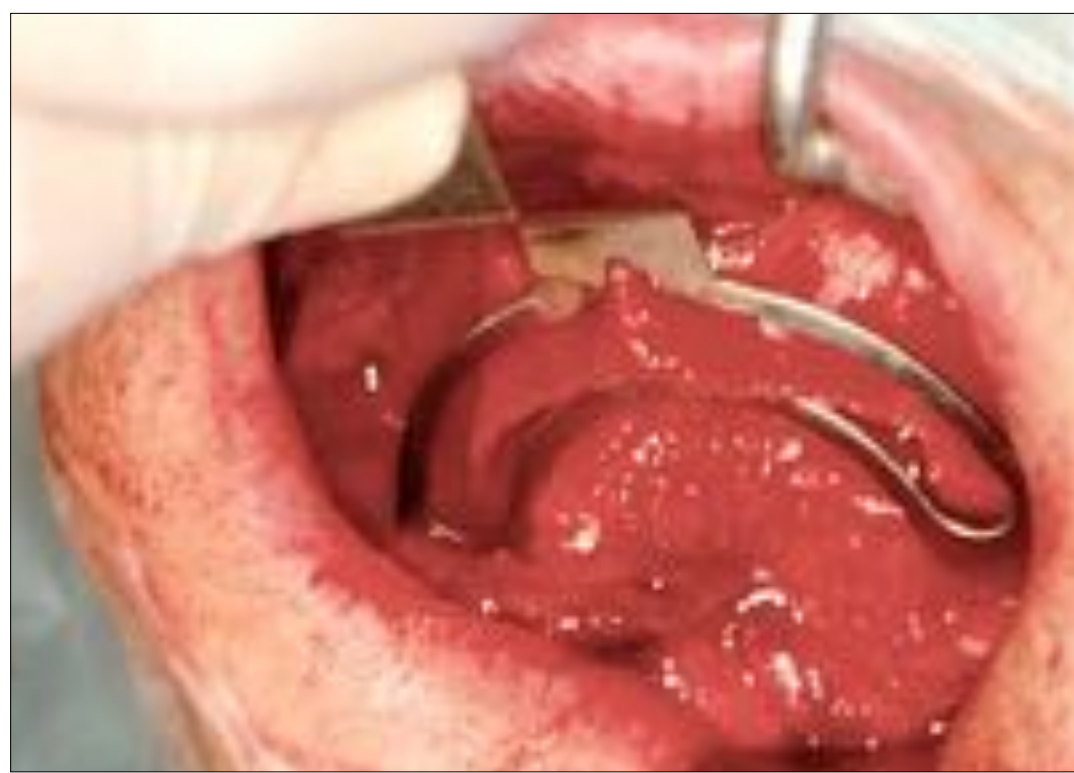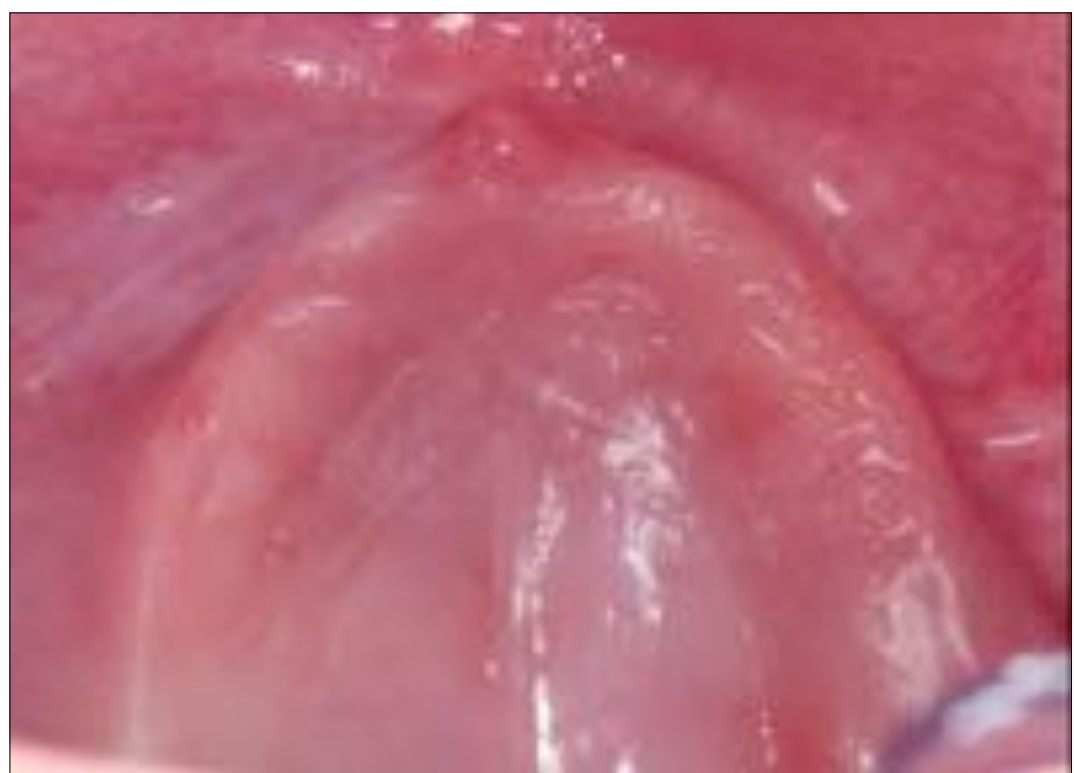
there's no revolution without evolution

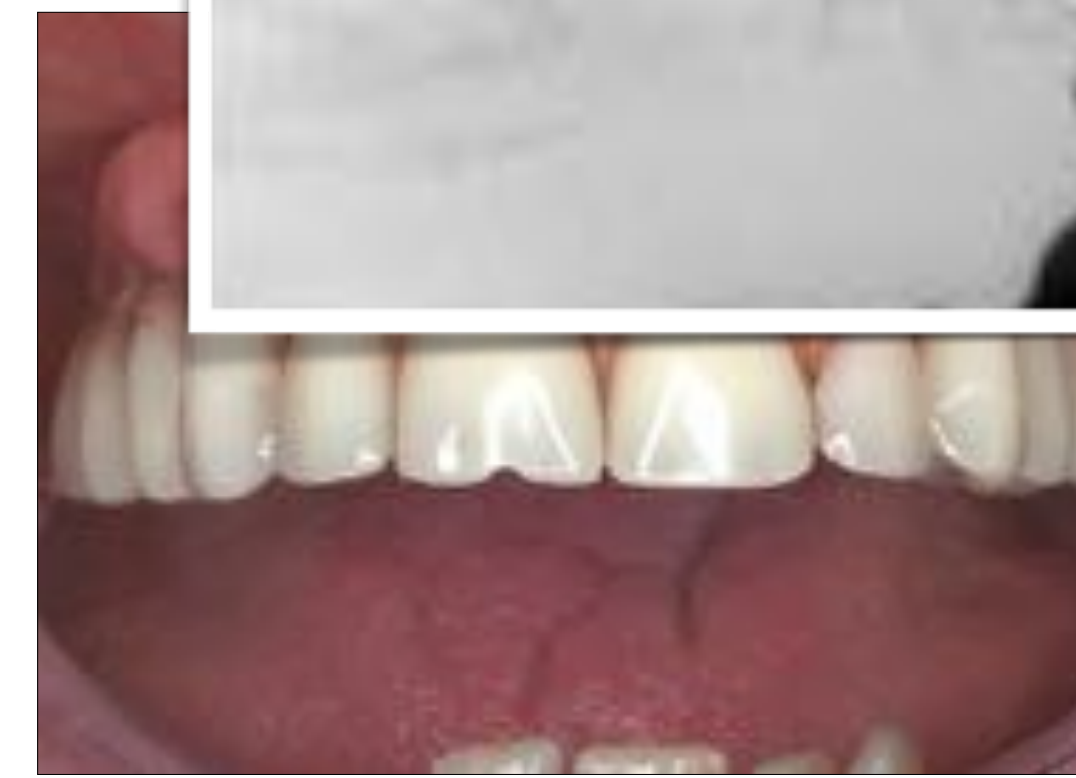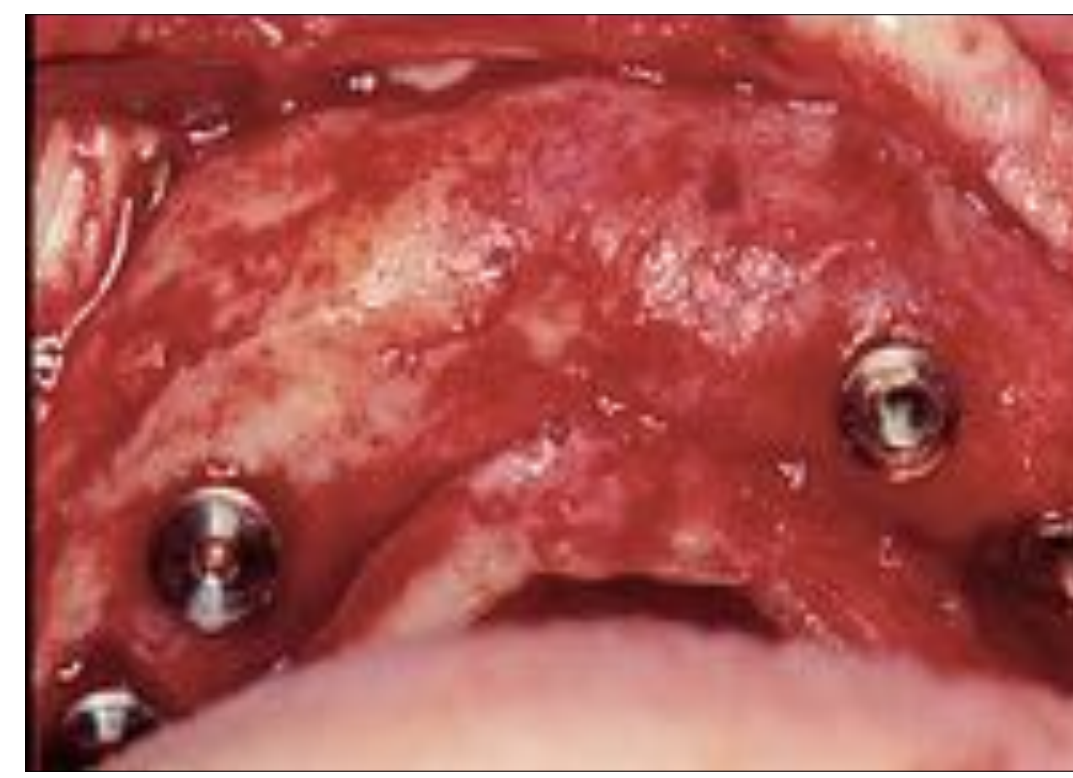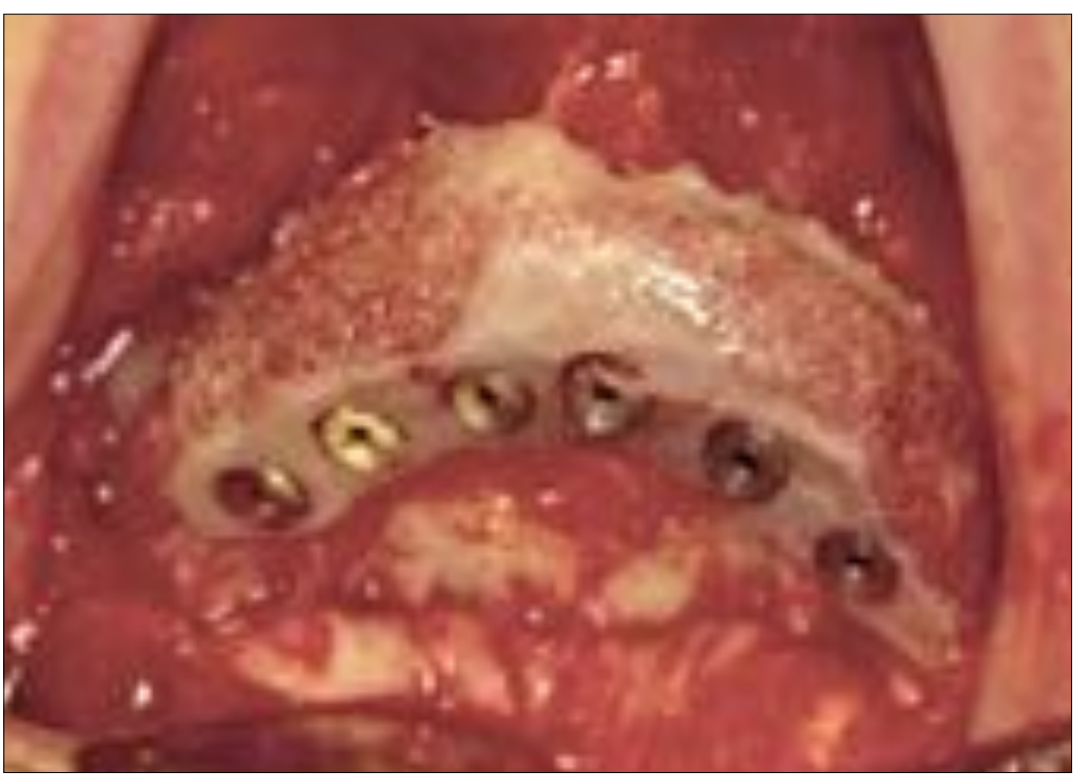

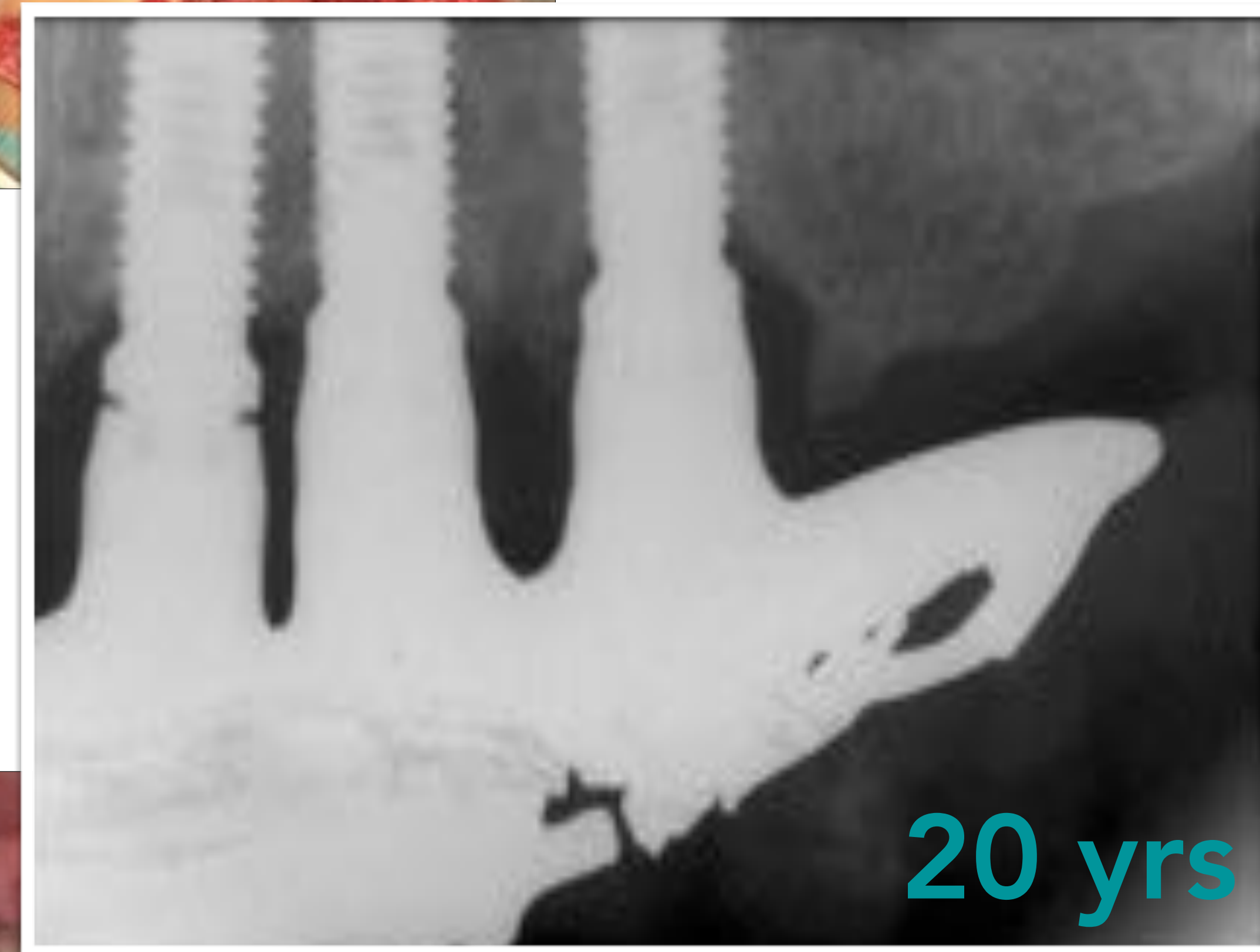
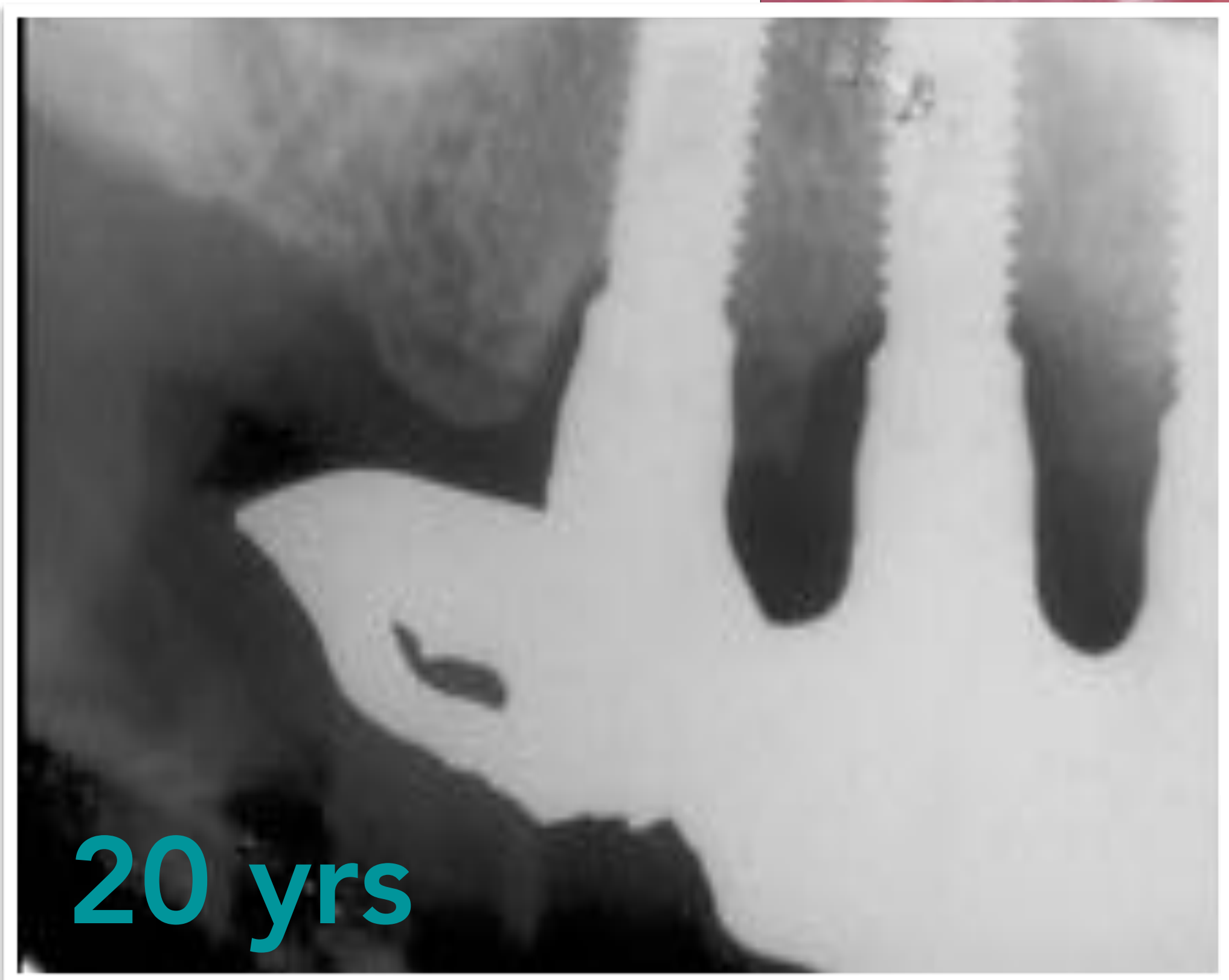
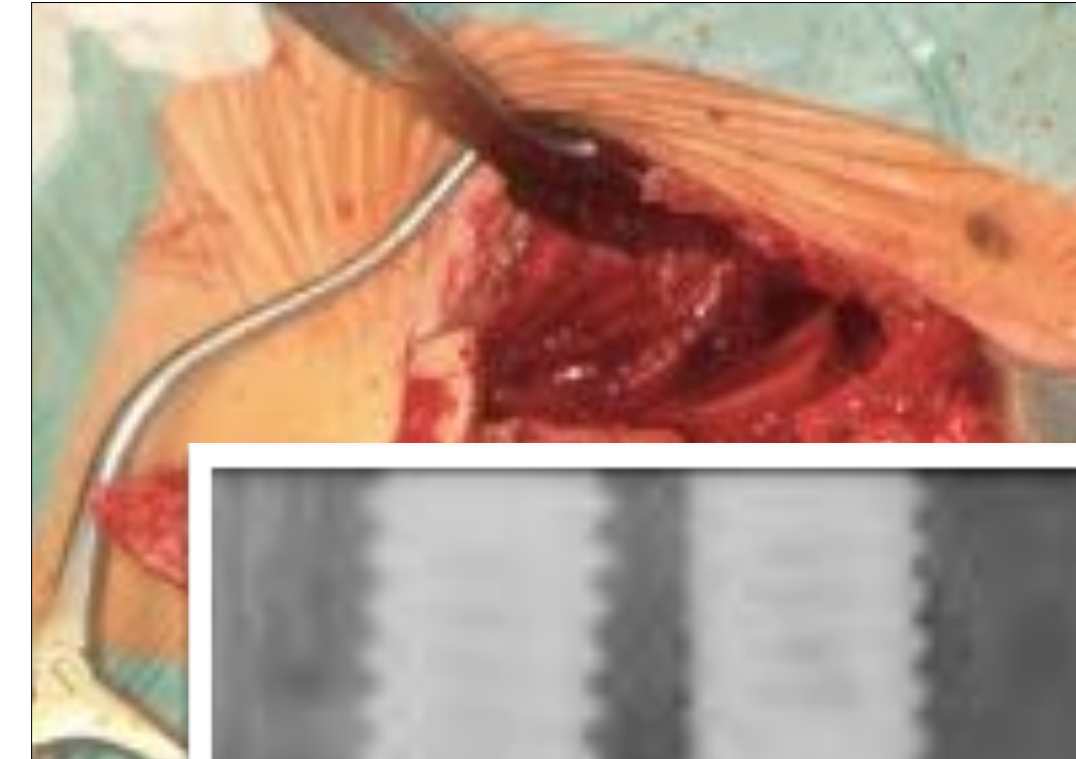

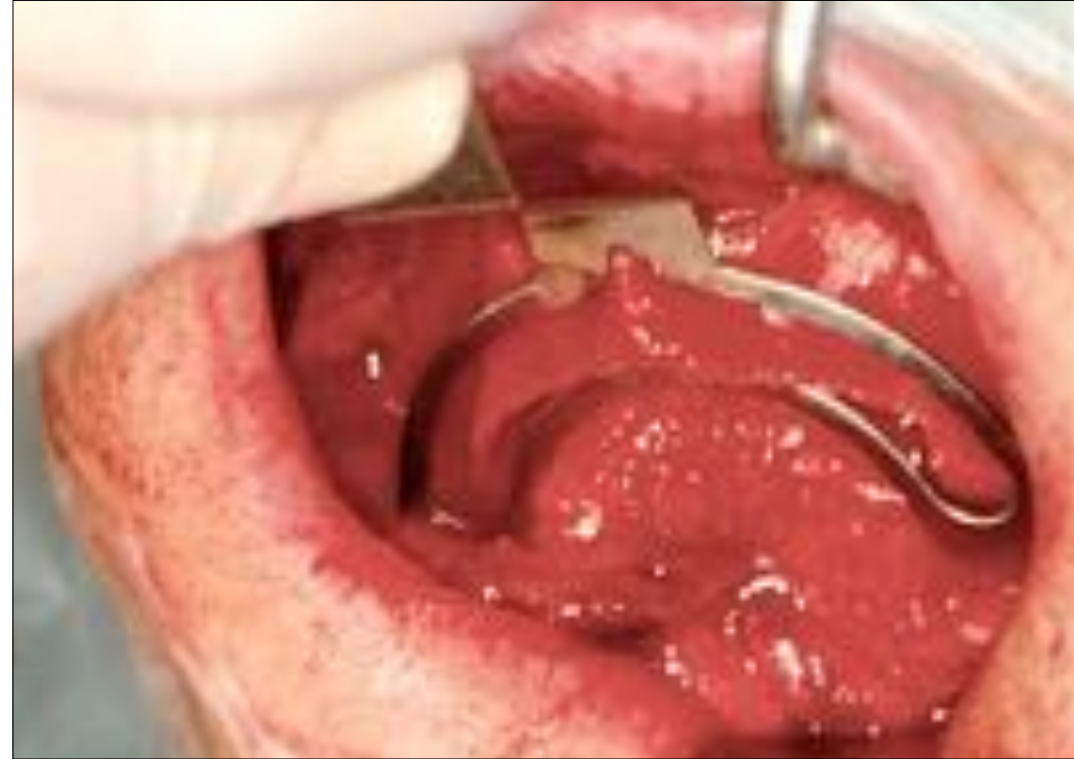
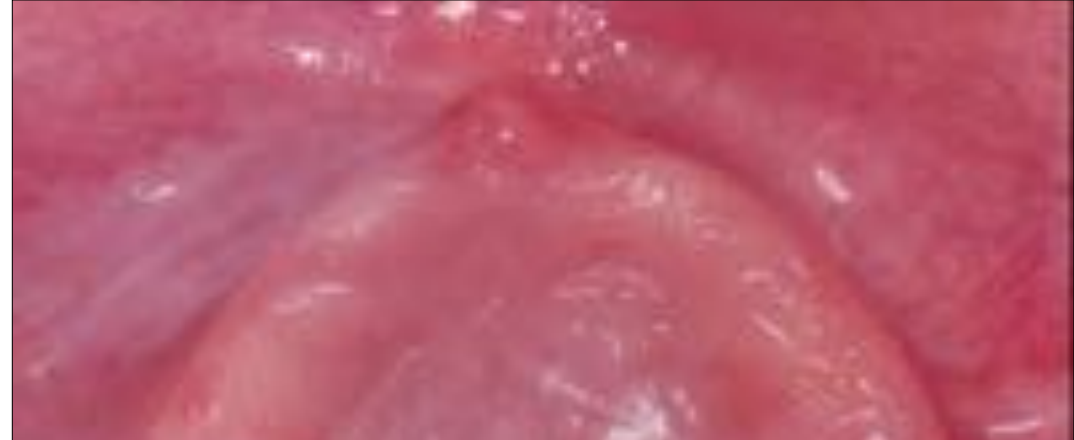









20 yrs



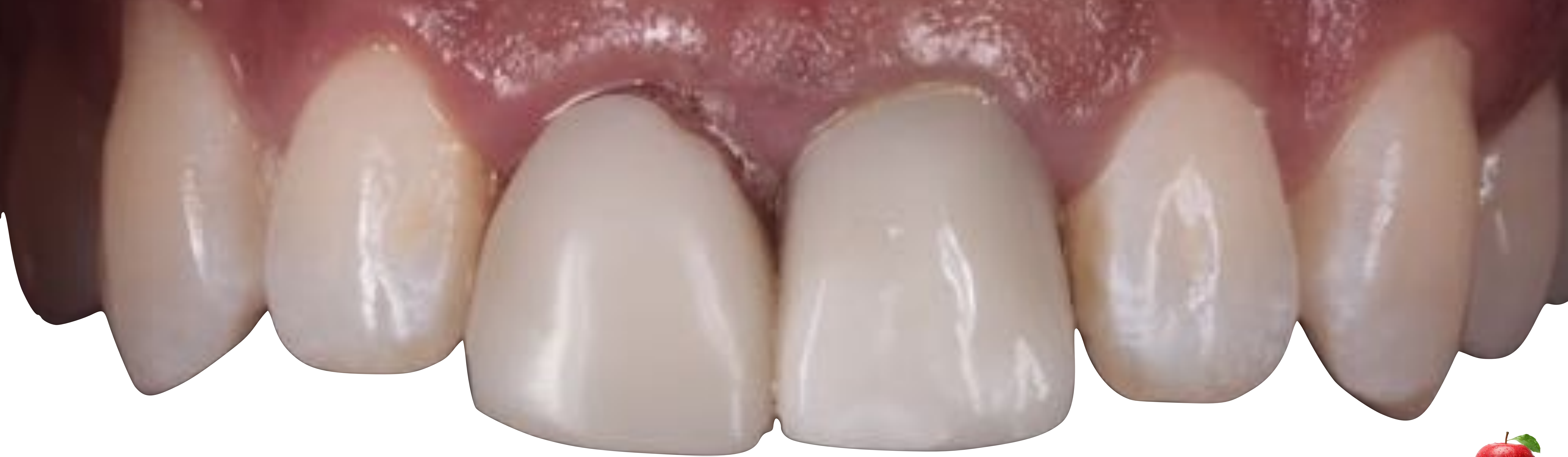


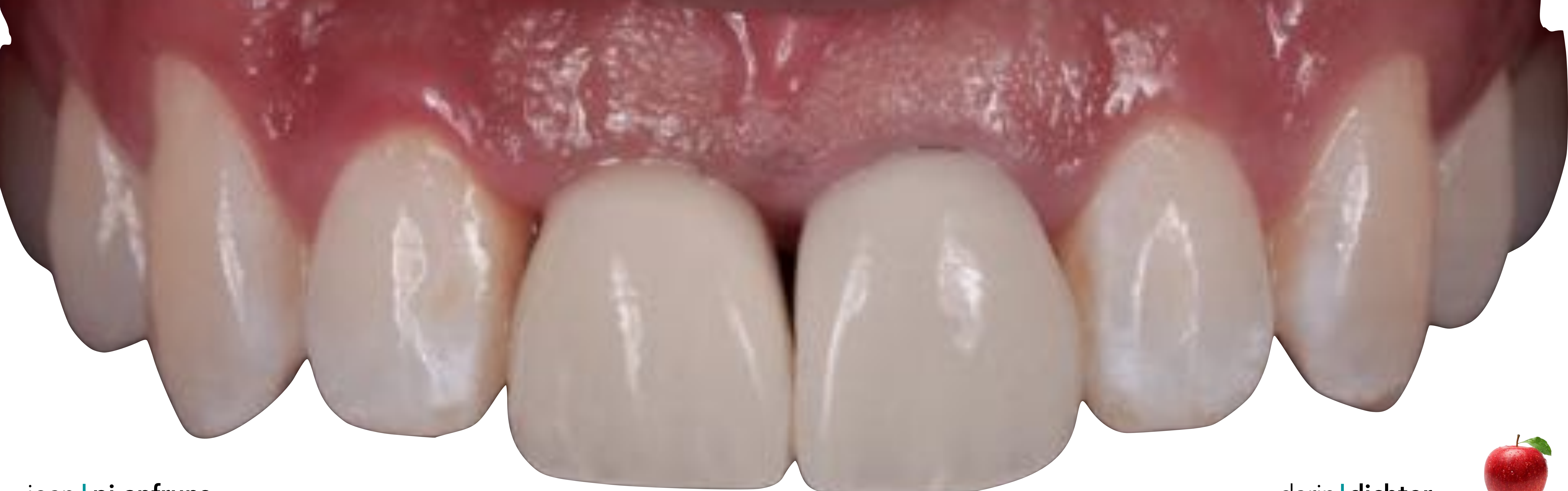
eve





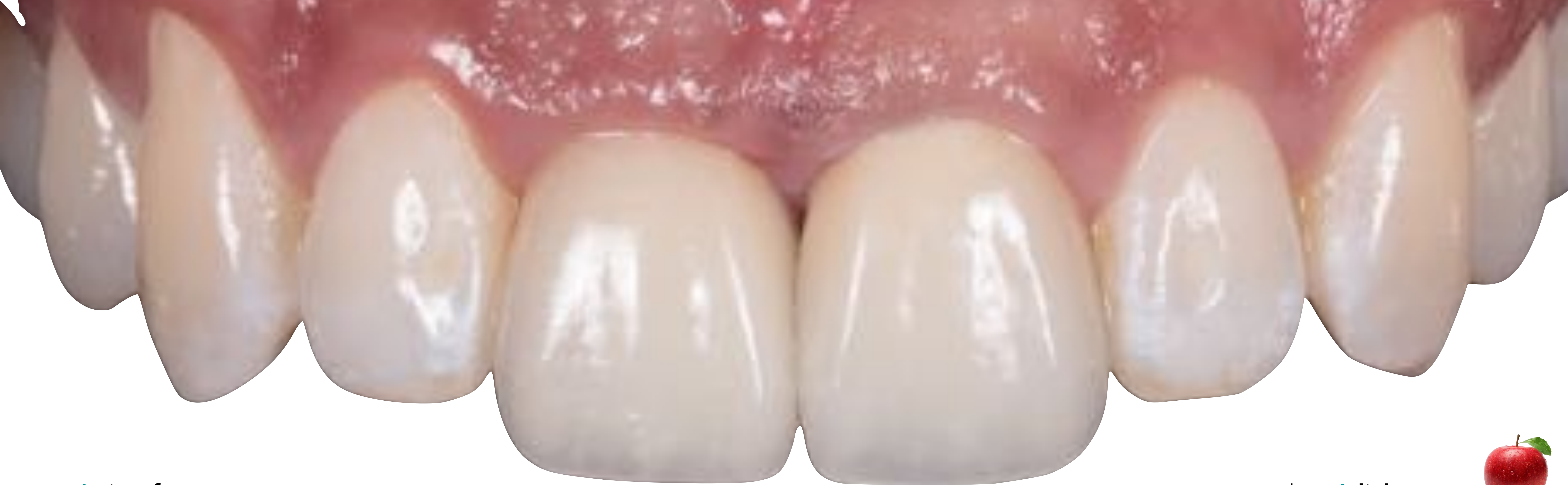



joan | pi-anfruns

darin | dichter





joan | pi-anfruns

darin | dichter



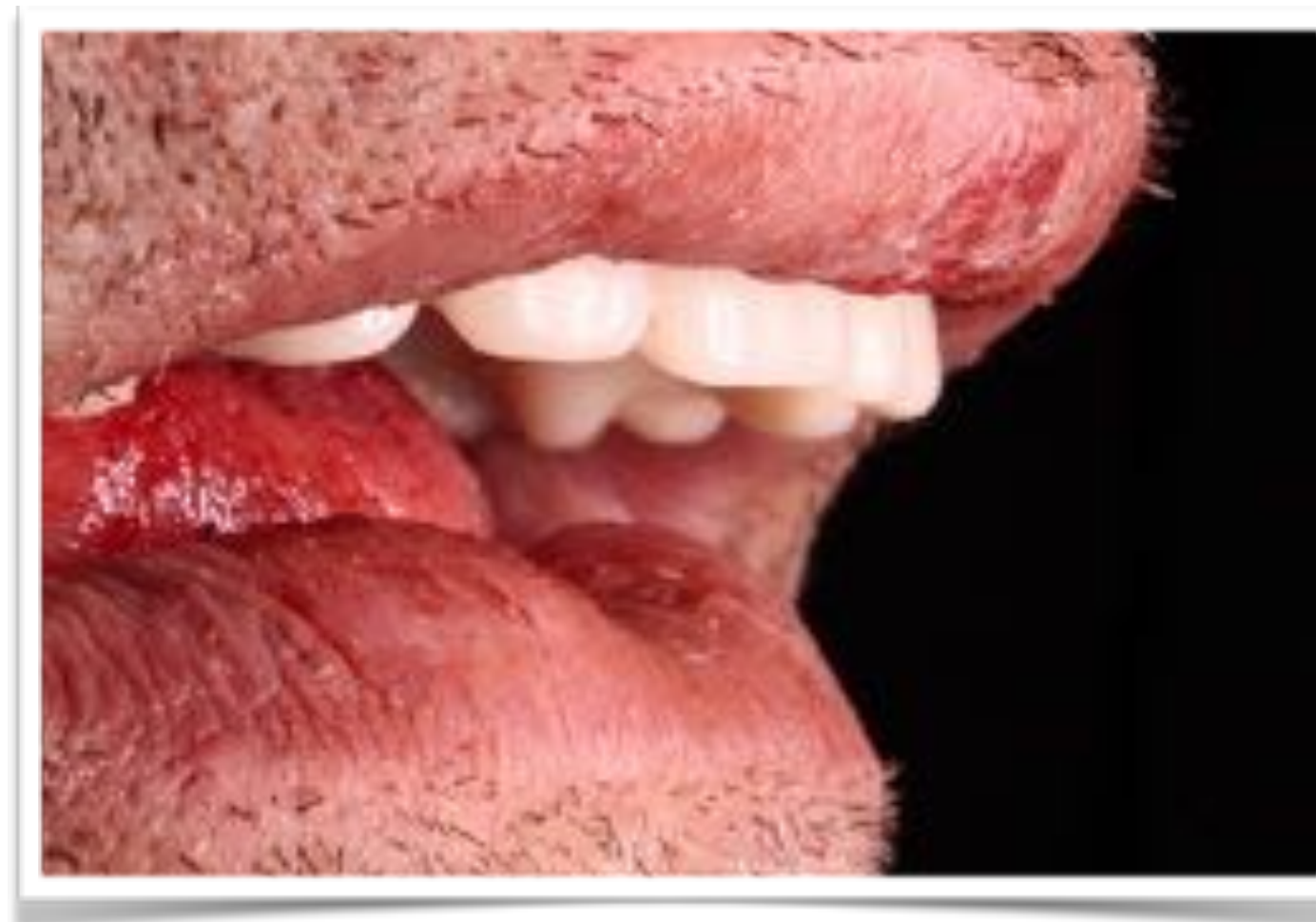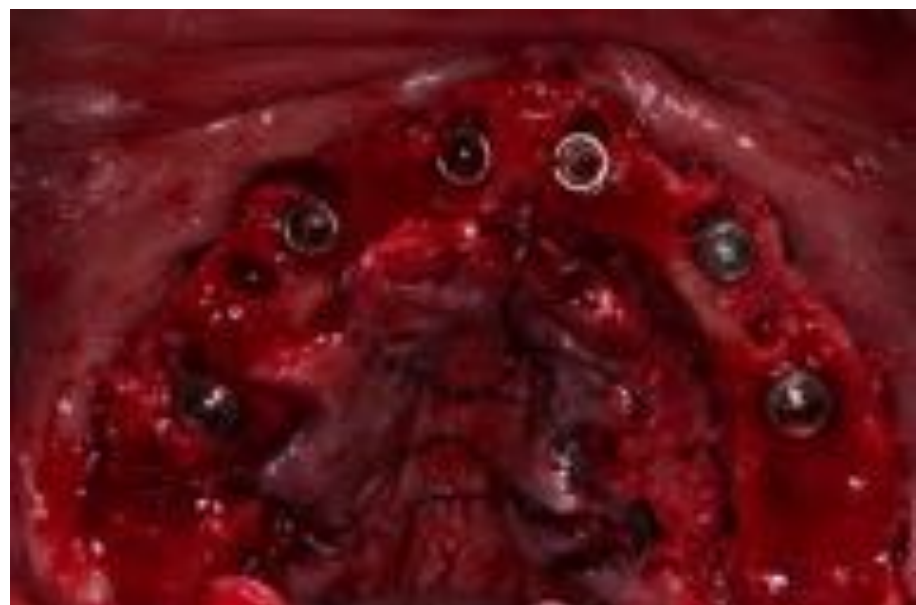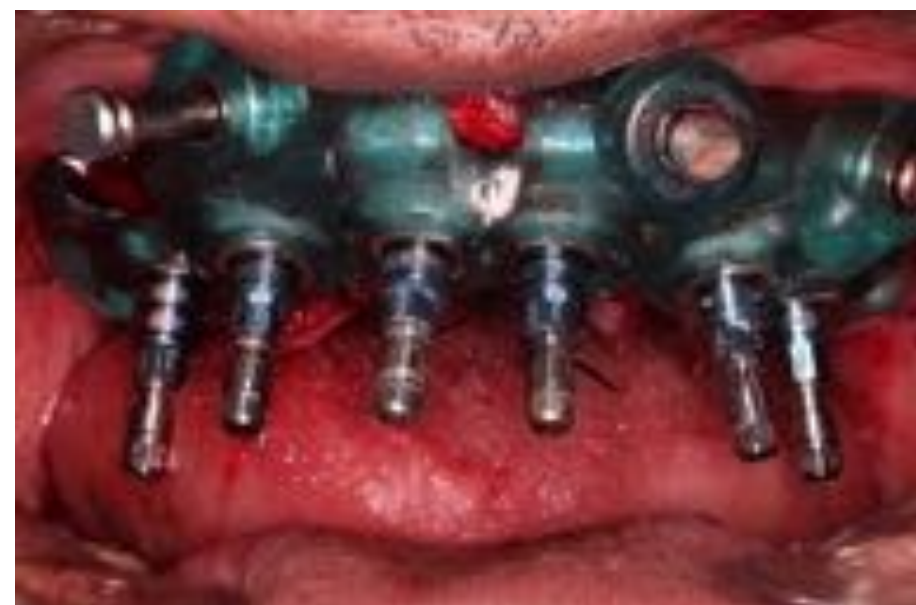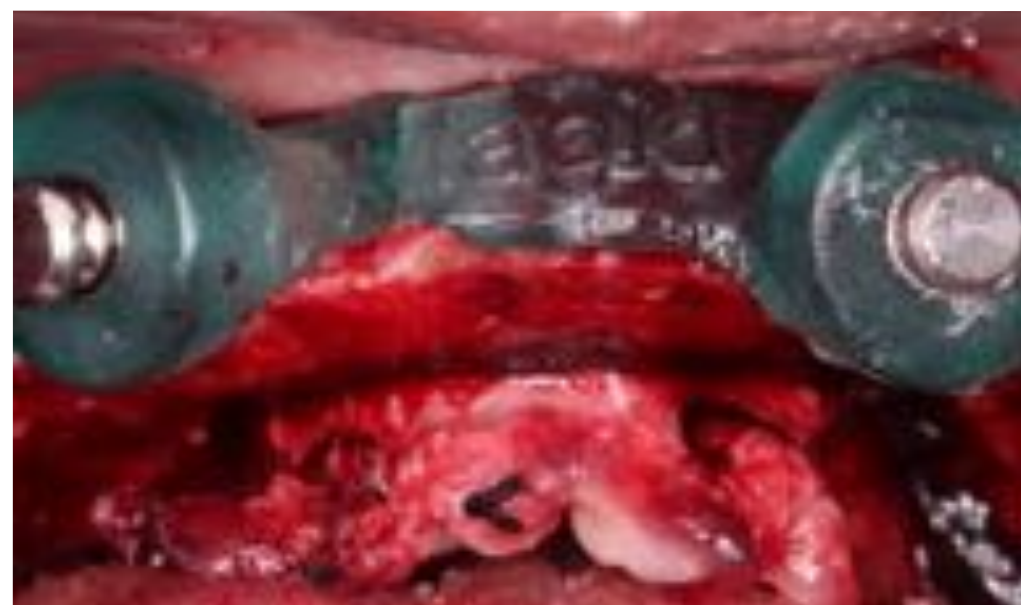



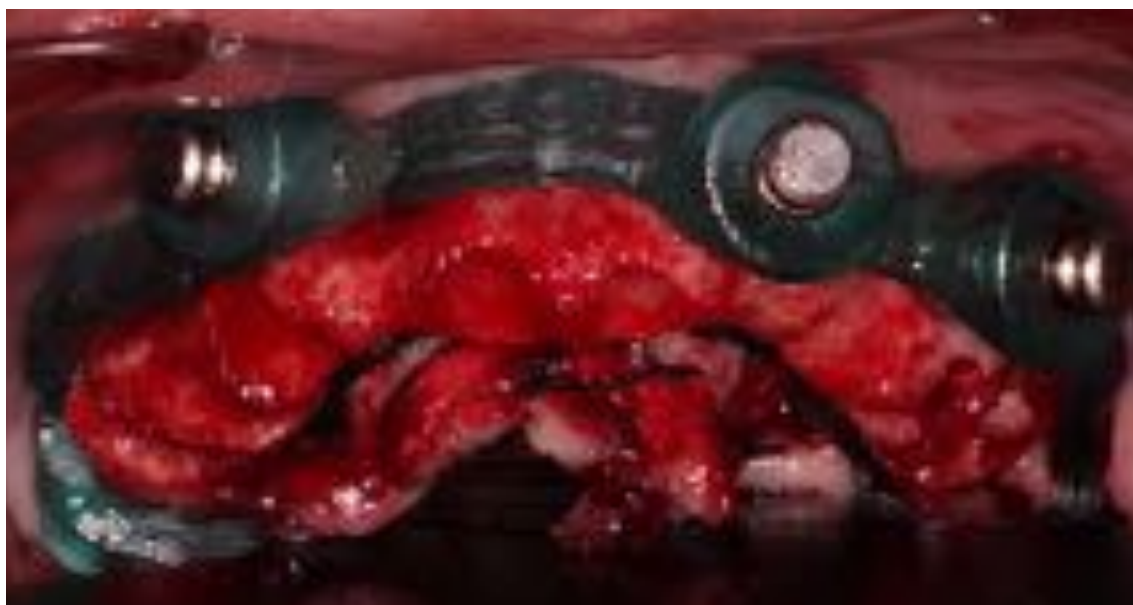
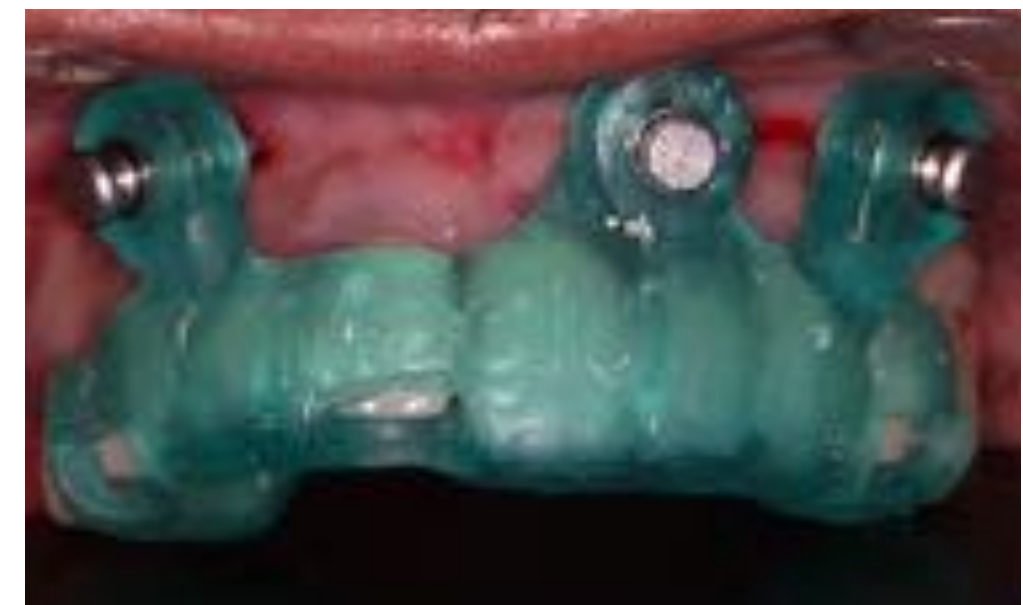newton







martin | mardirosian

russell | crockett



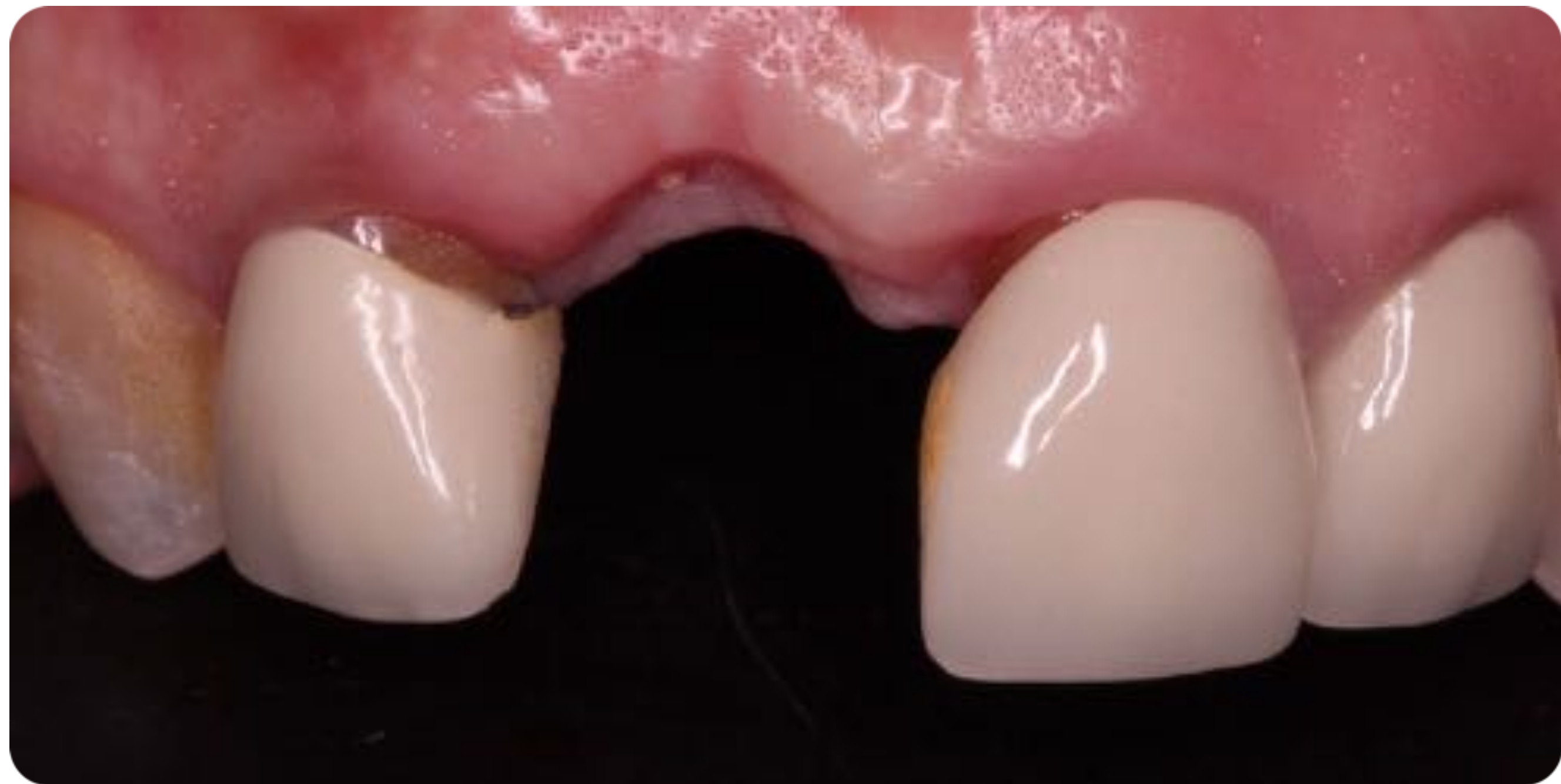


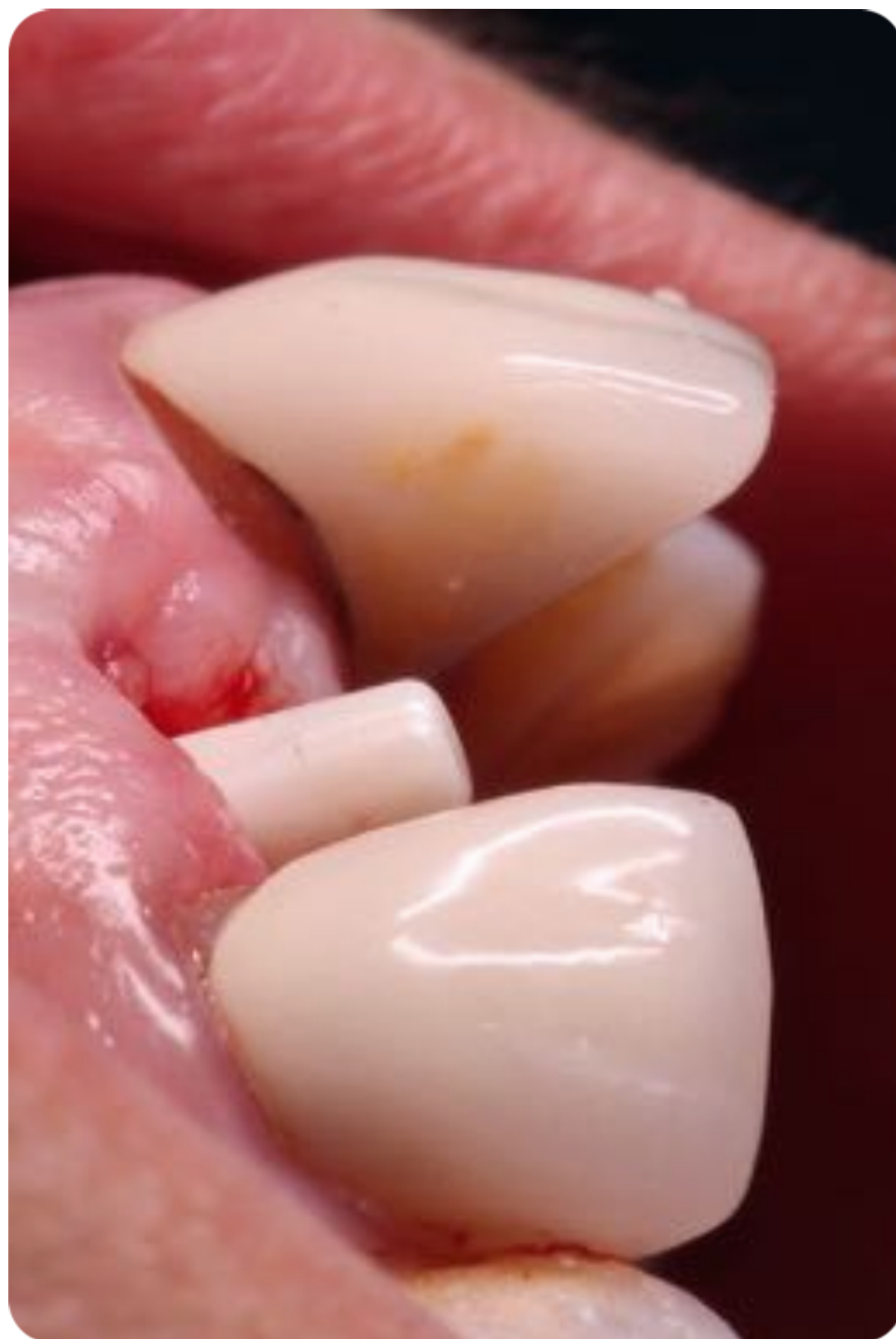
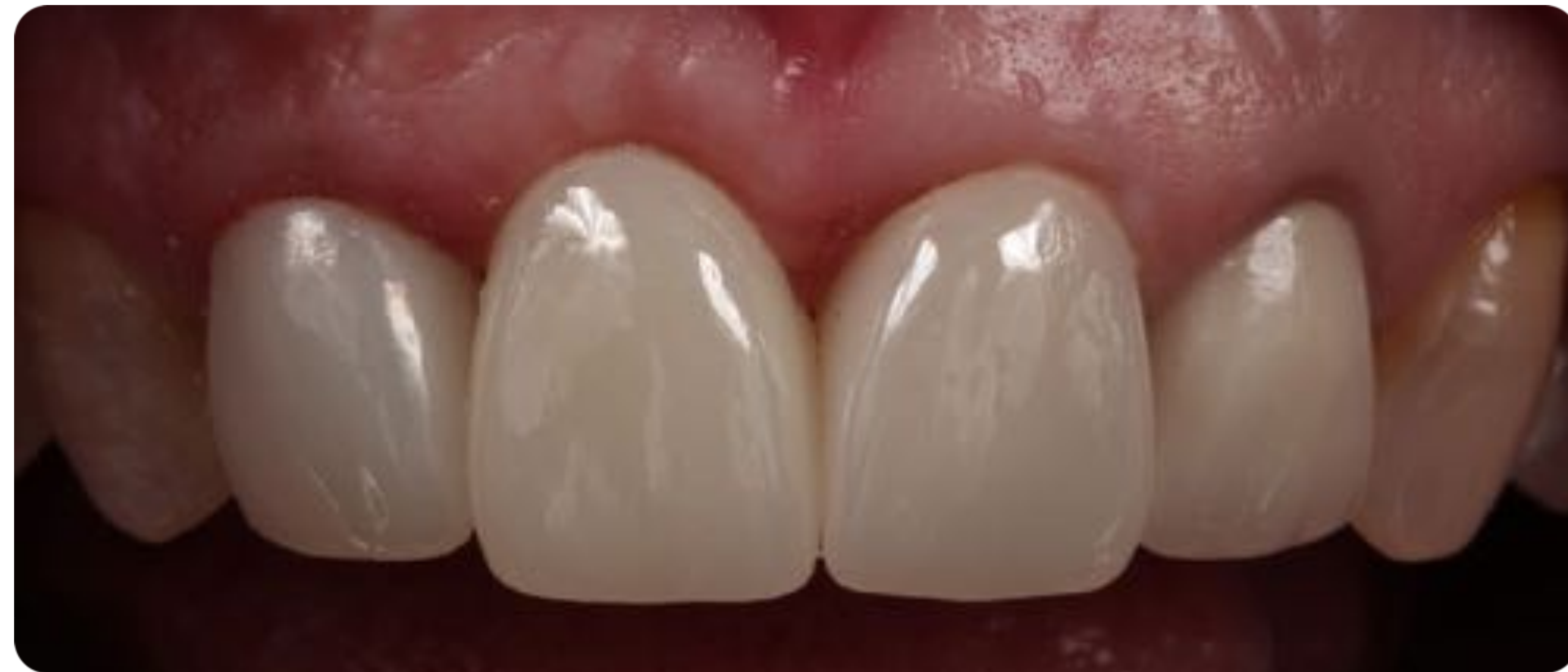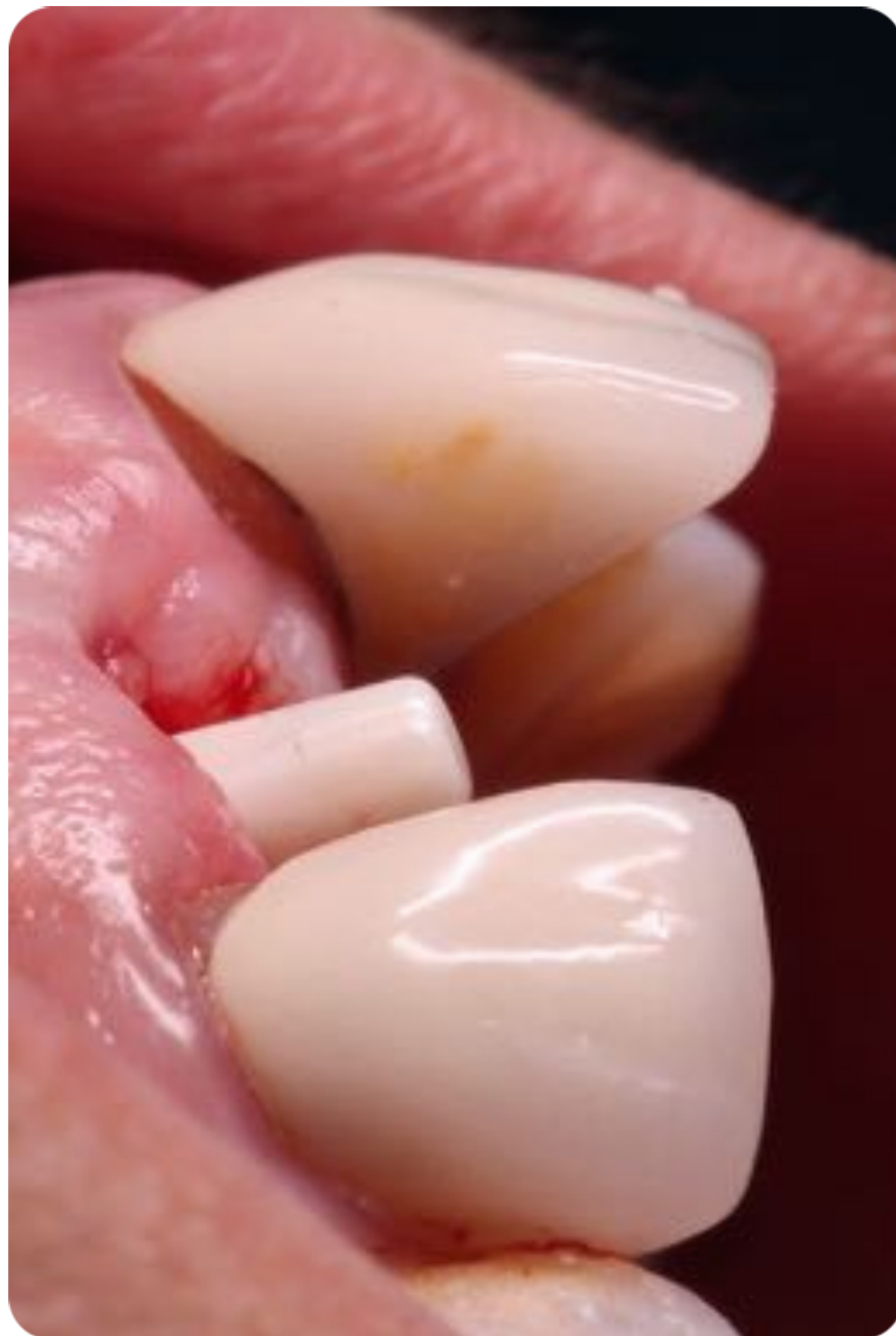the beatles















steve jobs



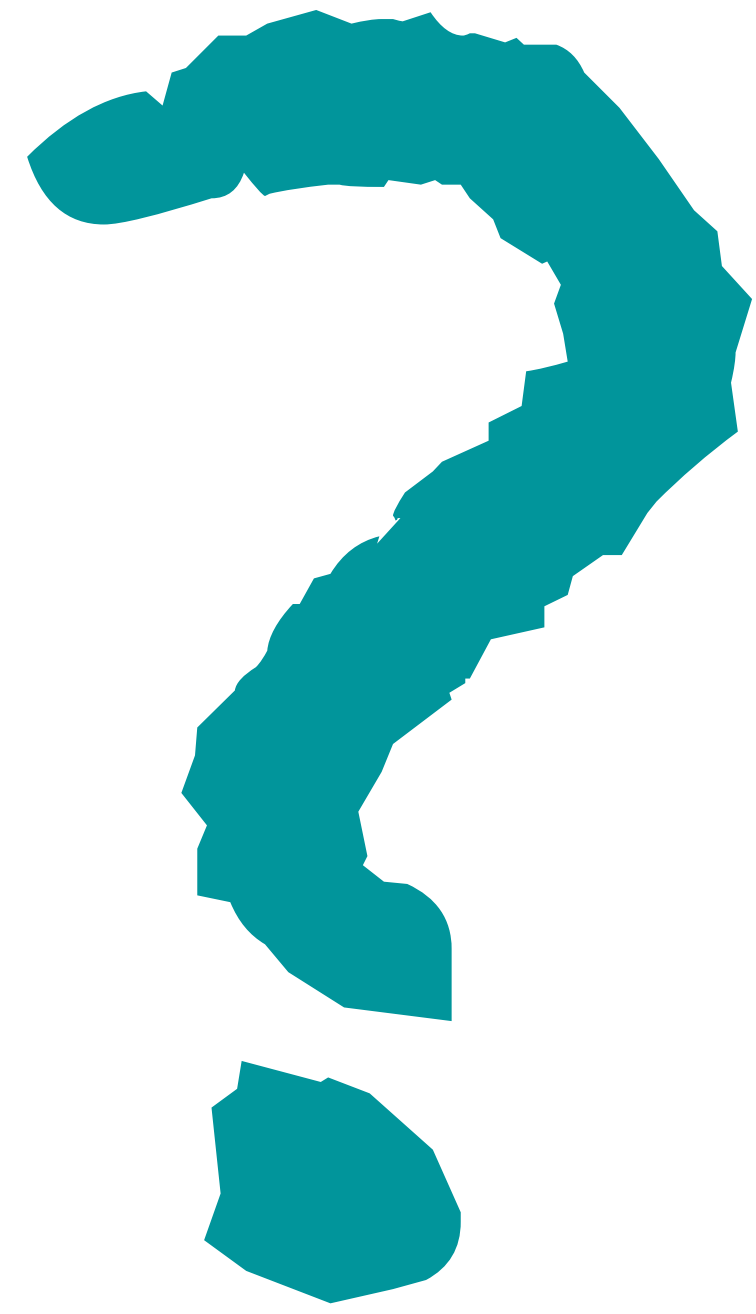


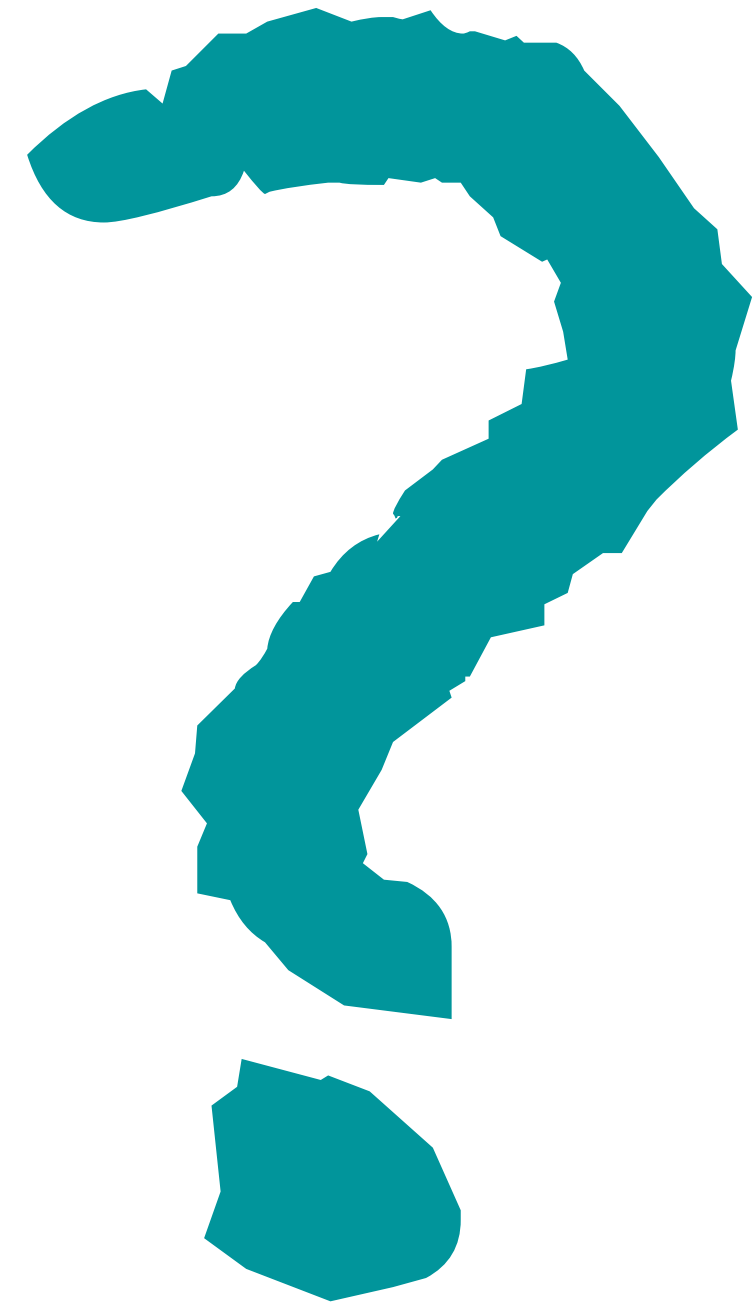
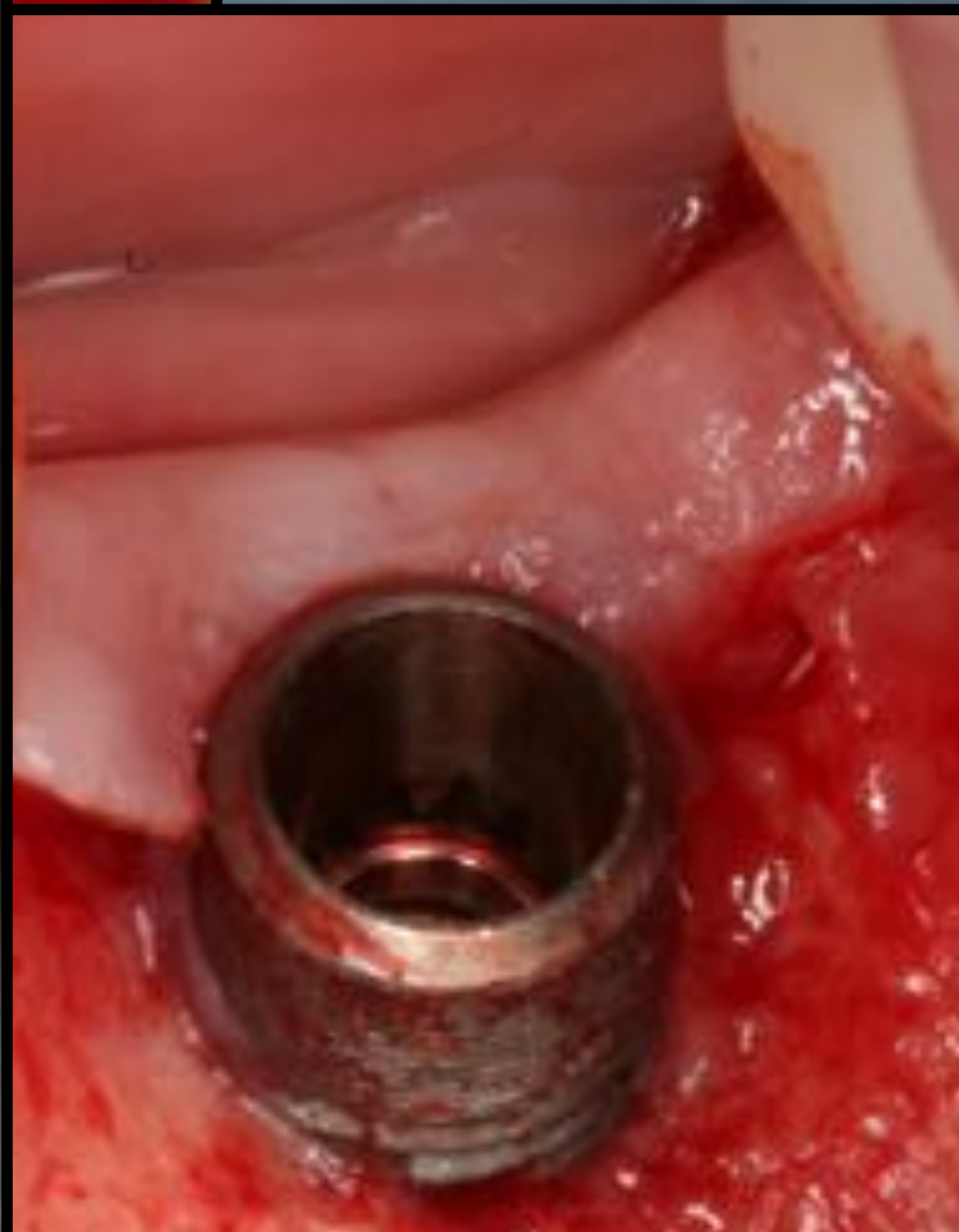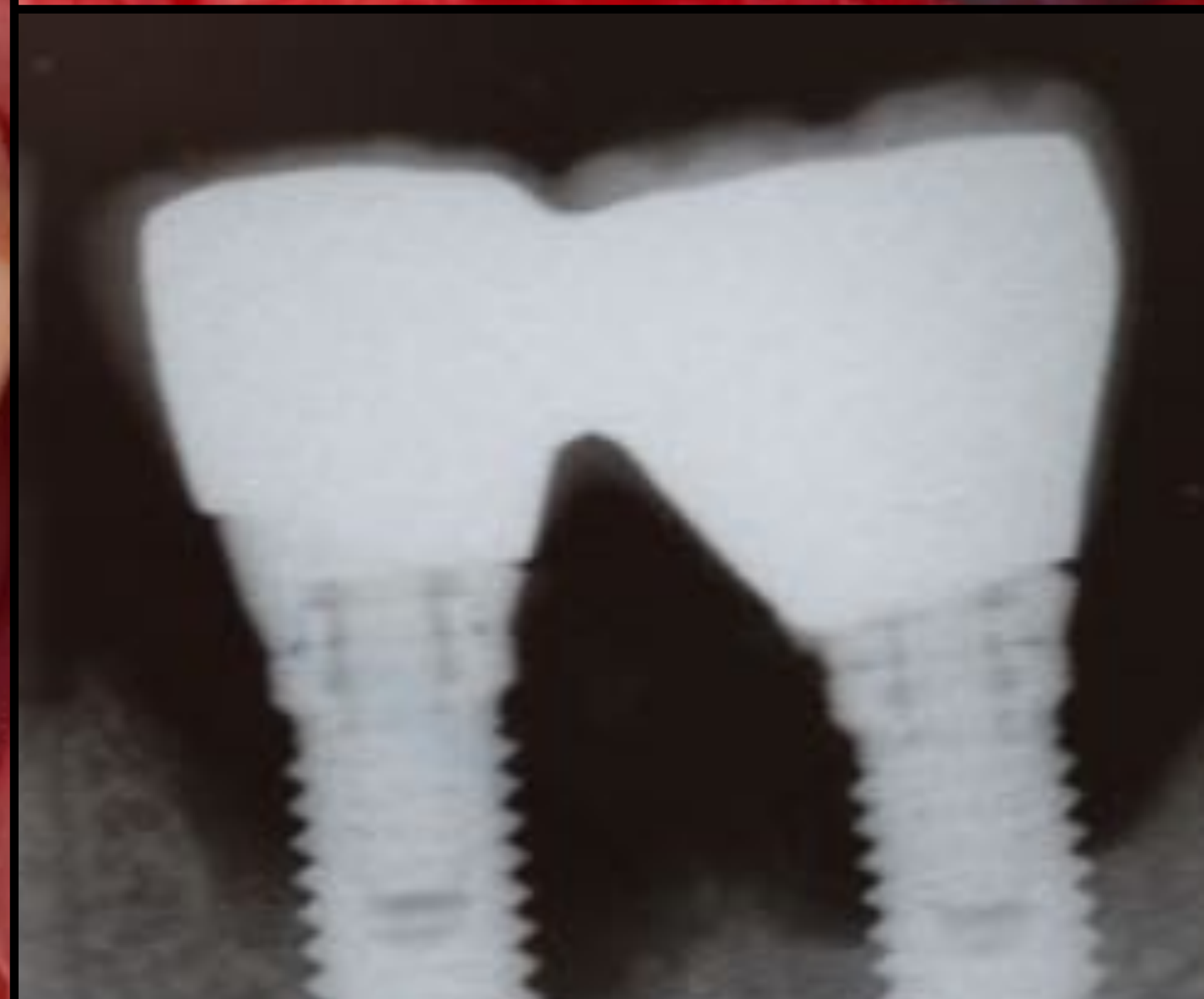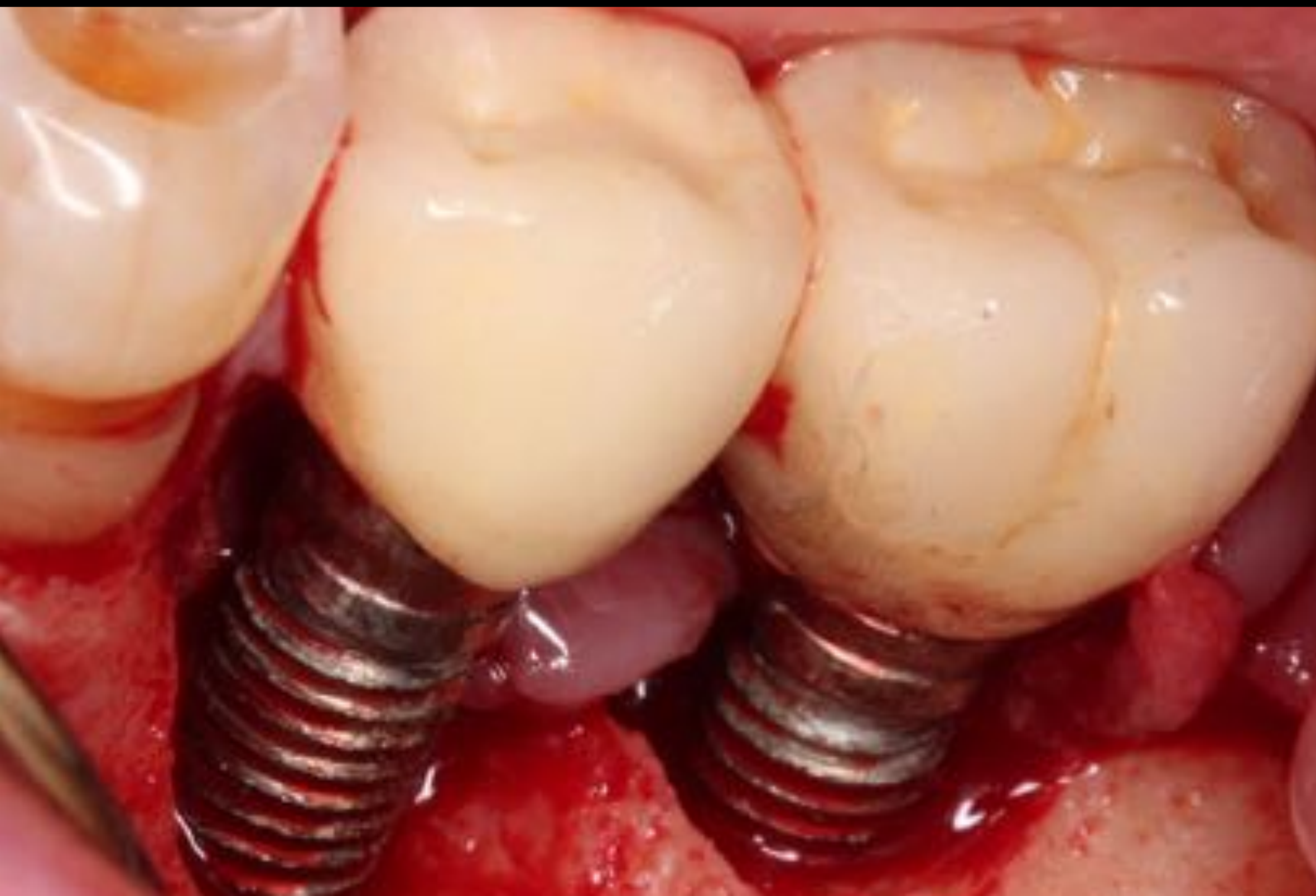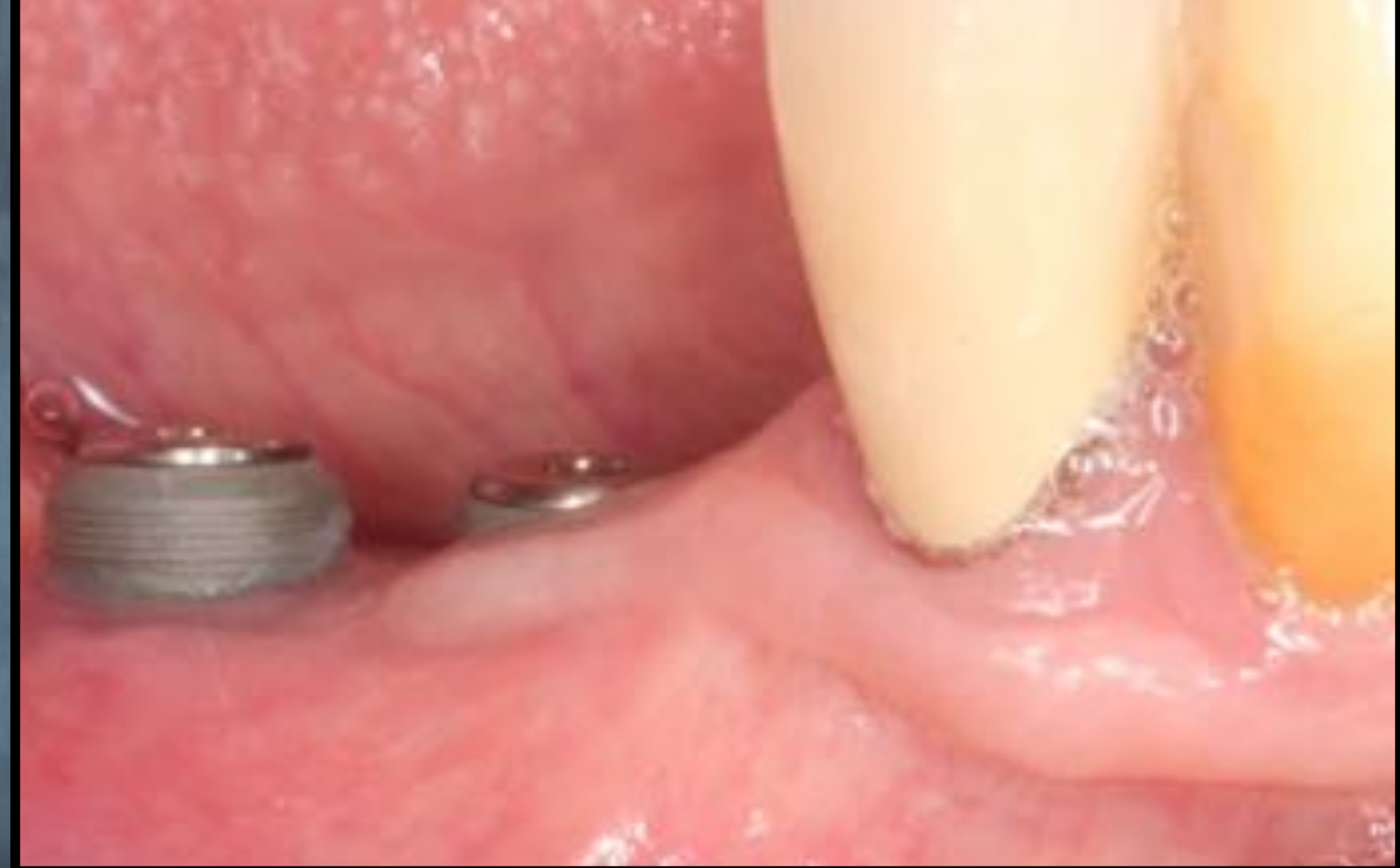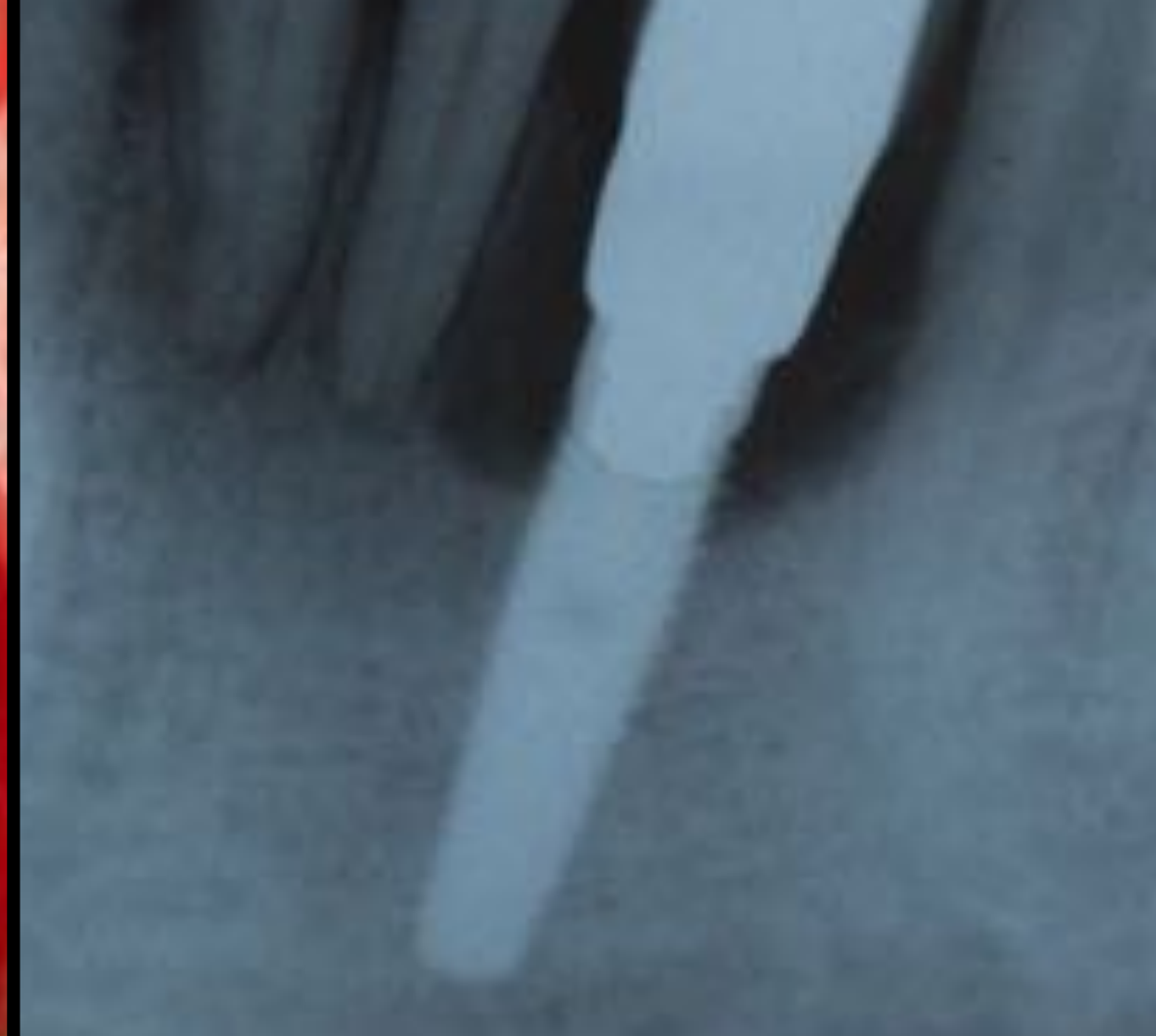
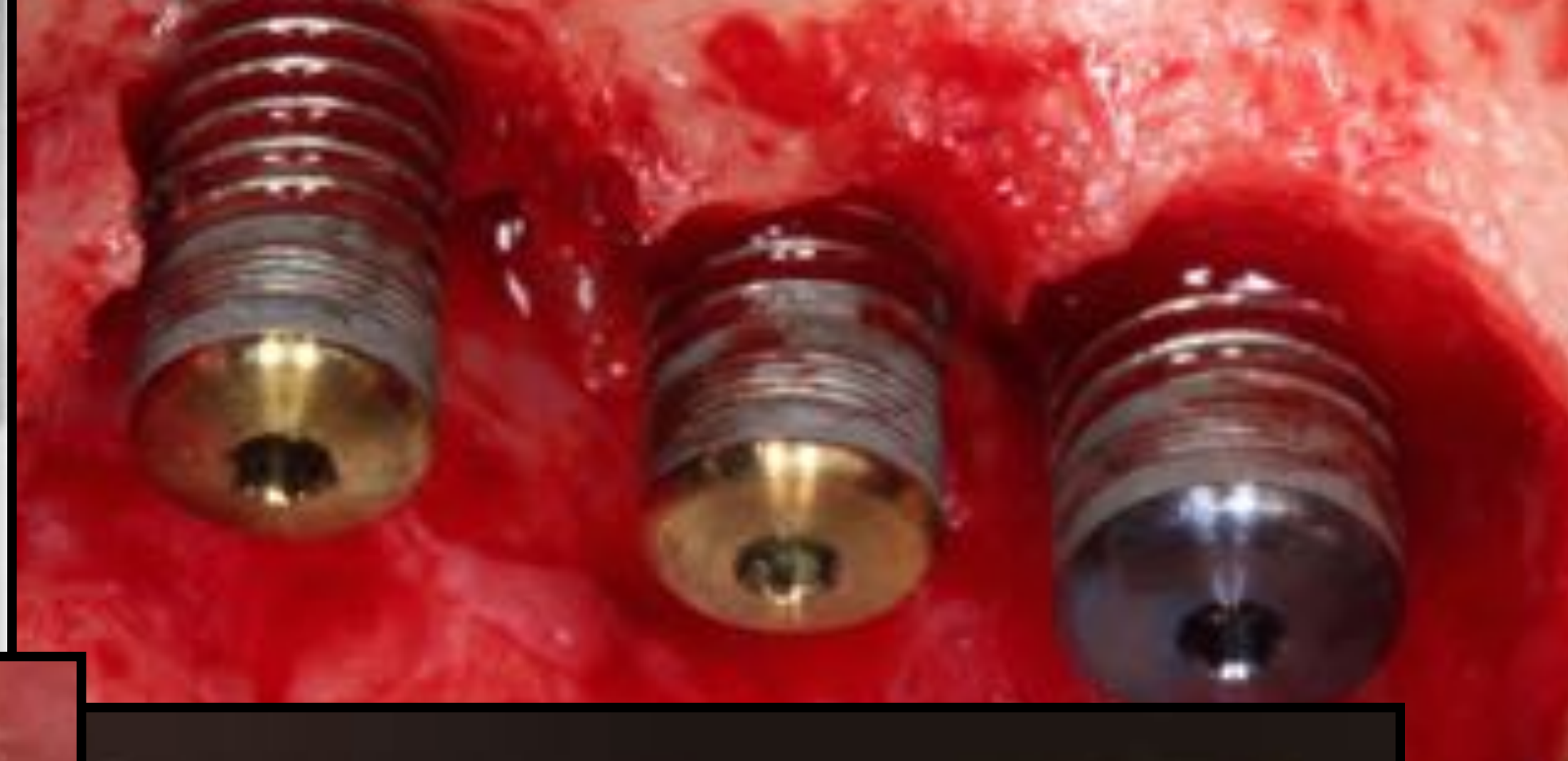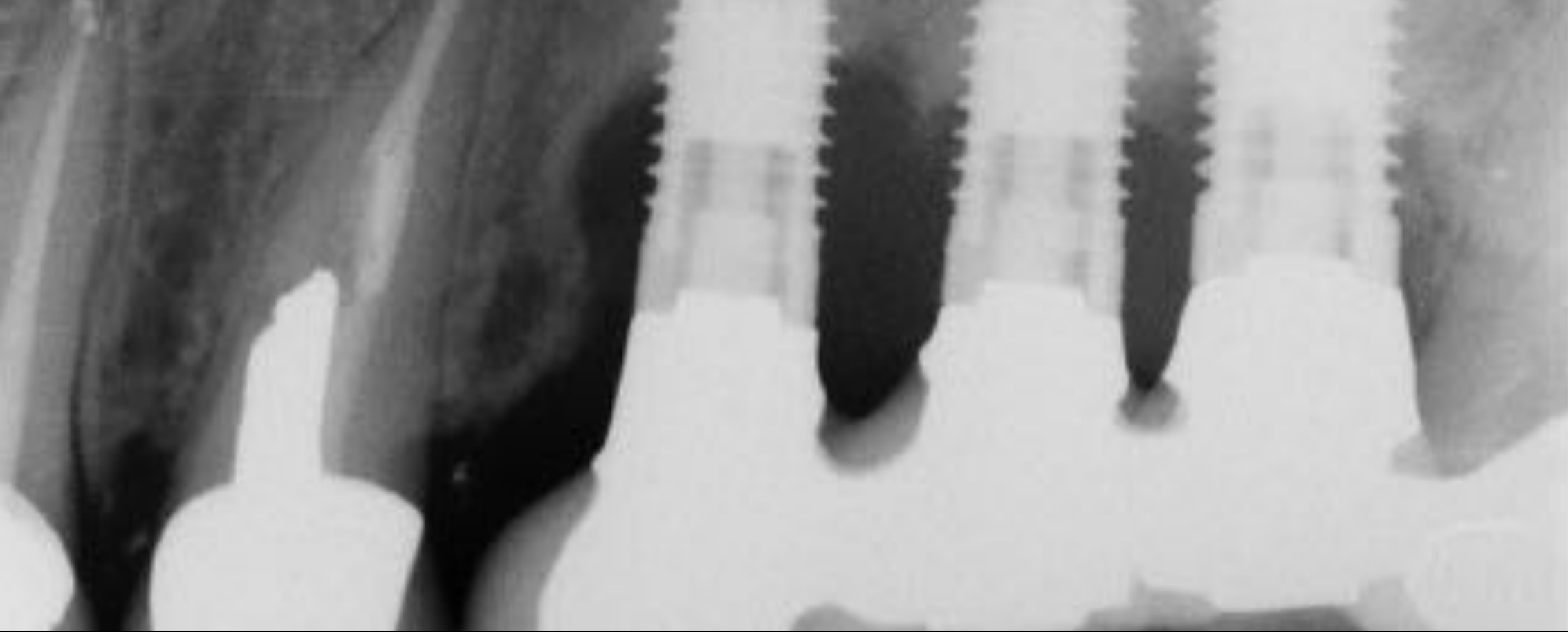












PERIIMPLANTITIS

THEMATIC ABSTRACT REVIEW

Guy Huynh-Ba, DDS, MS

University of Texas Health Science Center, San Antonio, Texas

Section Editor: Clark Stanford, DDS, PhD

The University of Iowa, Iowa City, Iowa

Thomas W. Oates, DMD, PhD

University of Texas Health Science Center
San Antonio, Texas

Martin Osswald, BDS, MDent

University of Alberta
Alberta, Canada

Jan-Elrik Ellingsen, DDS, PhD

University of Oslo
Oslo, Norway

Emad W. Estafanous, BDS, MSD

The University of Iowa
Iowa City, Iowa

Peri-implantitis: “Tsunami” or Marginal Problem?

The use of dental implants has been steadily increasing ever since the early days of osseointegration in the mid-1970s. While the predictability of this treatment modality is undisputed, recent evidence has emerged suggesting that peri-implantitis tends to increase over long-term follow-up.^{1,2}

In 2012, the American Academy of Periodontology

Given the great variation reported in the prevalence or incidence of peri-implantitis and the controversial views of the subject, the present thematic abstract review will focus on studies published during the year 2012 reporting on the prevalence or incidence of peri-implantitis.

Renvert et al (2012) reported an incidence of peri-

THEMATIC ABSTRACT REVIEW

Guy Huynh-Ba, DDS, MS

University of Texas Health Science Center, San Antonio, Texas

Section Editor: Clark Stanford, DDS, PhD

The University of Iowa, Iowa City, Iowa

Thomas W. Oates, DMD, PhD

University of Texas Health Science Center
San Antonio, Texas

Martin Osswald, BDS, MDent

University of Alberta
Alberta, Canada

Jan-Elrik Ellingsen, DDS, PhD

University of Oslo
Oslo, Norway

Emad W. Estafanous, BDS, MSD

The University of Iowa
Iowa City, Iowa

Peri-implantitis: “Tsunami” or Marginal Problem?

The use of dental implants has been steadily increasing ever since the early days of osseointegration in the mid-1970s. While the predictability of this treatment modality is undisputed, recent evidence has emerged suggesting that peri-implantitis tends to increase over long-term follow-up.^{1,2}

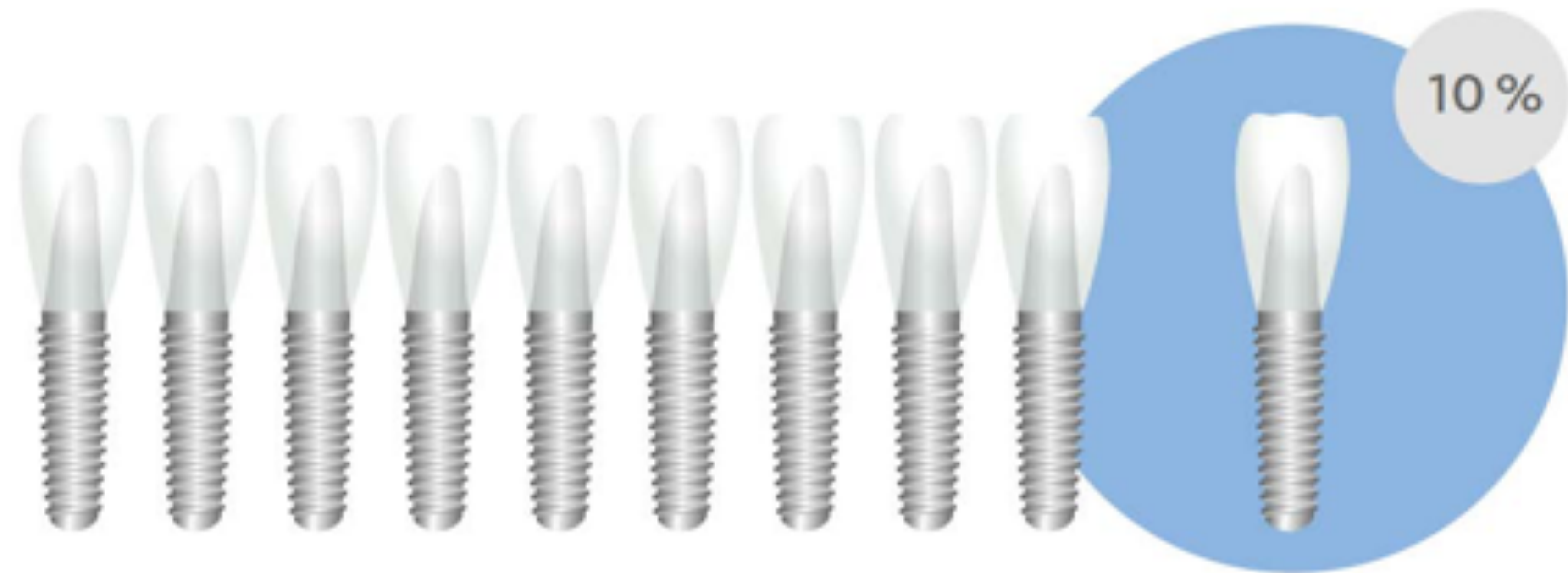In 2012, the American Academy of Periodontology

Given the great variation reported in the prevalence or incidence of peri-implantitis and the controversial views of the subject, the present thematic abstract review will focus on studies published during the year 2012 reporting on the prevalence or incidence of peri-implantitis.

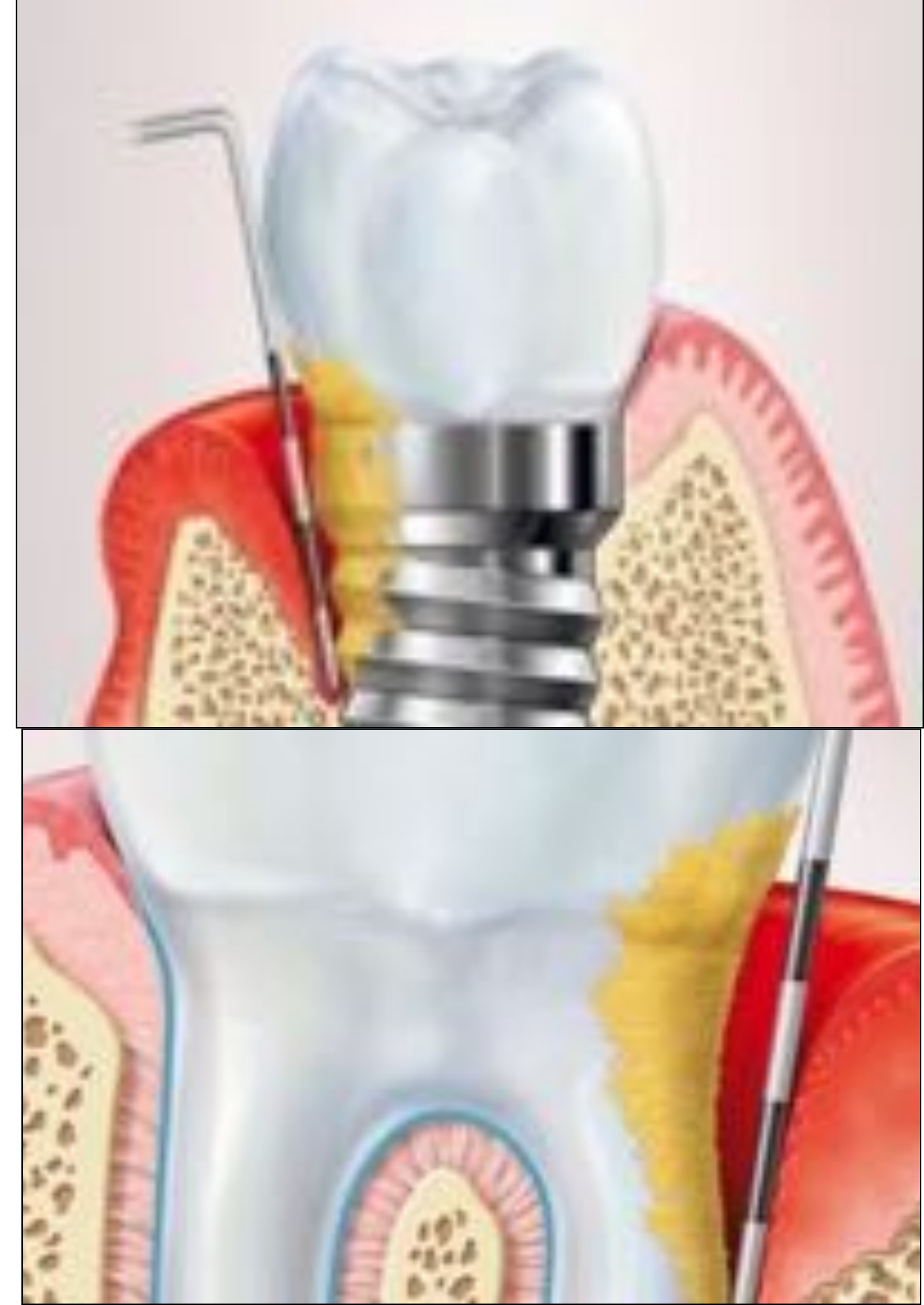
Renvert et al (2012) reported an incidence of peri-

Incidence

- 1-2% [Albrektsson et al 2012](#)
- 6.6% [Roos-Jansåker et al 2006](#)
- 12.2% [Fransson et al 2005](#)
- 28% [Fransson et al 2008](#)
- 47% [Koldslund et al 2010](#)
- 56% [Zitzmann and Berglundh 2008](#)

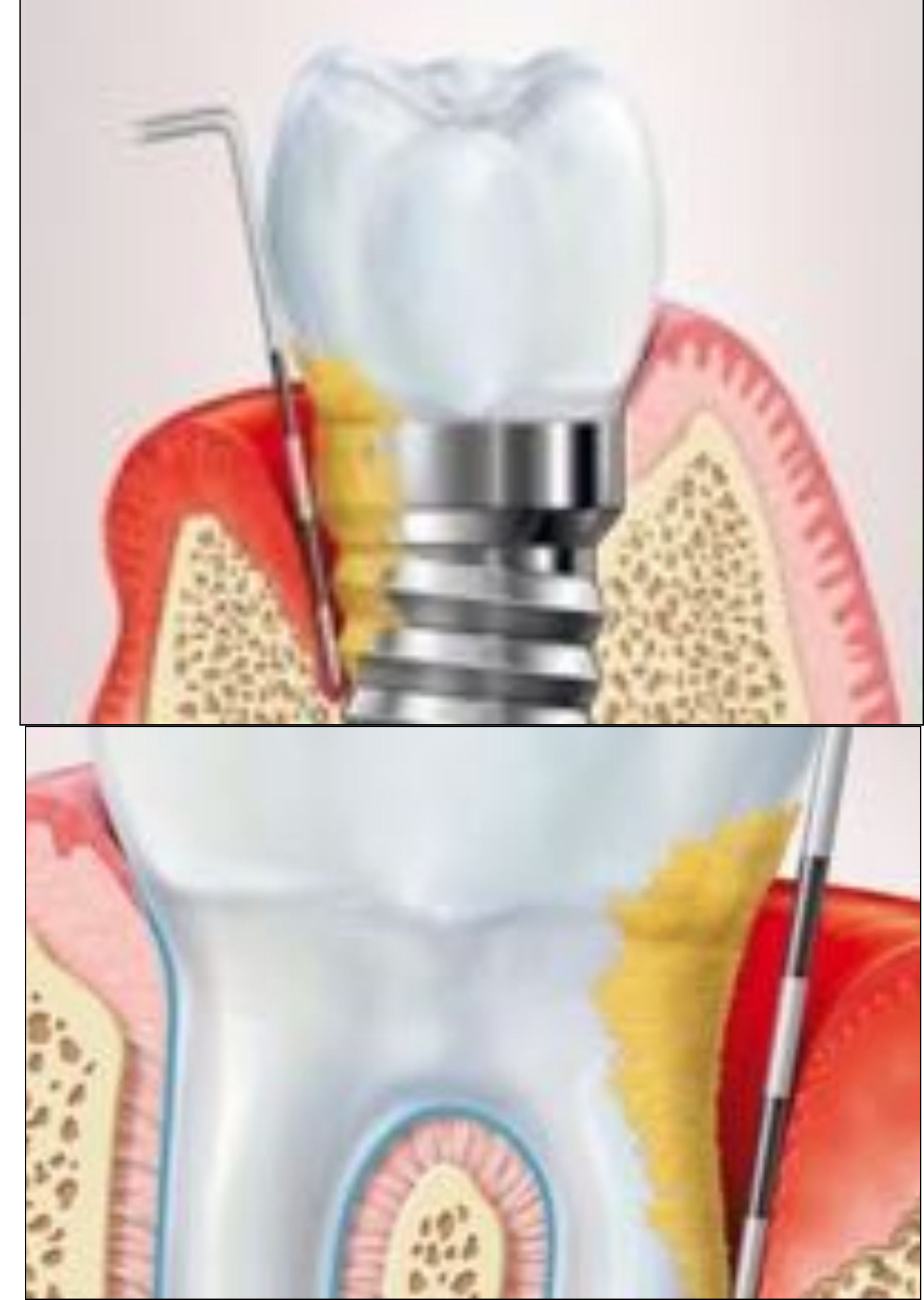


PERIODONTITIS *vs.* PERIMPLANTITIS



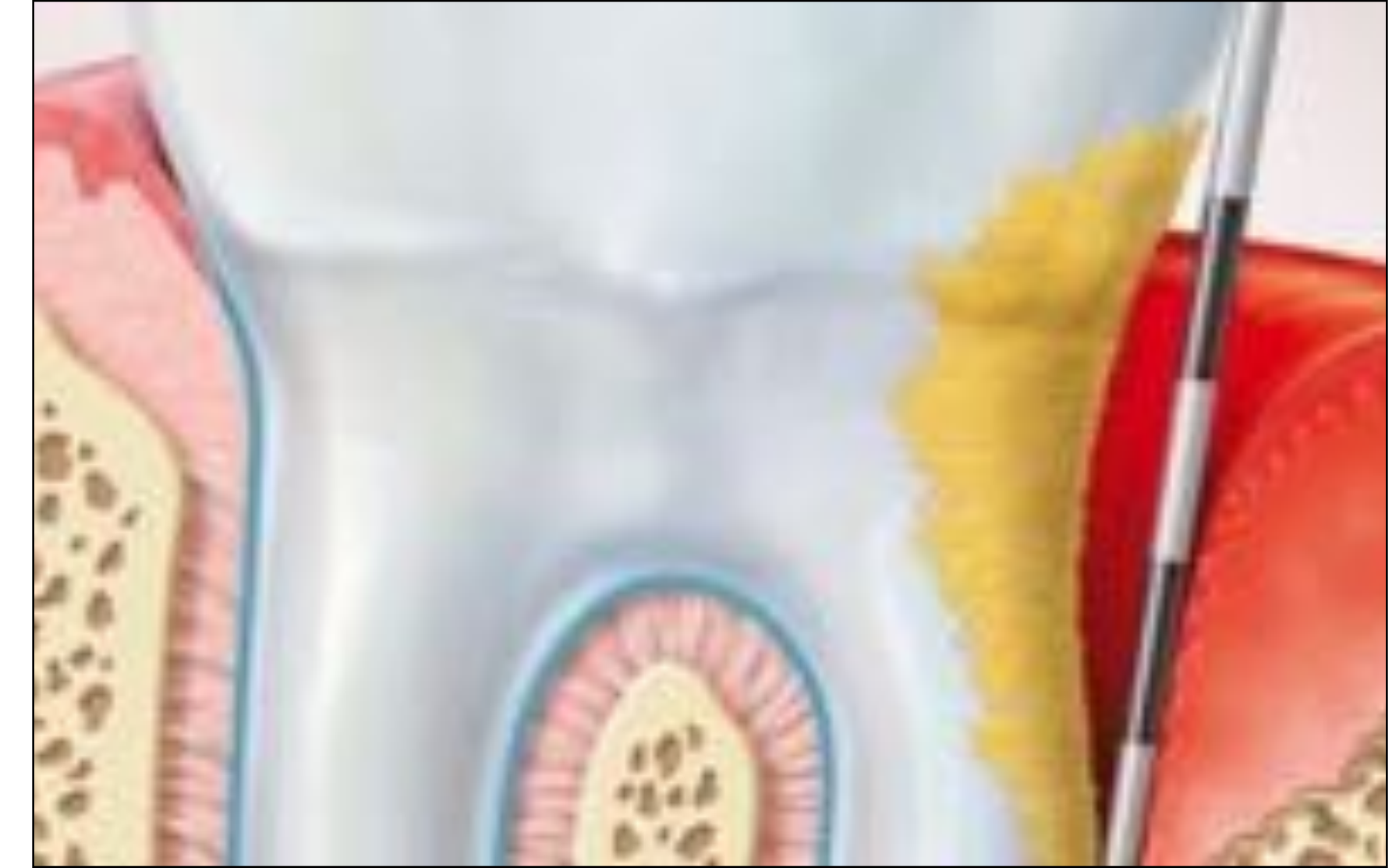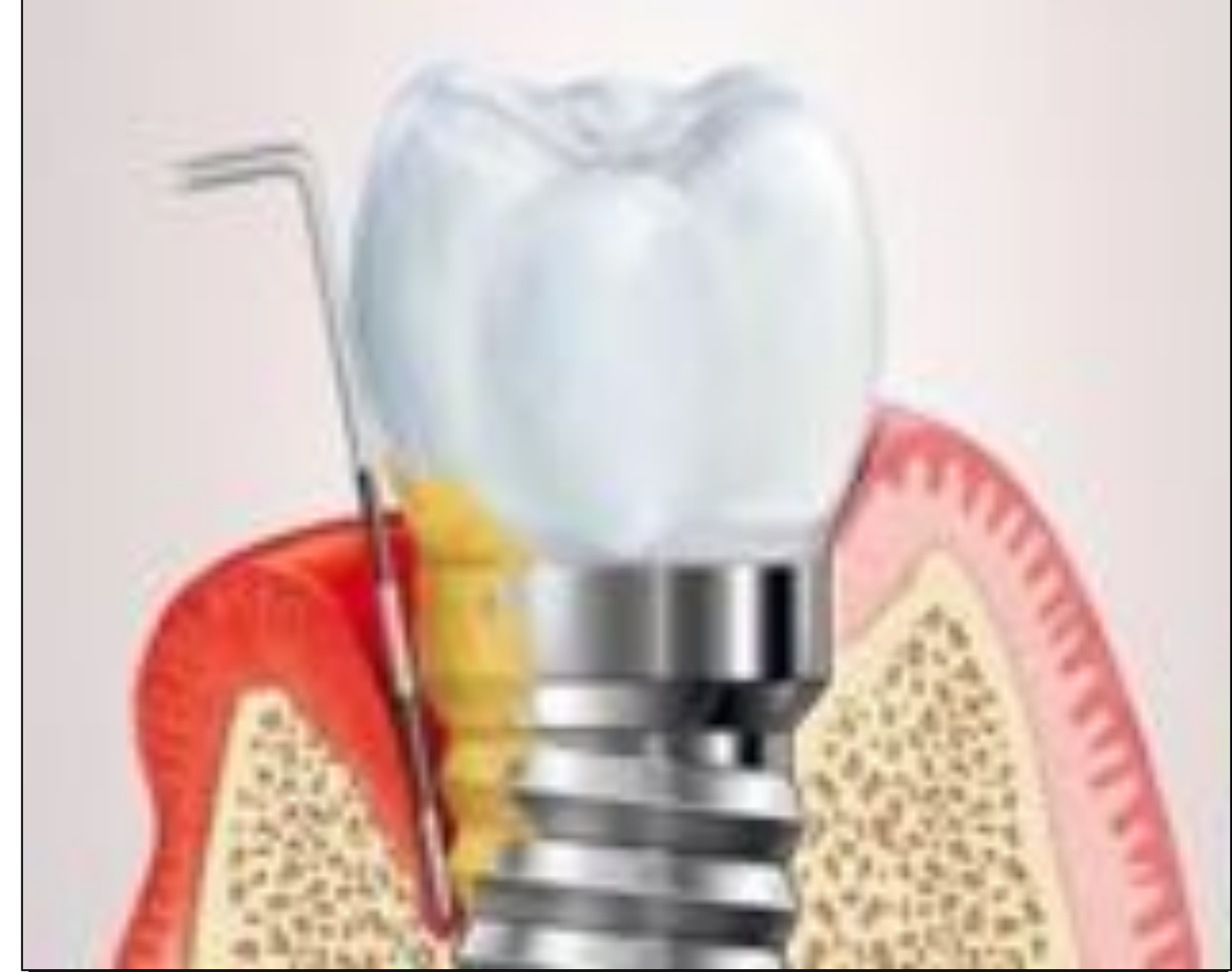PERIODONTITIS *vs.* PERIMPLANTITIS

- similar clinical presentations



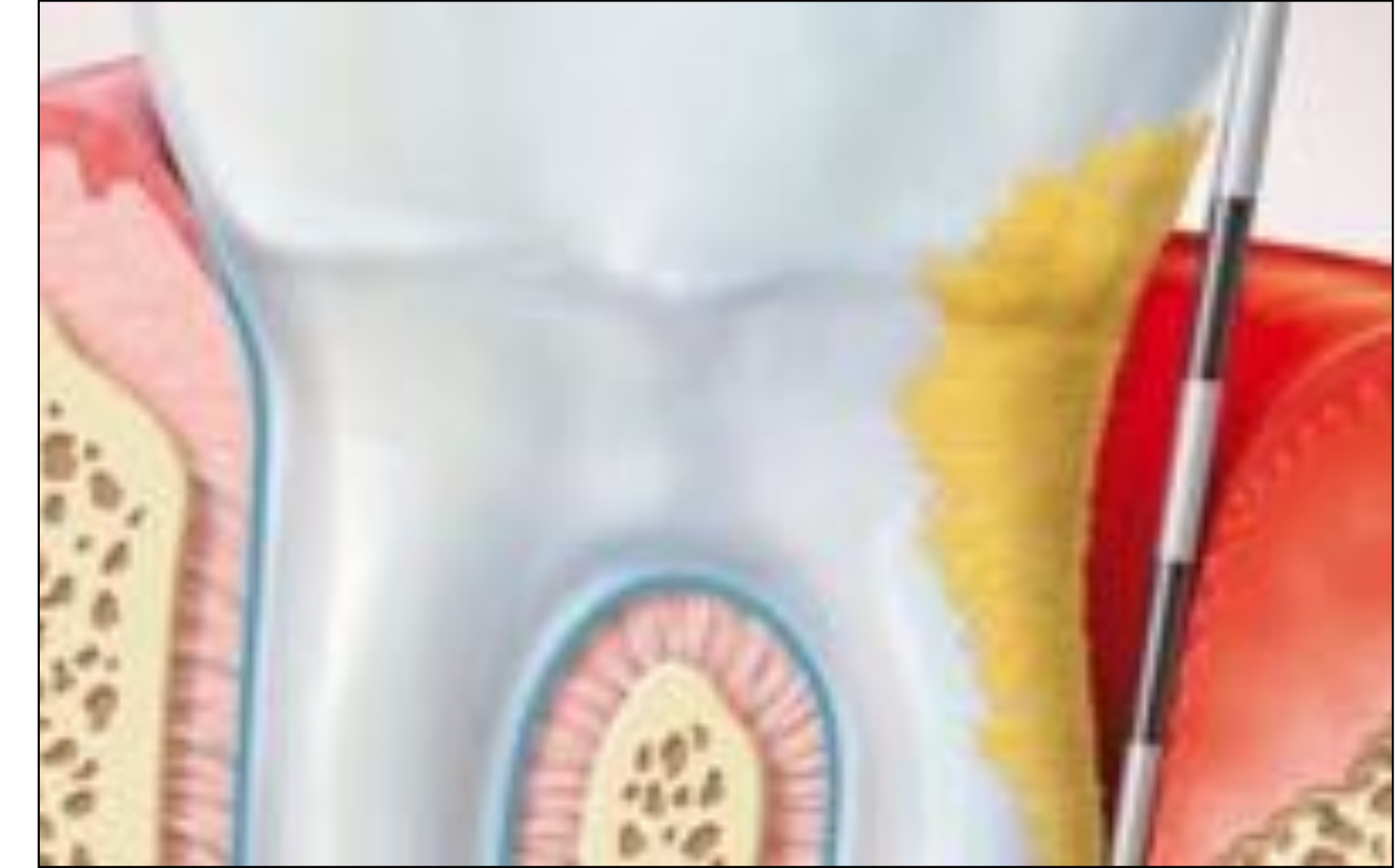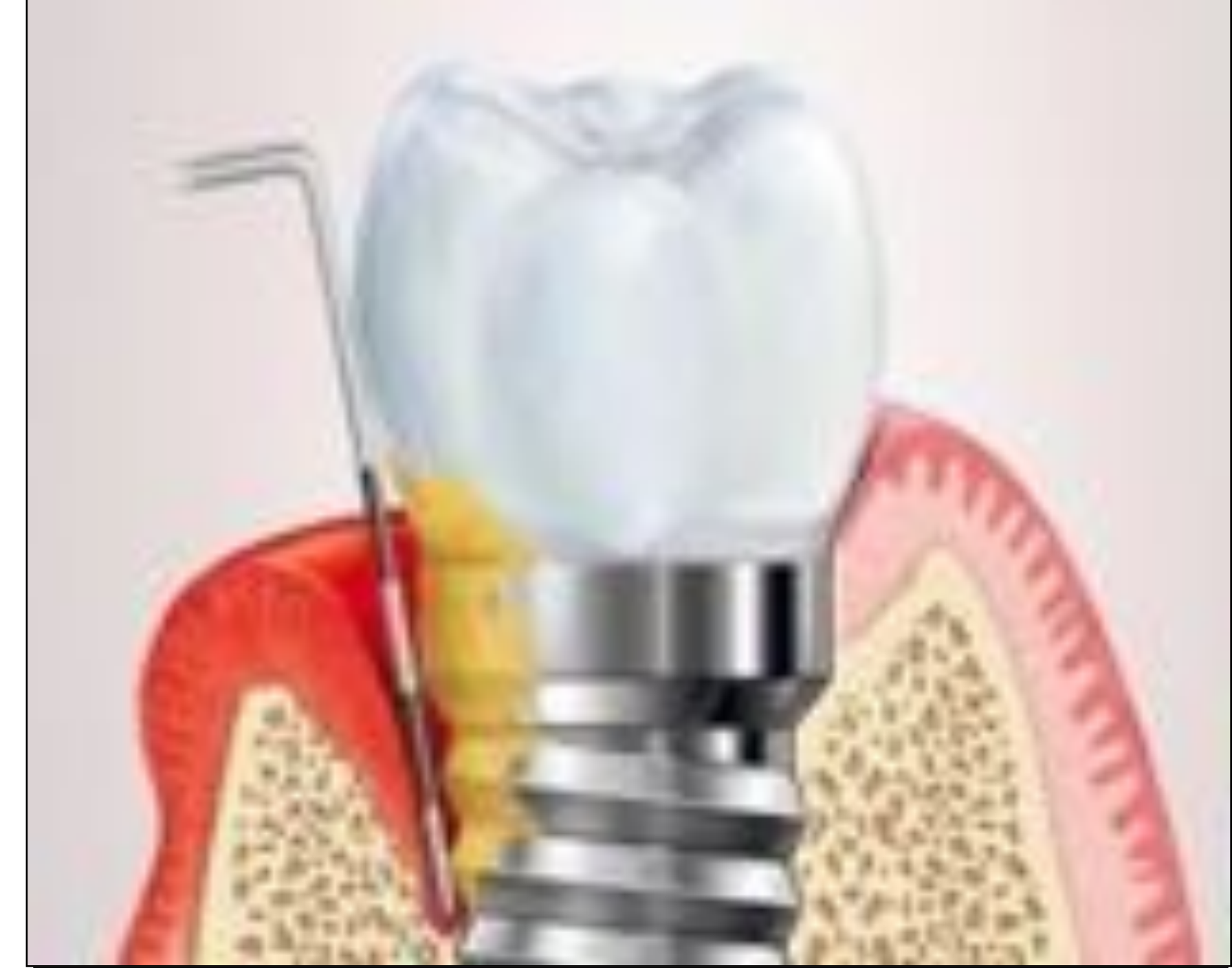PERIODONTITIS *vs.* PERIMPLANTITIS

- similar clinical presentations
- similar microbiological profiles



PERIODONTITIS *vs.* PERIMPLANTITIS

- similar clinical presentations
- similar microbiological profiles
- similar treatment approach

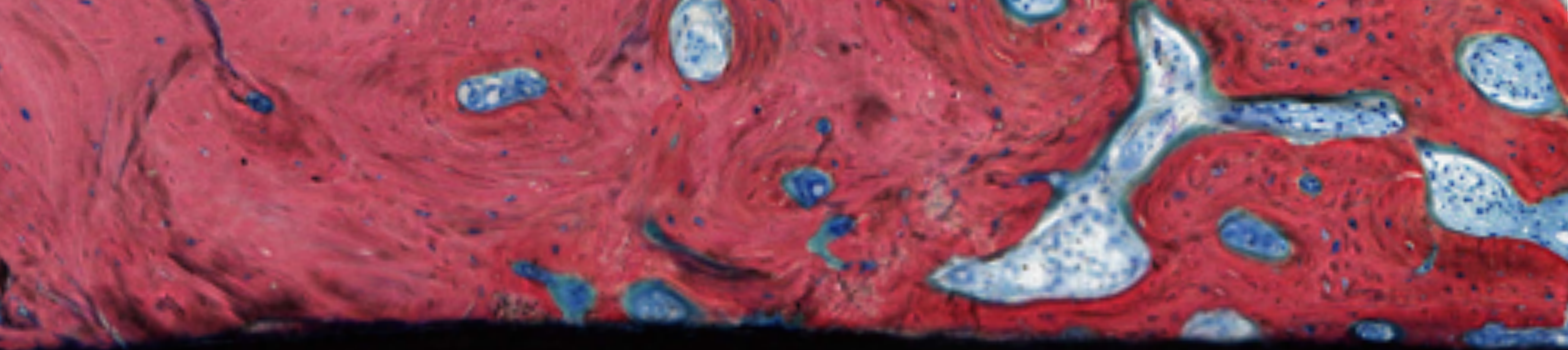


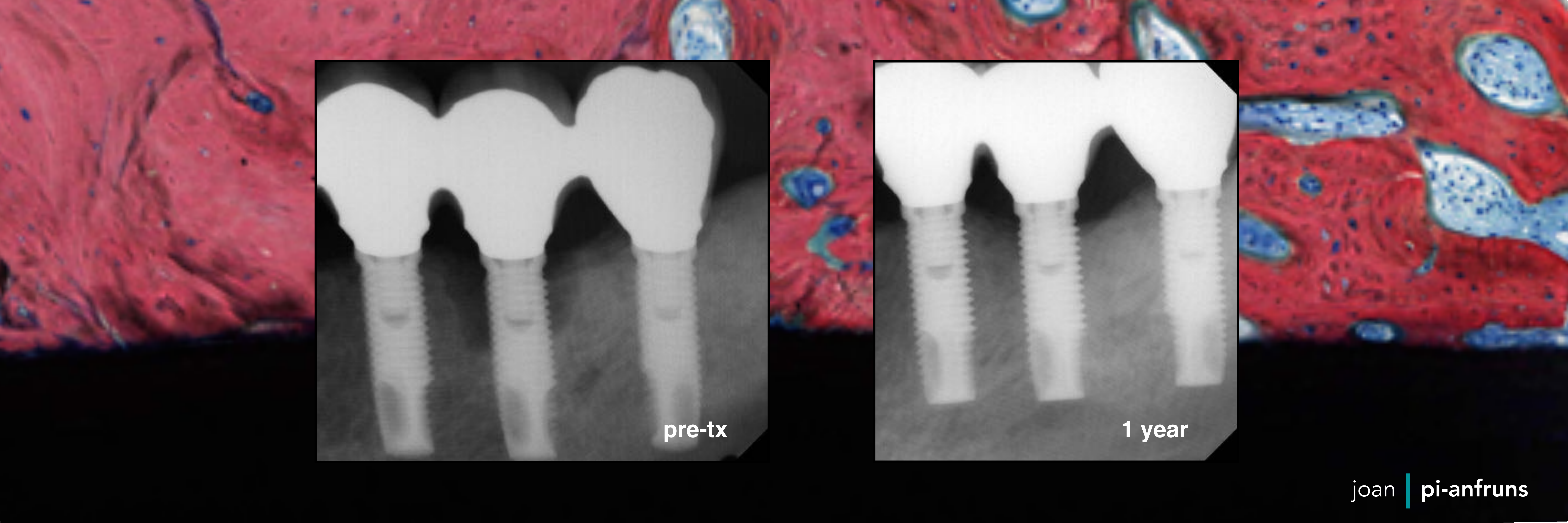
PERIODONTITIS *vs.* PERIMPLANTITIS

- similar clinical presentations
- similar microbiological profiles
- similar treatment approach

discrepancy in the outcome of therapy?

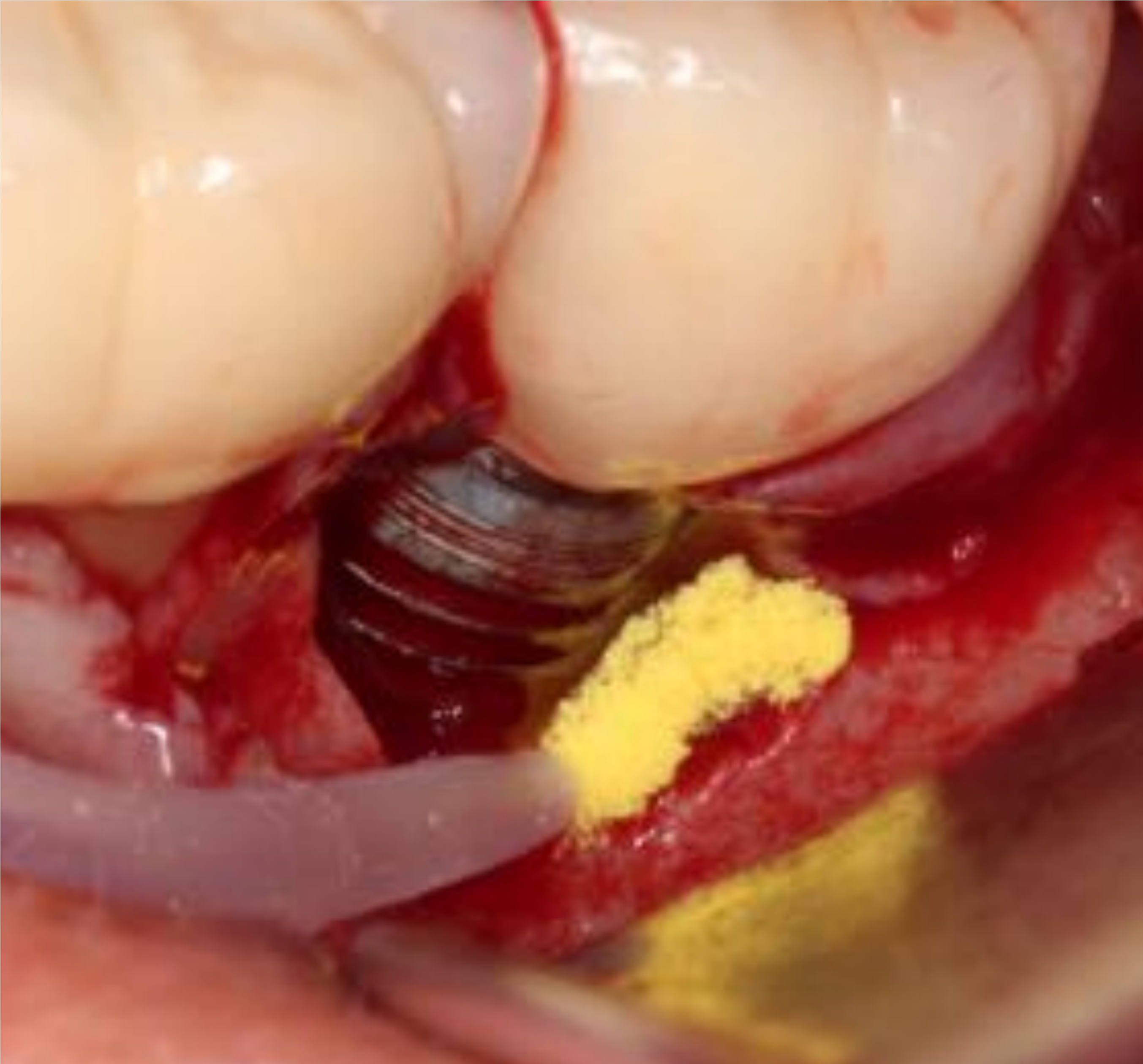





pre-tx

1 year



- outcome therapy of perimplantitis is still considered unpredictable
- relapse incidence of **60%**

General review of titanium toxicity

Kyeong Tae Kim^{1†}, Mi Young Eo^{2†}, Truc Thi Hoang Nguyen² and Soung Min Kim^{1,2,*}**Table 1** Number of articles representing each titanium toxicity trend according to year

	1991–1995	1996–2000	2001–2005	2006–2010	2011–2015	2016–2018
Titanium toxicity	30	58	81	216	432	412
Titanium alloy toxicity	12	17	30	18	40	32
Titanium implant toxicity	8	20	30	26	53	55
Titanium implant corrosion	20	48	59	88	122	120
Titanium allergy	2	5	5	21	22	30
Yellow nail syndrome	22	30	31	39	61	73
Total	94	178	236	408	730	722

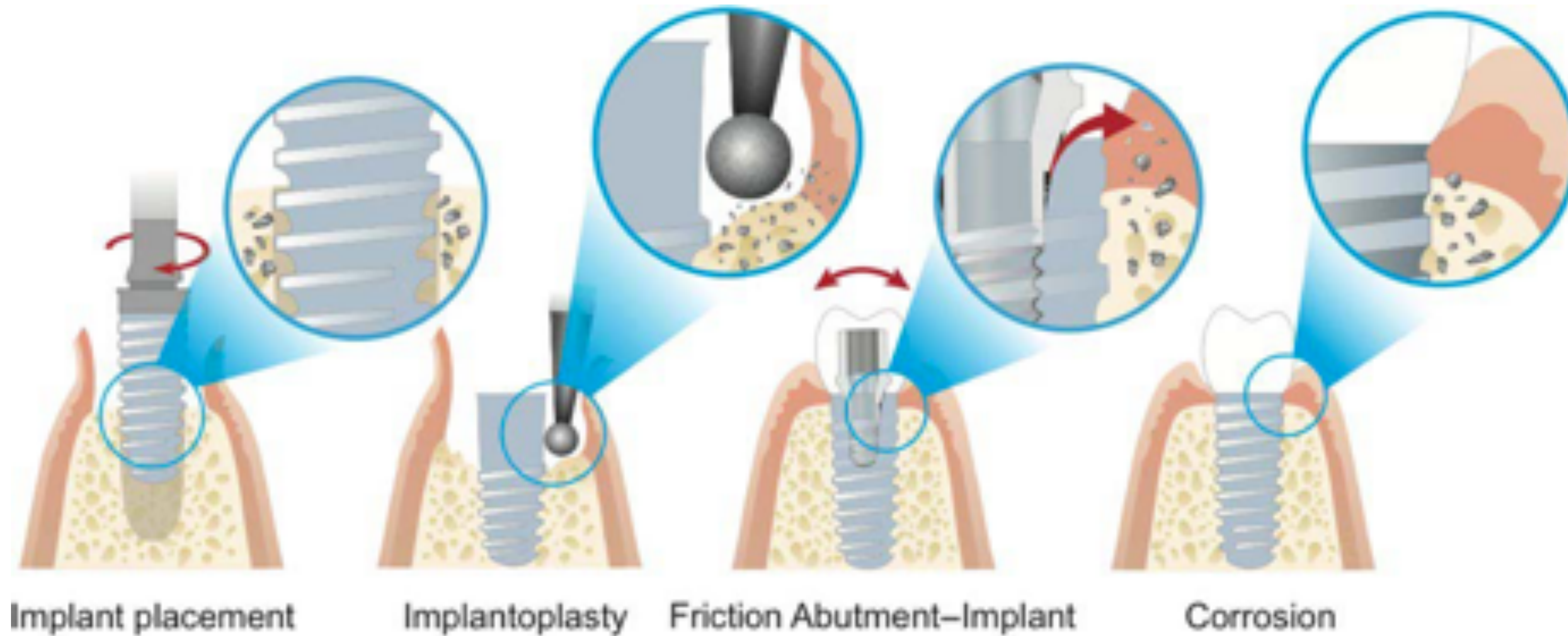
General review of titanium toxicity

Kyeong Tae Kim^{1†}, Mi Young Eo^{2†}, Truc Thi Hoang Nguyen² and Soung Min Kim^{1,2,*}**Table 1** Number of articles representing each titanium toxicity trend according to year

	1991–1995	1996–2000	2001–2005	2006–2010	2011–2015	2016–2018
Titanium toxicity	30	58	81	216	432	412
Titanium alloy toxicity	12	17	30	18	40	32
Titanium implant toxicity	8	20	30	26	53	55
Titanium implant corrosion	20	48	59	88	122	120
Titanium allergy	2	5	5	21	22	30
Yellow nail syndrome	22	30	31	39	61	73
Total	94	178	236	408	730	722

Dental implants-associated release of titanium particles: A systematic review

Fernando Suárez-López del Amo^{1,2} | Carlos Garaicoa-Pazmiño^{1,3} |
Tobias Fretwurst^{1,4} | Rogerio M. Castillo^{1,3} | Cristiane H. Squarize^{1,3}



- Corrosion causes **release of metal ions** to surrounding hard and soft tissues, lymph nodes and peripheral or even distant organs
- Ti particles cause **changes in the DNA** of the peri-implant micro-organisms
- increased risk and incidence of **inflammatory disease**
- more Ti particles found in implants affected by **peri-implantitis**

Alberto Sicilia
Susana Cuesta
Gerardo Corra
Ignacio Arregui
Cristina Giménez
Eduardo Ruiz
Antonio Maestro

Titanium allergy in dental implant
patients: a clinical study on 1500
consecutive patients

CLINICAL ORAL IMPLANTS RESEARCH

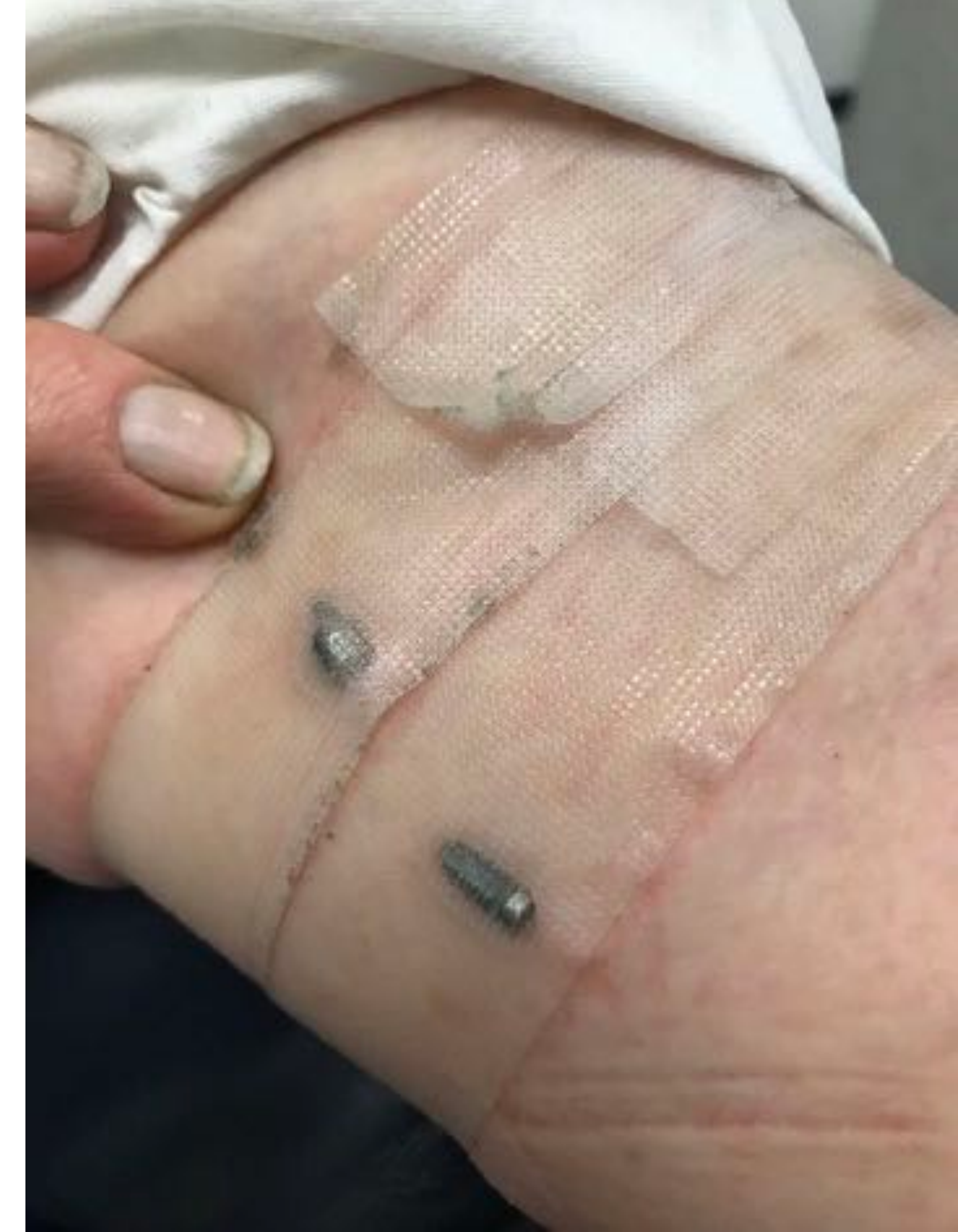Allauddin Siddiqi
Alan G. T. Payne
Rohana Kumara De Silva
Warwick J. Duncan

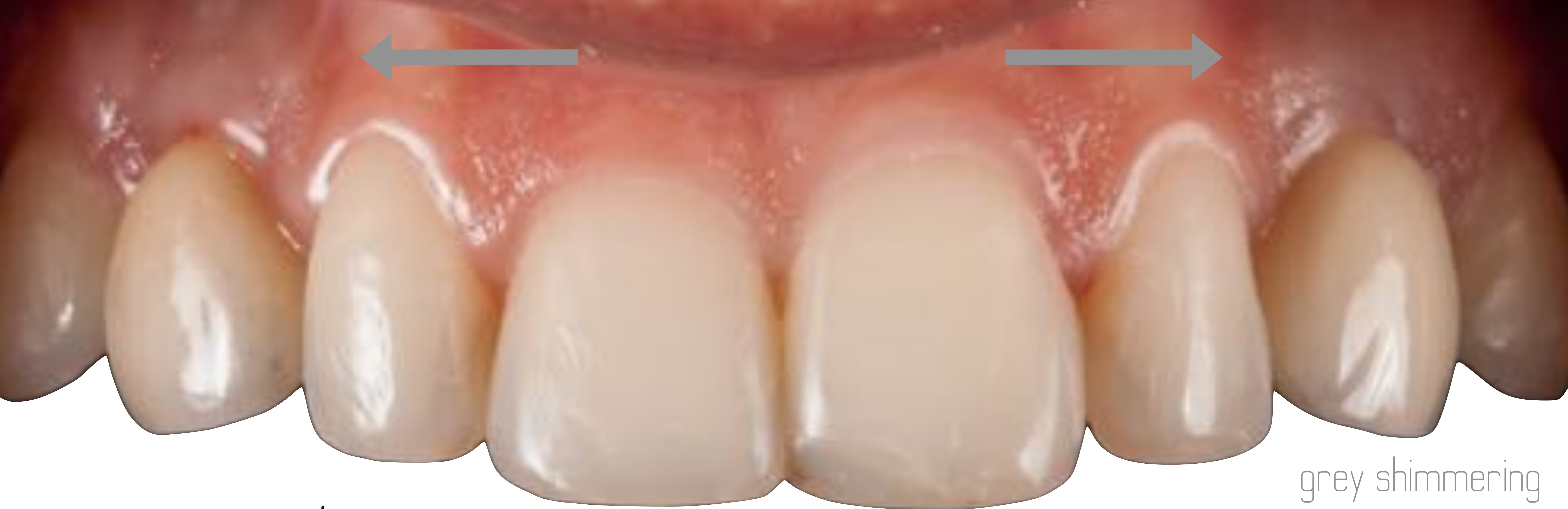Review
Titanium allergy: could it affect dental
implant integration?

- titanium allergy
- high demand for “metal-free”, holistic dentistry



HOLISTIC
DENTISTRY





grey shimmering



Zirconia

Zircon

Zirconium

Zirconia

Zircon

- the raw material, a mineral
- 80% of zircon mining occurs in Australia and South Africa
- this zircon sand is the raw material to obtain zirconium (Zr), a metal



Zircon

Zirconium

Zirconia

Zirconium

- to obtain the pure metal, the “Van Arkel” process is used to obtain a zirconium sponge called **Zirconium crystal-bar**
- the “crystal-bar” can be melted to obtain the **Zirconium rod**
- pure zirconium is mainly used in the **nuclear reactors** as containers for the nuclear fuel, and also to form compounds
- highly resistant to corrosion.



zirconium crystal bar



pure zirconium rod

Zircon

Zirconium

Zirconia

Zirconia

- Zirconium undergoes a reductive chlorination process, known as the *Kroll process*
- At the end of this process, one can obtain **zirconium oxide powder**
- this is a ceramic and no longer a metal



Zirconium

grey metallic color
weak metallic bonds
malleable
ductile
wear
thermic conductor
electric conductor
easy oxidation
chemical corrosion
used in nuclear reactors

Zirconia

white color
strong covalent bonds
hard
fragile
wear resistant
thermic insulator
electric insulator
oxidation resistant
no chemical corrosion
used in technical ceramics

Zirconia

- used as pigment for white paints, jewelry and as an abrasive material
- at room temperature presents a *monoclinic phase*, in which the material is very fragile
- to stabilize the compound, other elements can be added **yttrium oxide**, element of choice for dental implants

Y-TZP Yttrium-Stabilized Tetragonal Zirconia Polycrystal




	tetragonal zirconia	cubic zirconia	zirconium	zircon
material family	ceramic	ceramic	metal	mineral
chemical formula	ZrO ₂ Y ₂ O ₃	ZrO ₂	Zr	ZrSiO ₄
chemical name	Yttrium Tetragonal Zirconia	Zirconium Dioxide	Zirconium	Zirconium Silicate
applications	Dentistry, Orthopaedics, Aerospace	Jewelry	Construction, Nuclear	Rarely Used

zirconia advantages

- in vitro three-species biofilm or human plaque samples were applied for bacterial adhesion to each type of disk
- 72 hours of incubation was assessed using an anaerobic flow chamber model

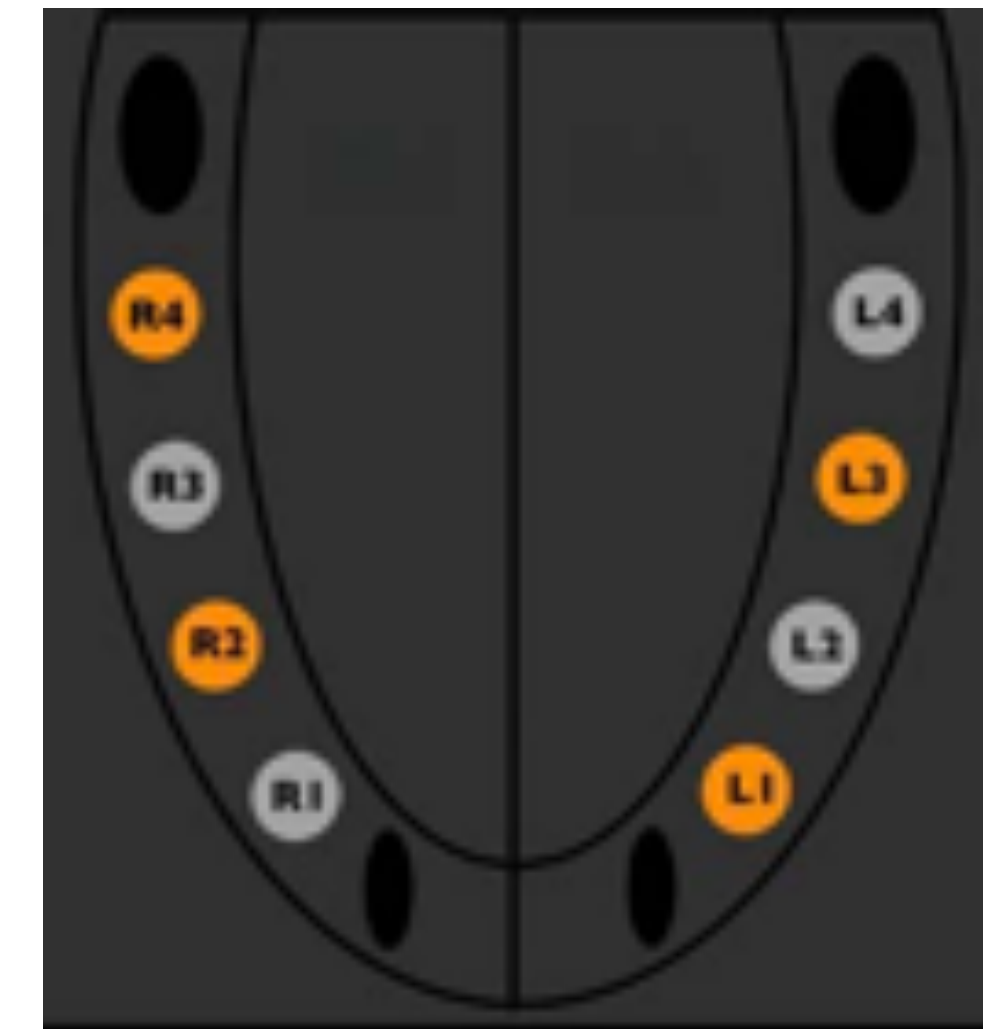
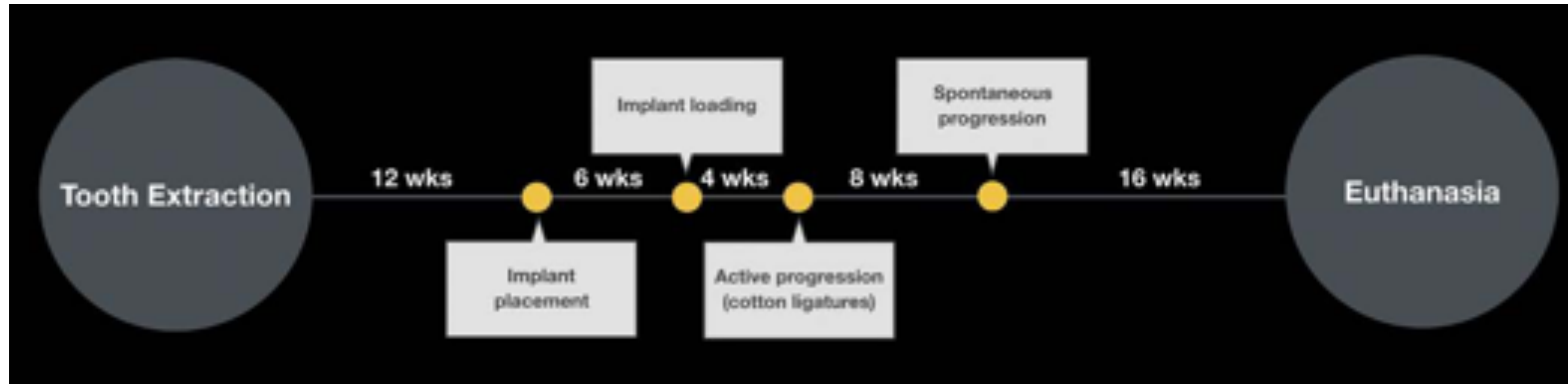
- ➔ Zirconia showed a statistically significant reduction in three-species **biofilm thickness** compared with titanium
- ➔ statistically significant reduction in human plaque **biofilm formation**



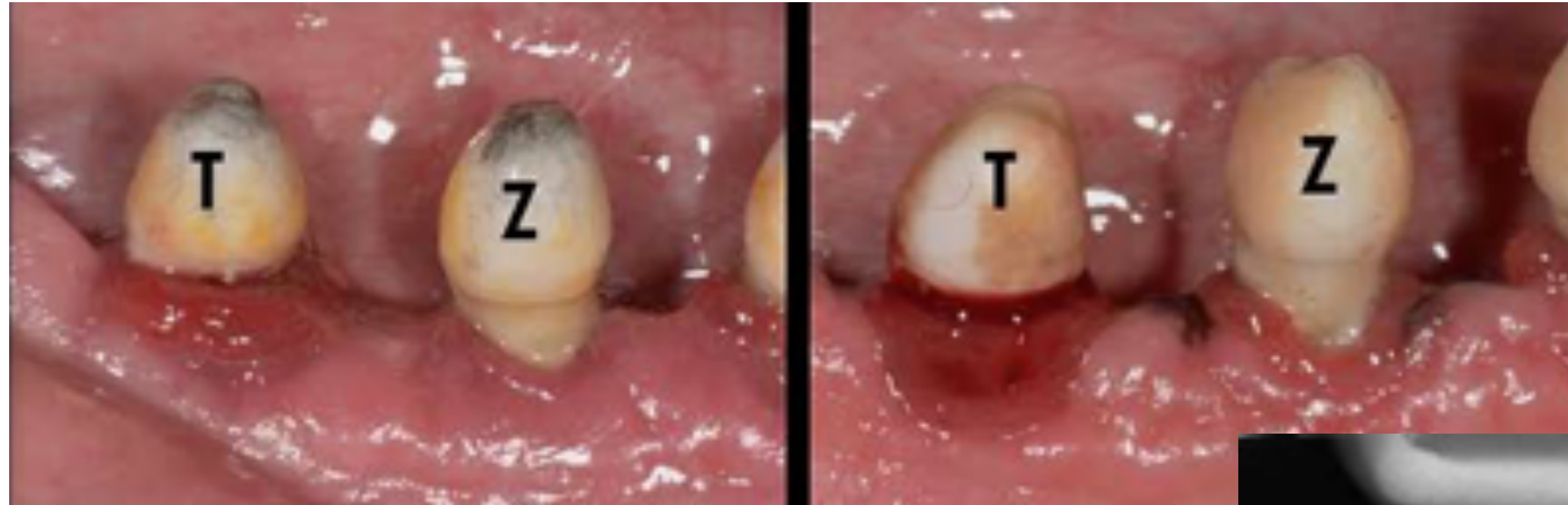
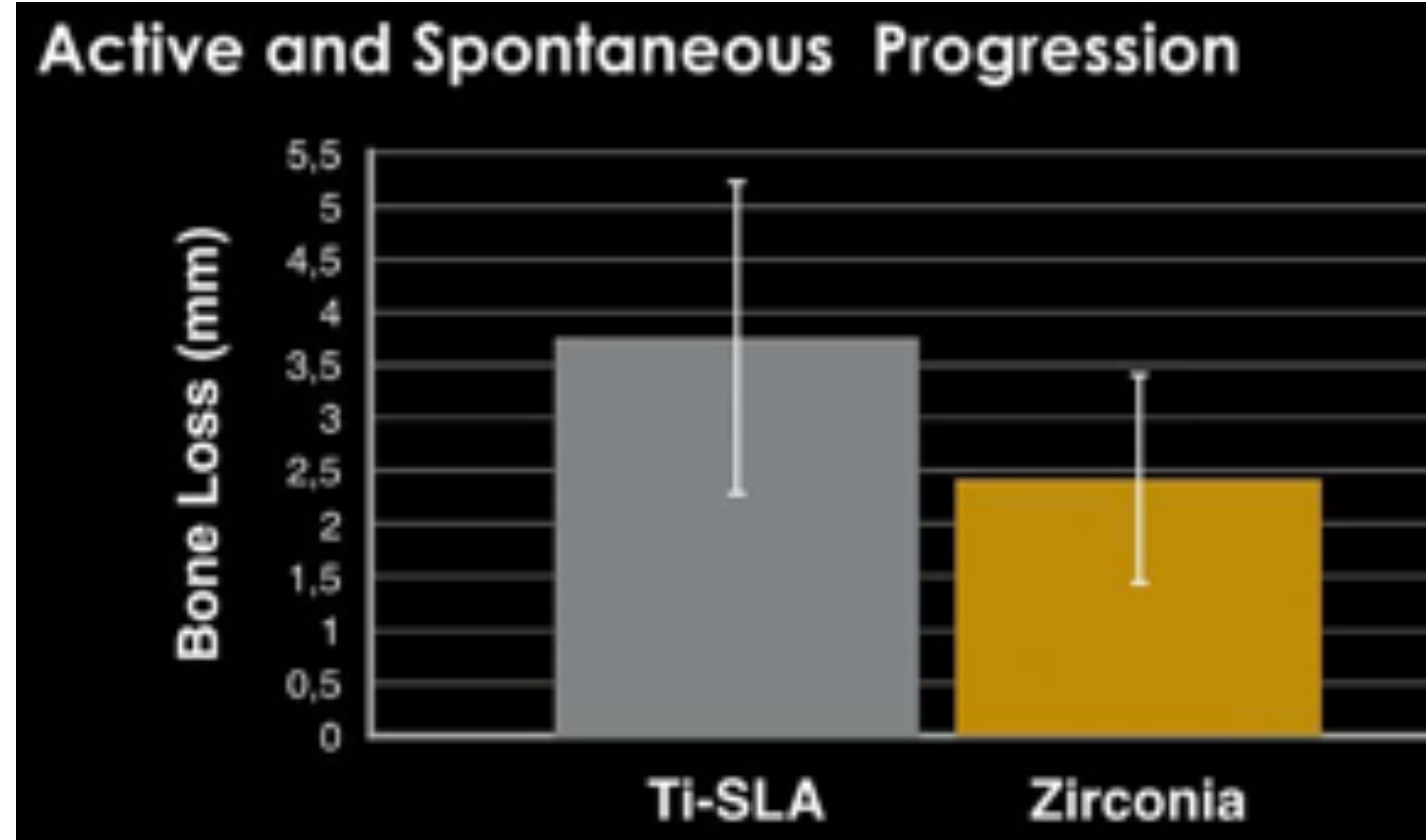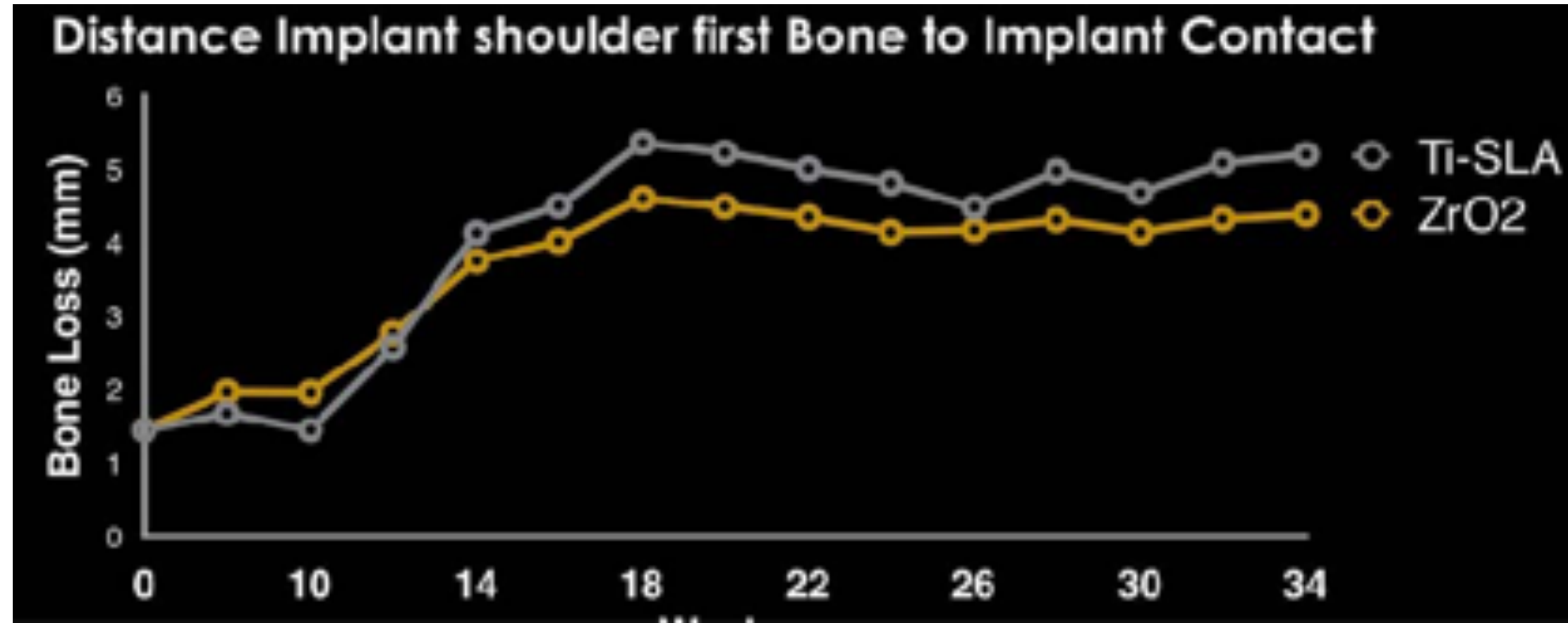
zirconia advantages

Ligature-Induced Peri-implant Bone Loss Around Loaded Zirconia and Titanium Implants

Stefan Roehling, DDS¹/Michael Gahlert, DDS, PhD²/Simone Janner, DDS³/
Bo Meng, DDS⁴/Henriette Woelfler, PhD⁵/David L. Cochran, BA, MS, DDS, PhD, MMS⁴



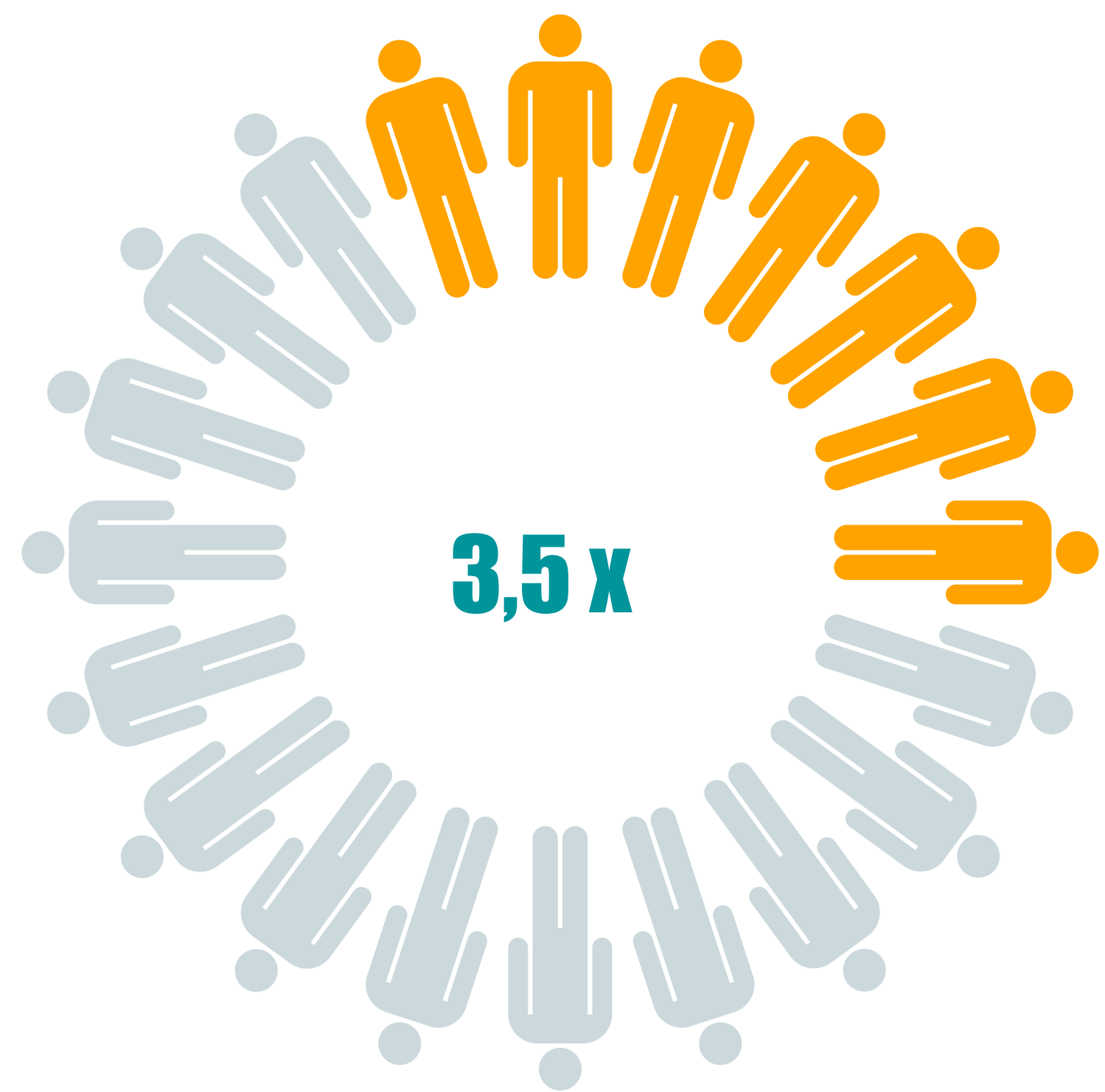
zirconia advantages




Ligature-Induced Peri-implant Bone Loss Around Loaded Zirconia and Titanium Implants

Stefan Roehling, DDS¹/Michael Gahlert, DDS, PhD²/Simone Janner, DDS³/
Bo Meng, DDS⁴/Henriette Woelfler, PhD⁵/David L. Cochran, BA, MS, DDS, PhD, MMS⁴

SURVEY



Prefer ceramic implants

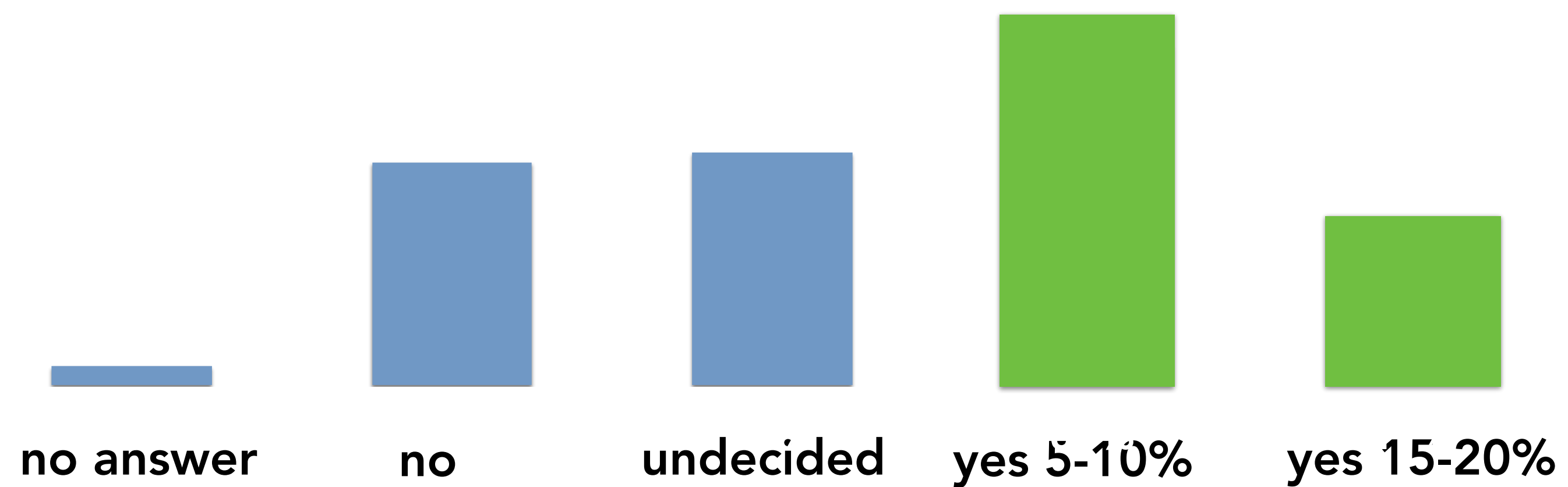


Prefer titanium implants



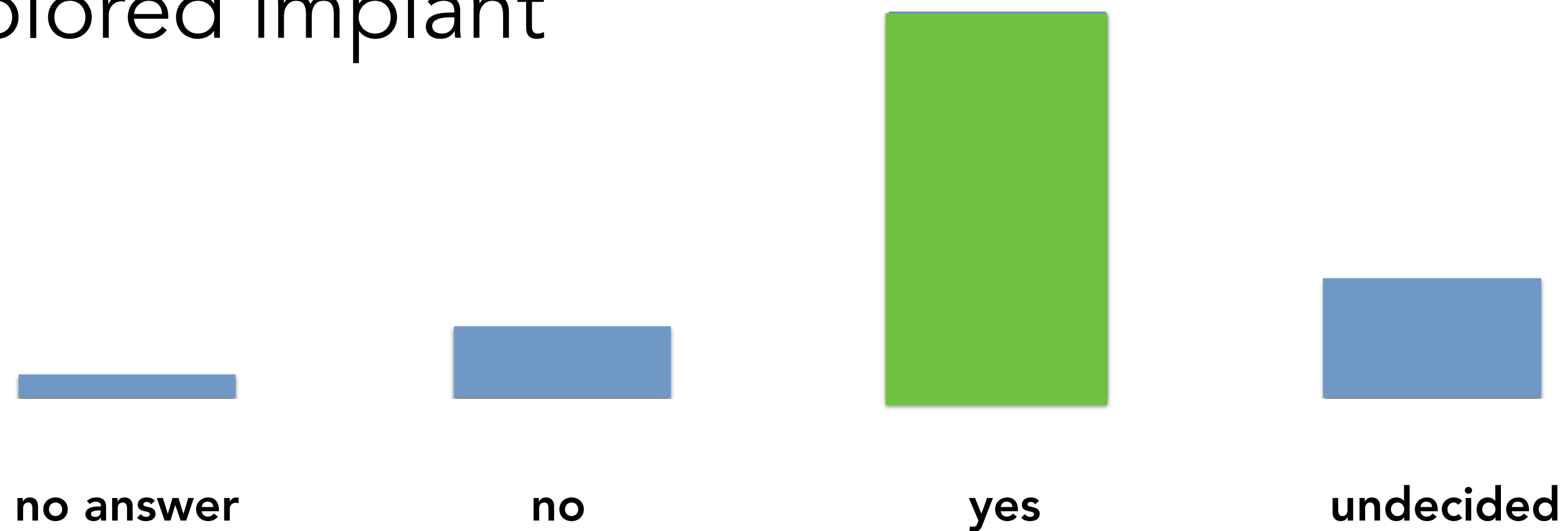
SURVEY

- 1/3 of the respondents accepts **higher costs** for tooth colored implant



SURVEY

- 64% of patients accept **longer treatment** procedure for tooth colored implant



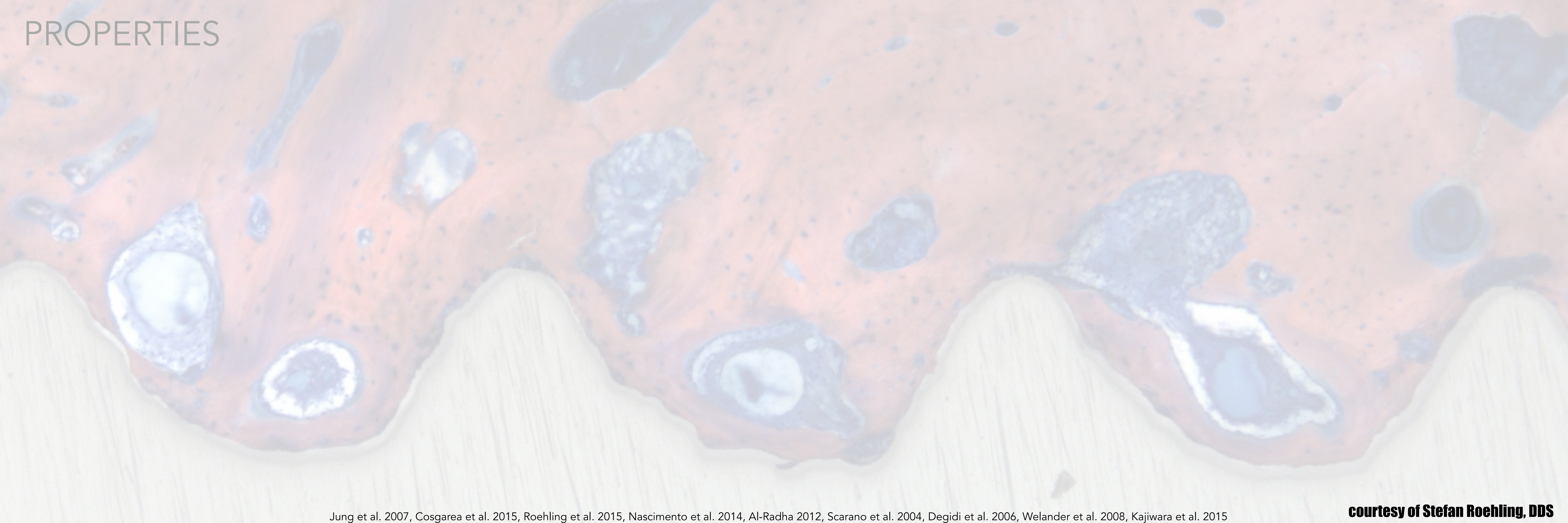
PROPERTIES



Jung et al. 2007, Cosgarea et al. 2015, Roehling et al. 2015, Nascimento et al. 2014, Al-Radha 2012, Scarano et al. 2004, Degidi et al. 2006, Welander et al. 2008, Kajiwara et al. 2015

courtesy of Stefan Roehling, DDS

PROPERTIES



PROPERTIES

- Less mucosa discoloration/ better **color match** to the soft tissue at natural teeth than with titanium

PROPERTIES

- Less mucosa discoloration/ better **color match** to the soft tissue at natural teeth than with titanium
- Significantly lower **bacterial adhesion** than with titanium surfaces

PROPERTIES

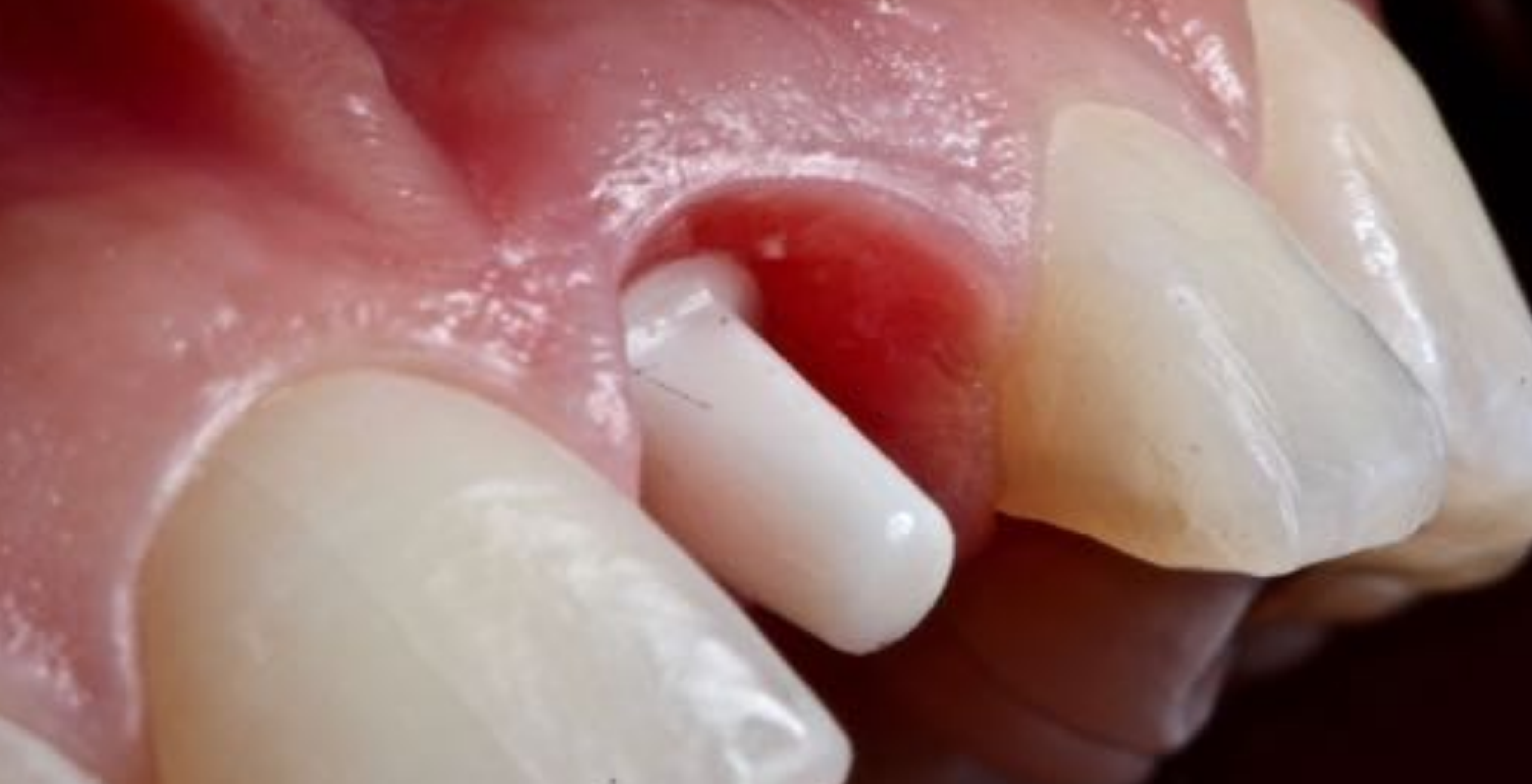- Less mucosa discoloration/ better **color match** to the soft tissue at natural teeth than with titanium
- Significantly lower **bacterial adhesion** than with titanium surfaces
- Less **inflammatory infiltration** in the peri-implant tissue than with gold and titanium

PROPERTIES

- Less mucosa discoloration/ better **color match** to the soft tissue at natural teeth than with titanium
- Significantly lower **bacterial adhesion** than with titanium surfaces
- Less **inflammatory infiltration** in the peri-implant tissue than with gold and titanium
- Favorable for the formation of **epithelial attachments** and mucosal obturation

PROPERTIES

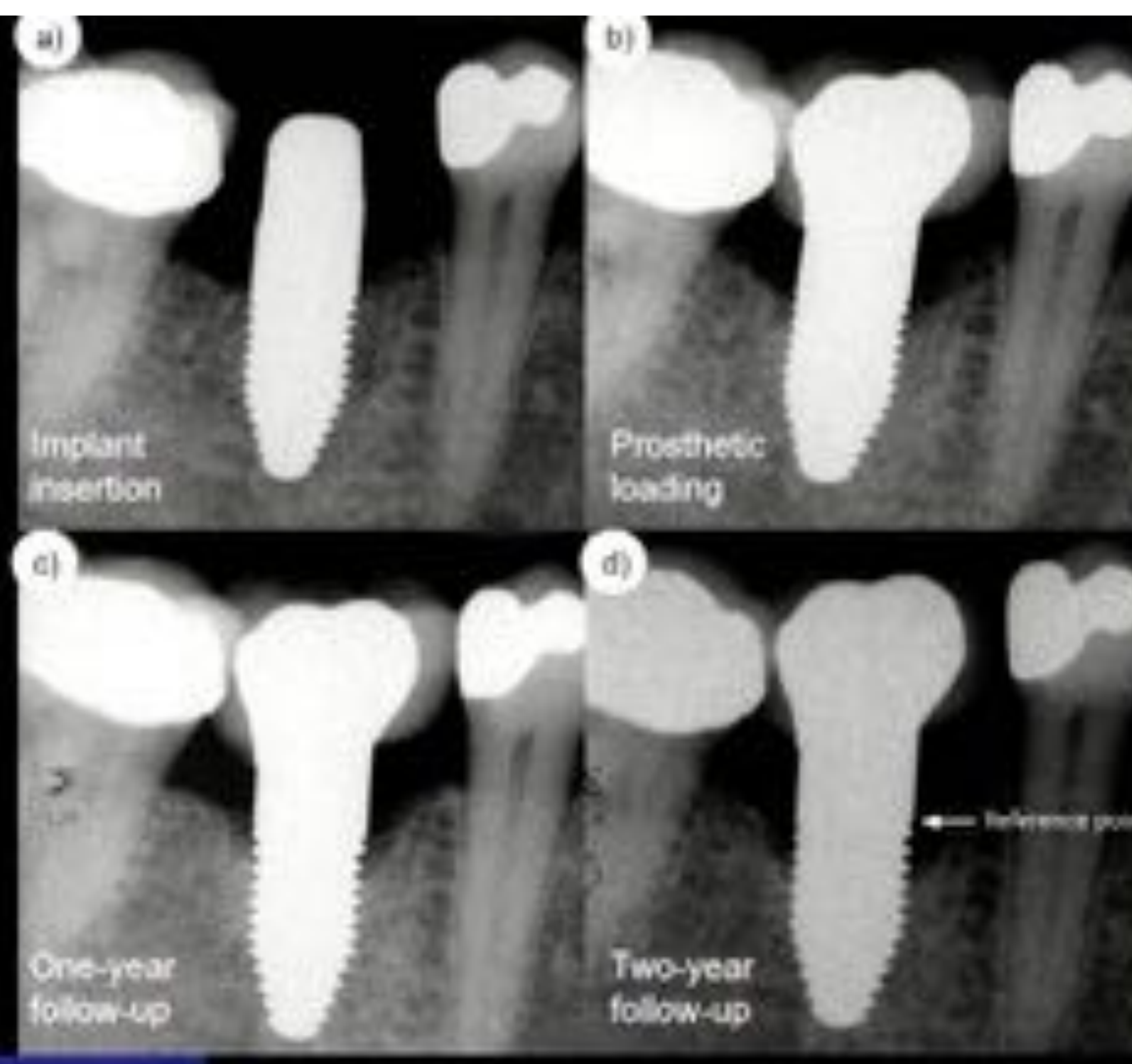- Less mucosa discoloration/ better **color match** to the soft tissue at natural teeth than with titanium
- Significantly lower **bacterial adhesion** than with titanium surfaces
- Less **inflammatory infiltration** in the peri-implant tissue than with gold and titanium
- Favorable for the formation of **epithelial attachments** and mucosal obturation
- Significantly increased **micro-circulation** in peri-implant soft tissue compared to titanium



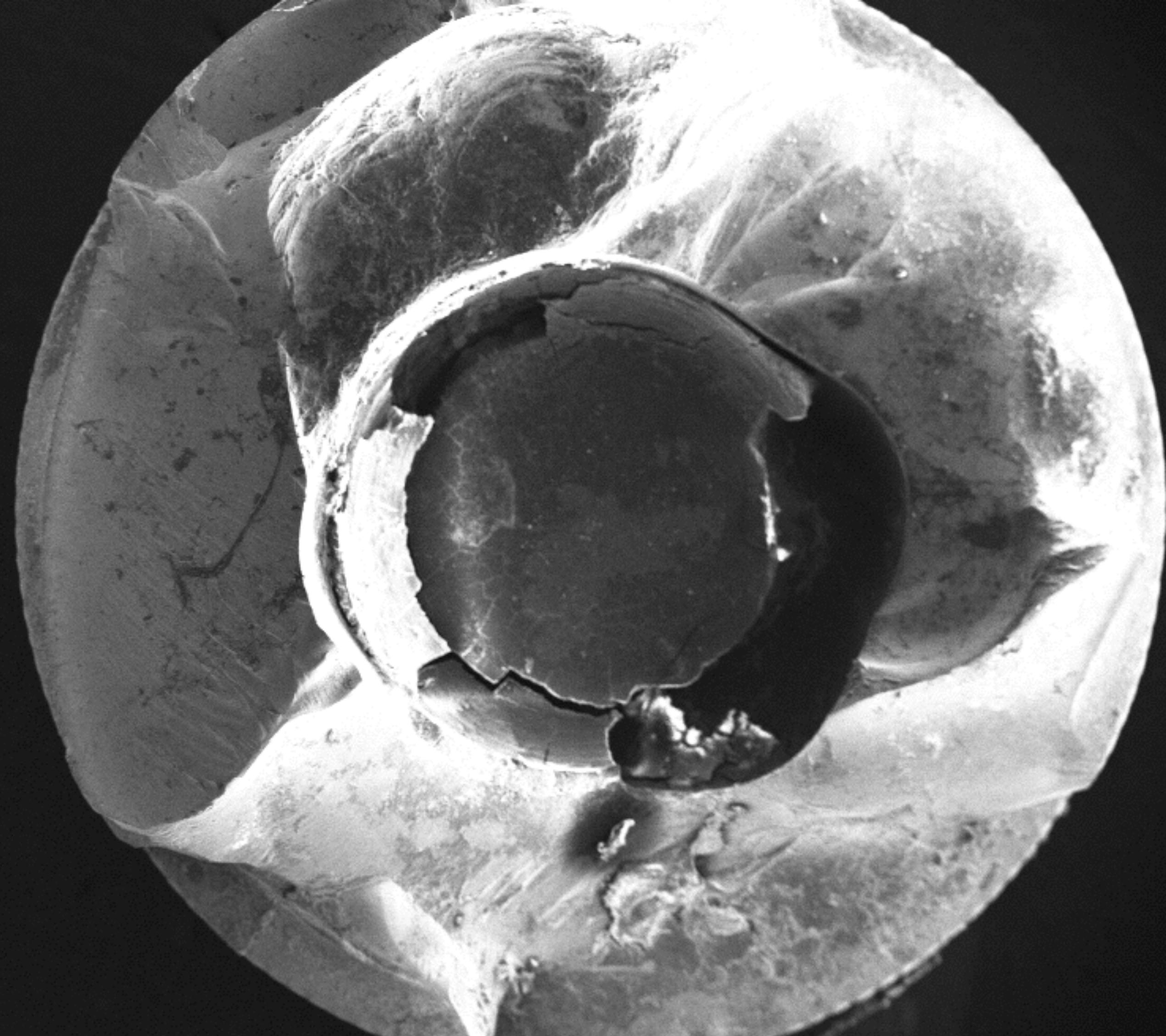- ✓ comparable osseointegration
- ✓ excellent soft tissue behavior
- ✓ good biological response
- ✓ aesthetic outcome

ZiUnite one-piece zirconia implant, Sa 1.24

- Cumulative survival rate of 90.8%, six posterior implants were lost but none due to fracture
- Mean marginal bone loss was 1.45 mm after 3 years, 35% of the implants lost at least 2 mm bone, and 22% more than 3 mm
- The ZiUnite™ implant was ~~never~~ marketed



Klein DJ, Speck RD, Kaur A, Kaur P. One-piece zirconia and titanium implant: Three-year results from a long-term prospective cohort study. *J Oral Maxillofac Surg*. 2010 Jan;12(1):111-121.



200 μ m
|-----|

EHT = 10.00 kV
WD = 15.0 mm

Signal A = SE2
Photo No. = 978

Date :15 Aug 2018
Time :13:17:00



200 μ m
|-----|

EHT = 10.00 kV
WD = 22.4 mm

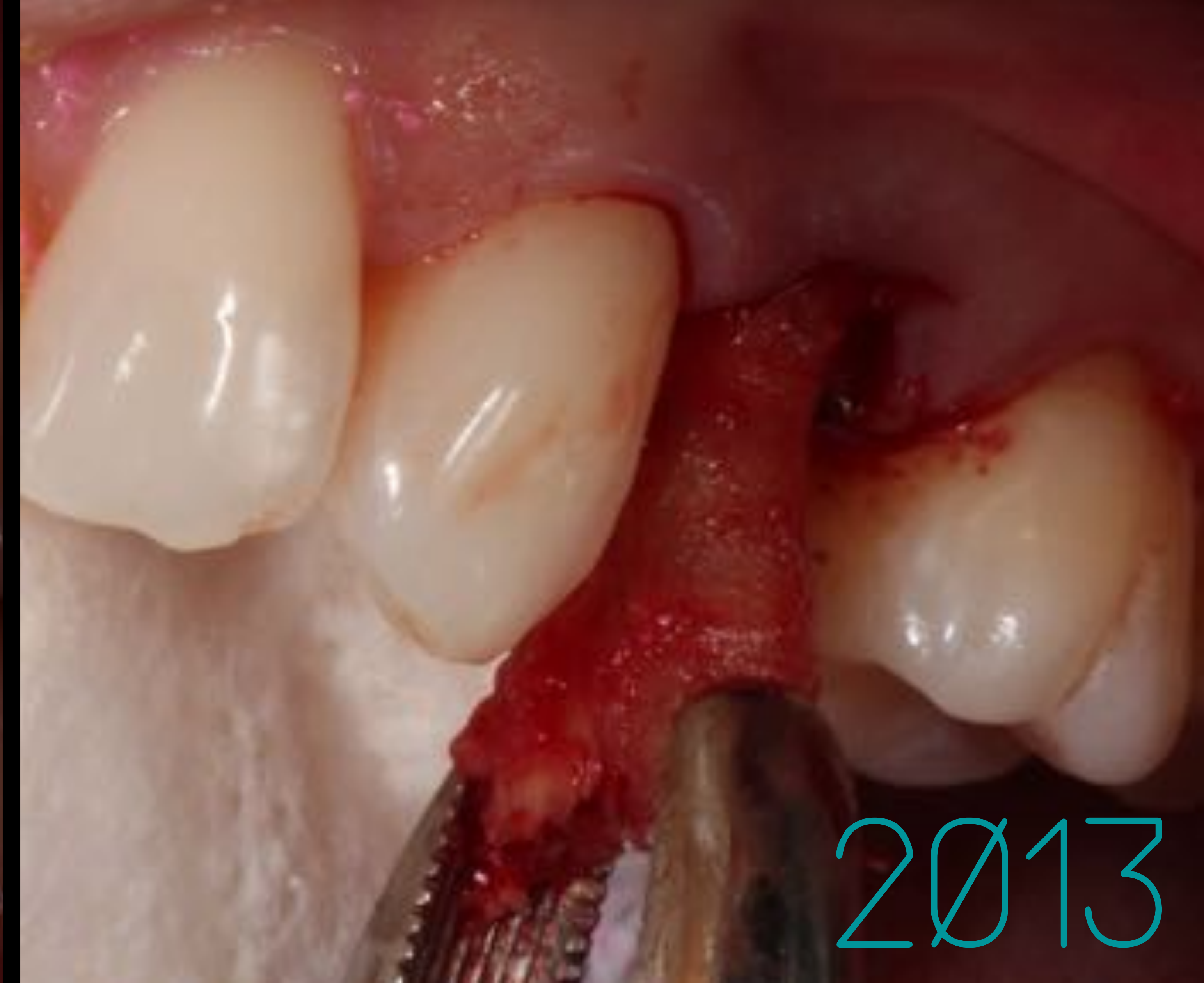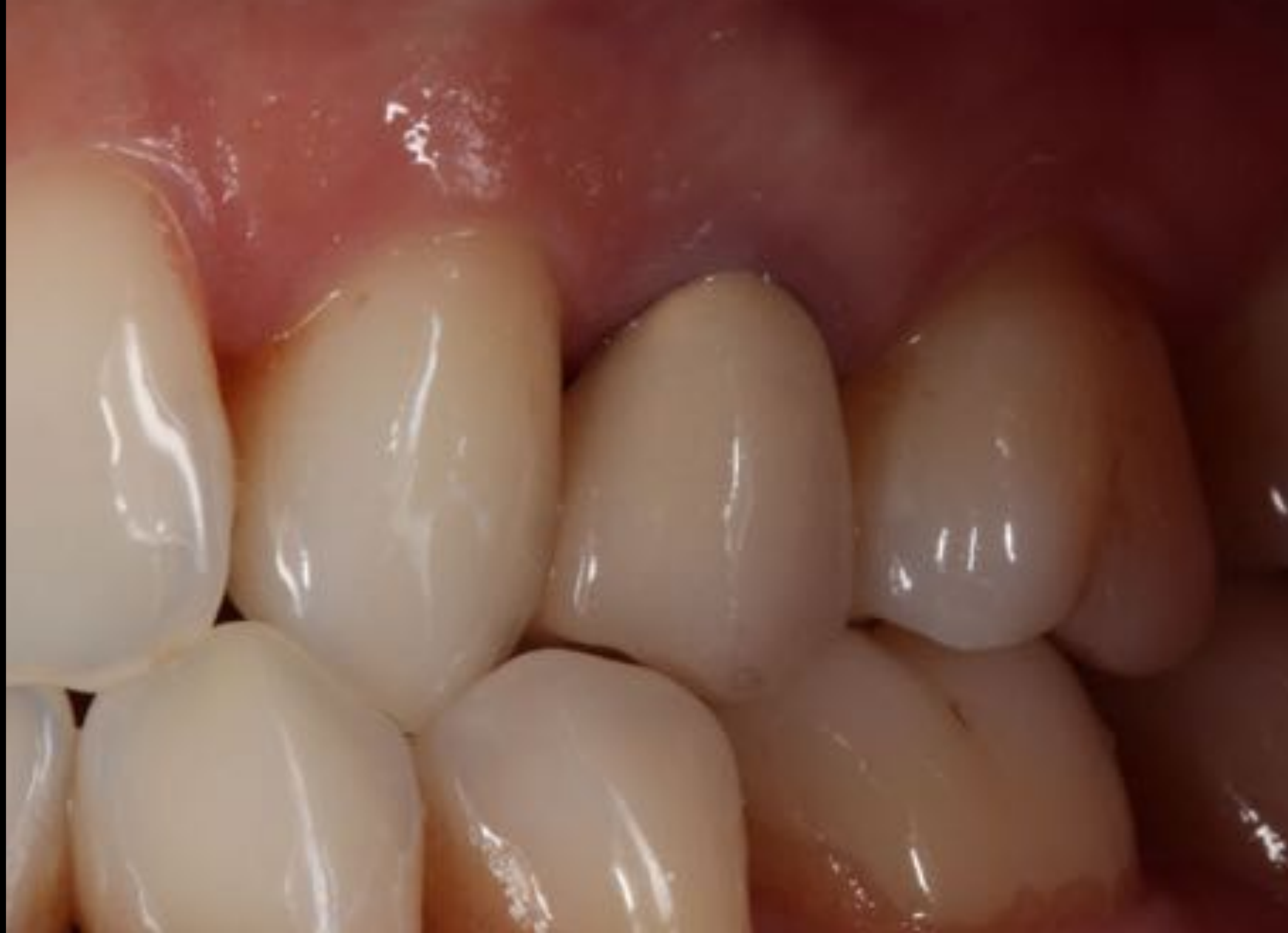Signal A = SE2
Photo No. = 1987

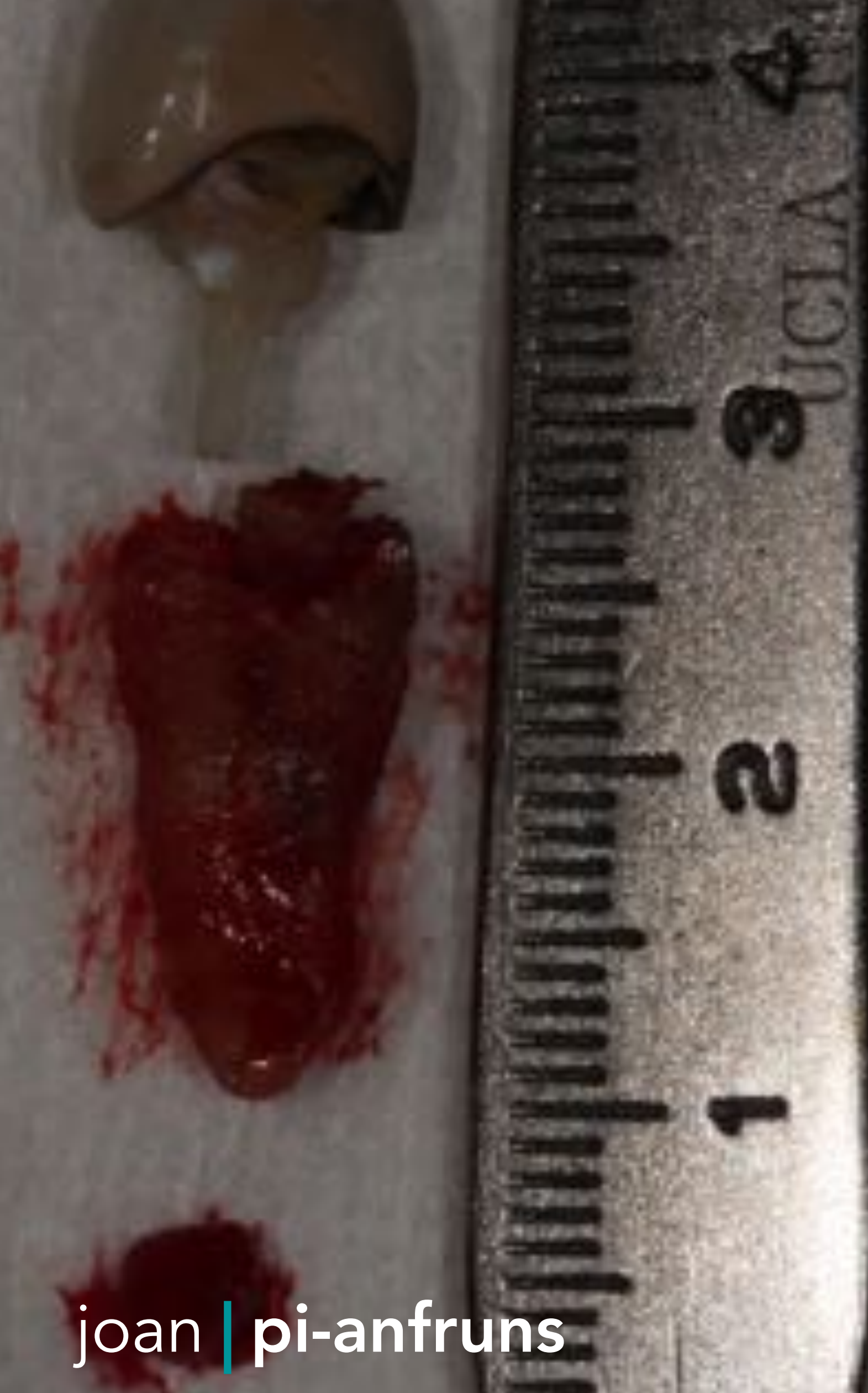
Date :28 Aug 2018
Time :19:57:38



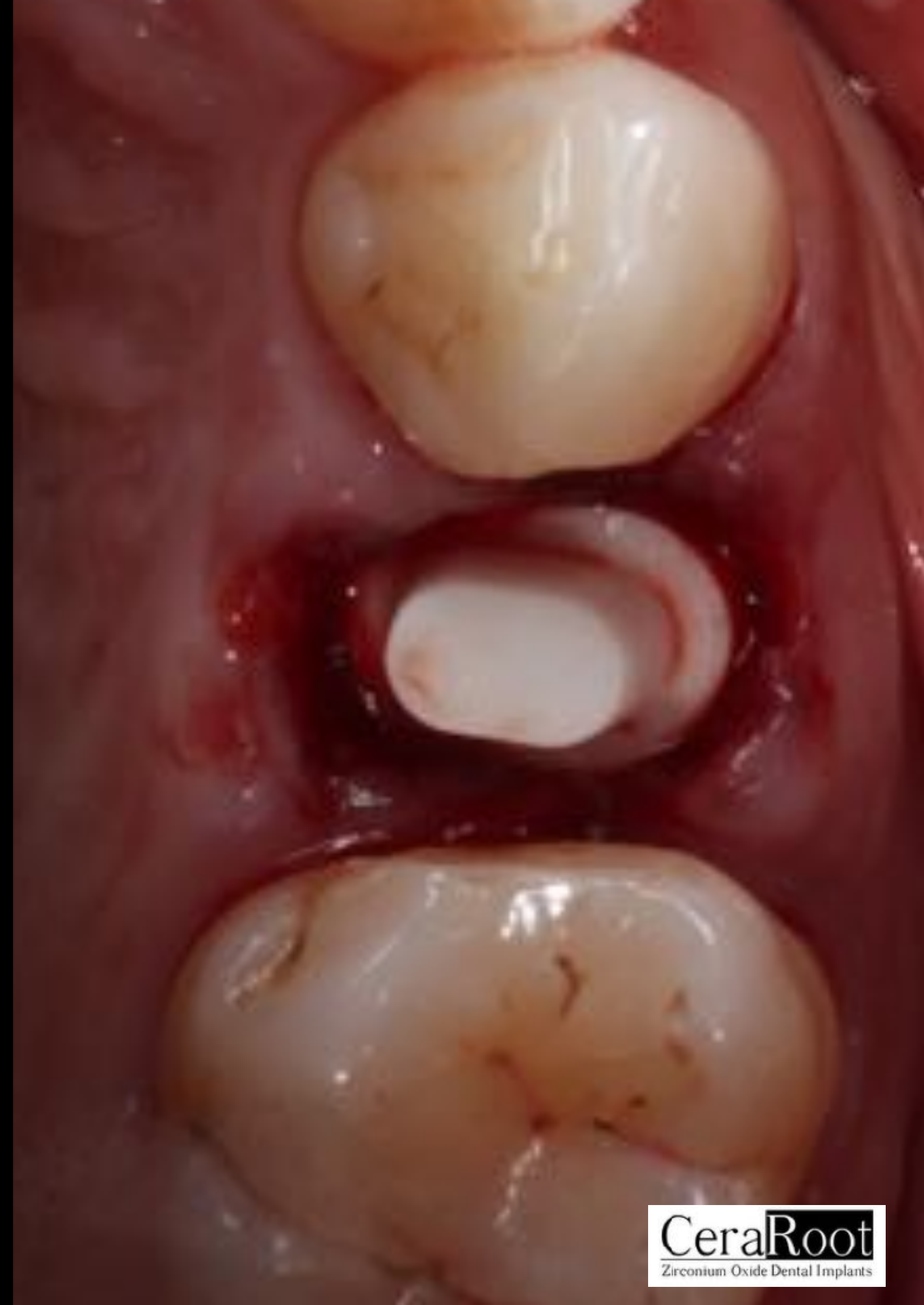
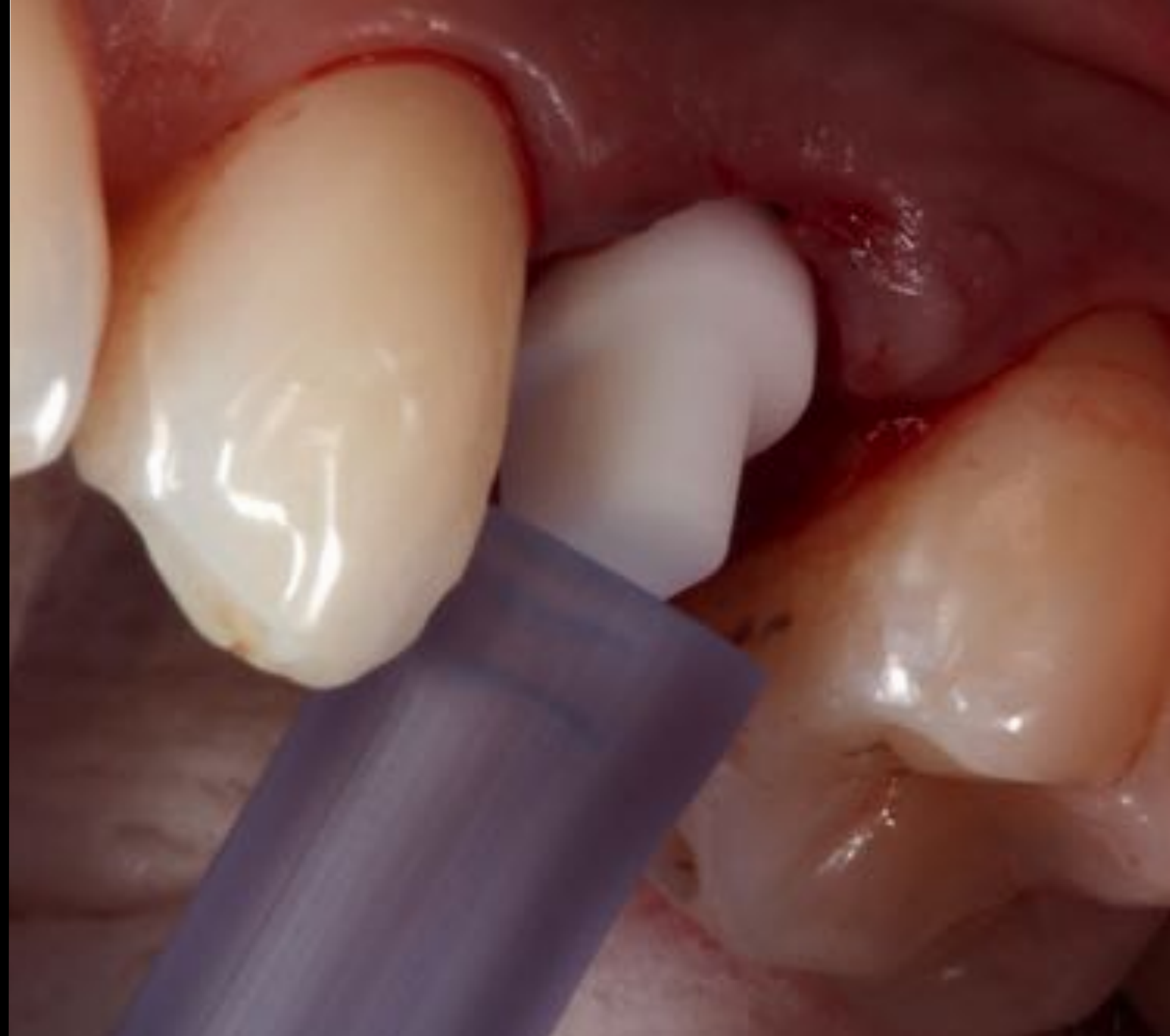
The **UCLA** experience

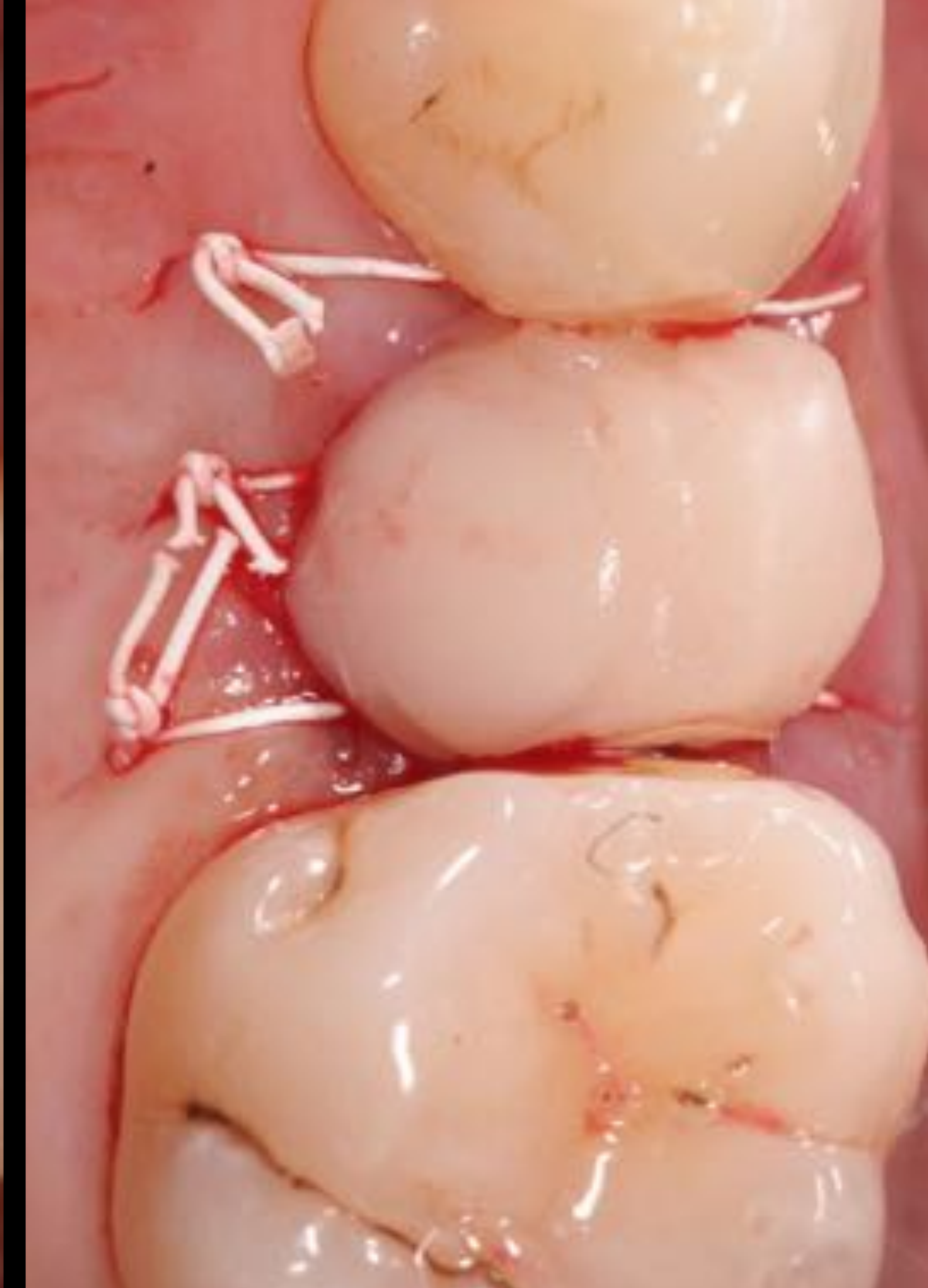
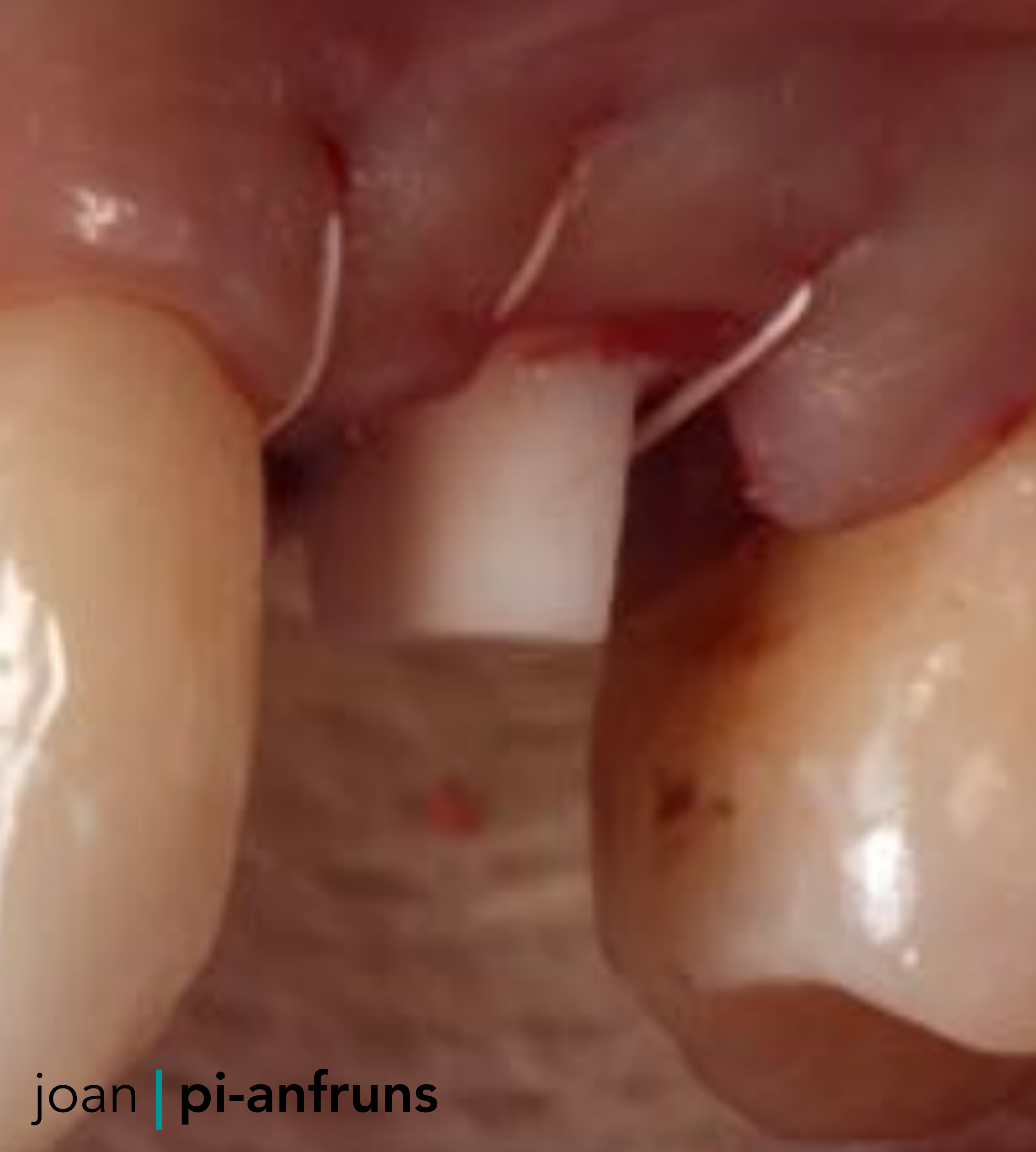


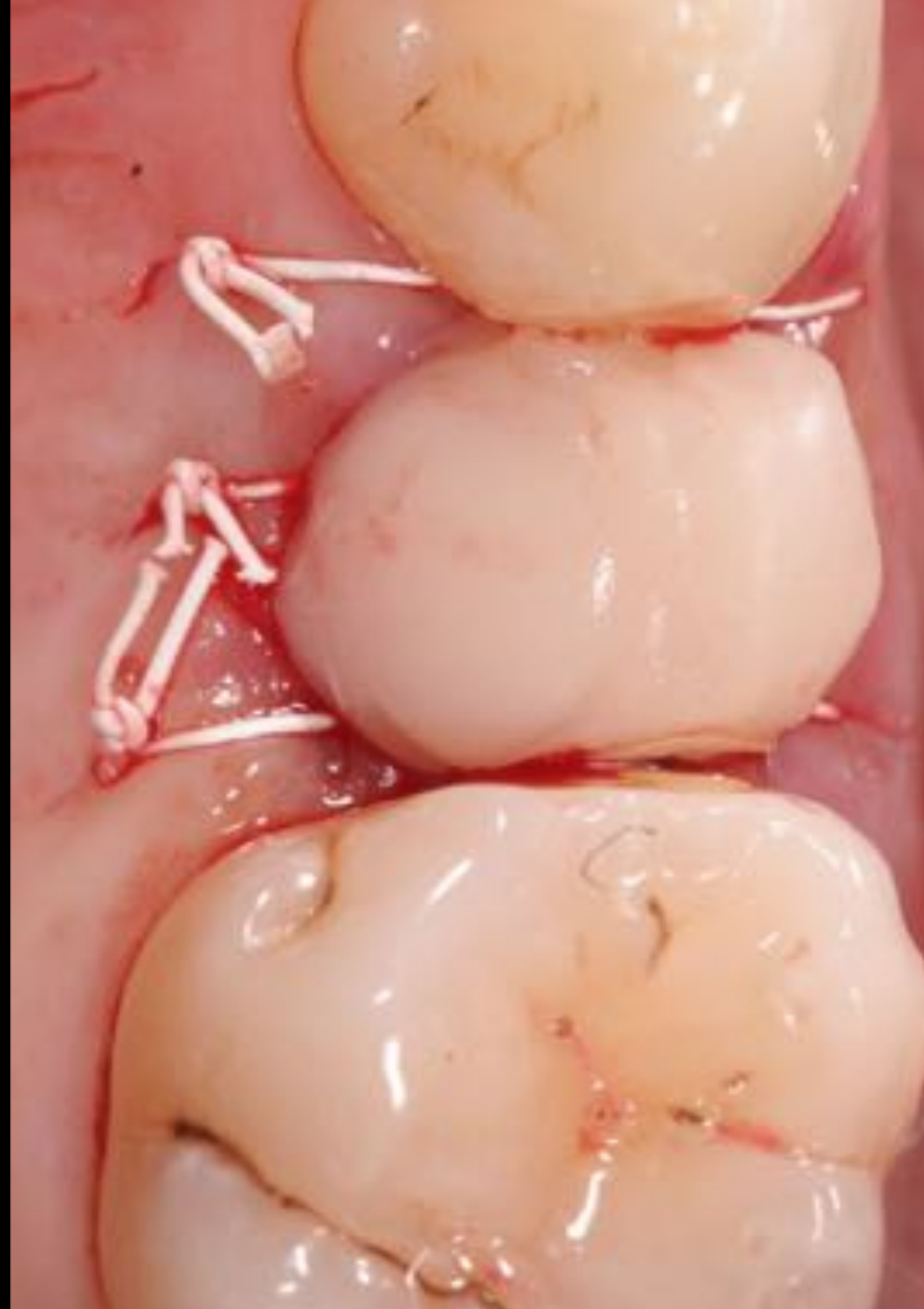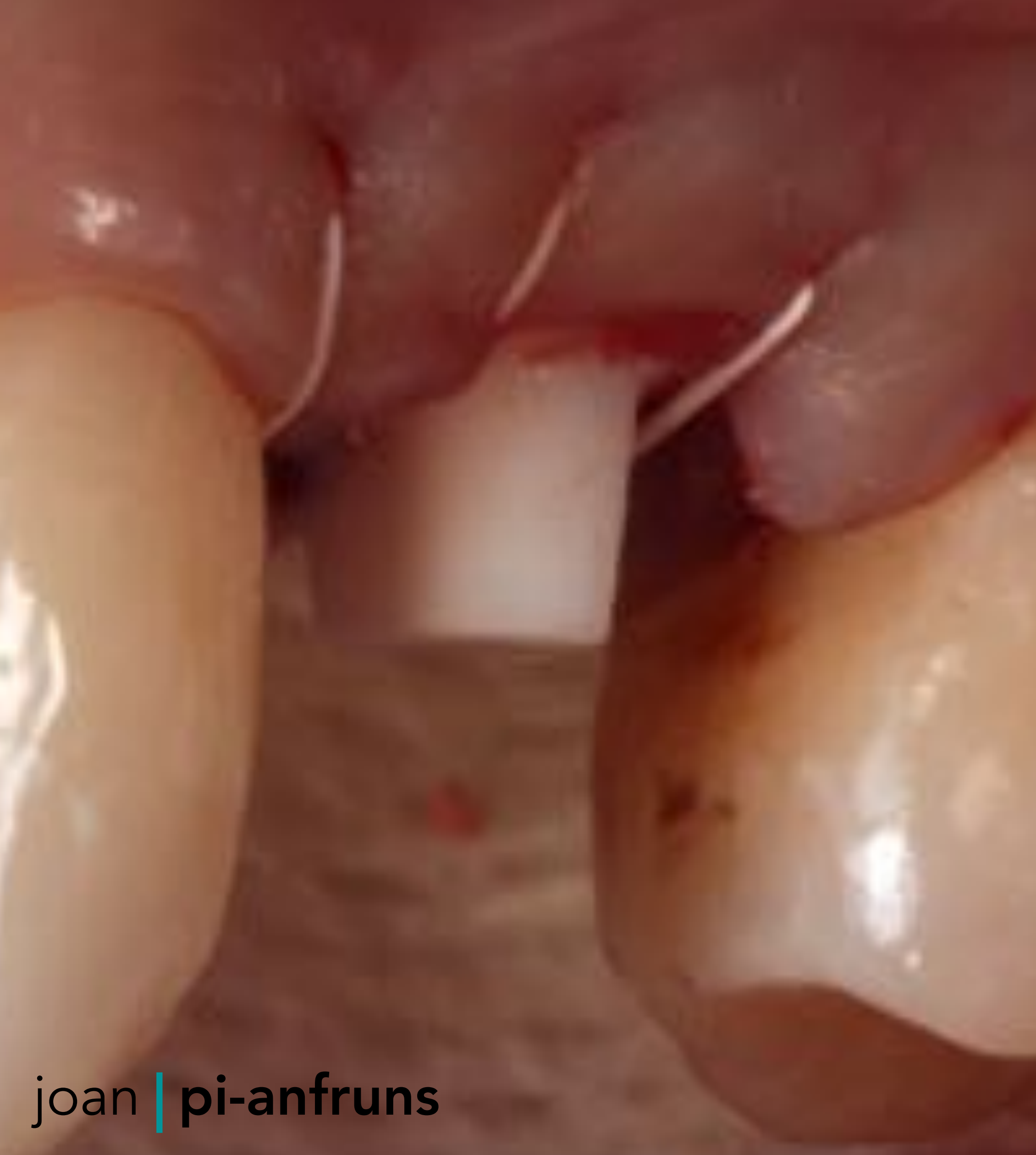joan | pi-anfruns

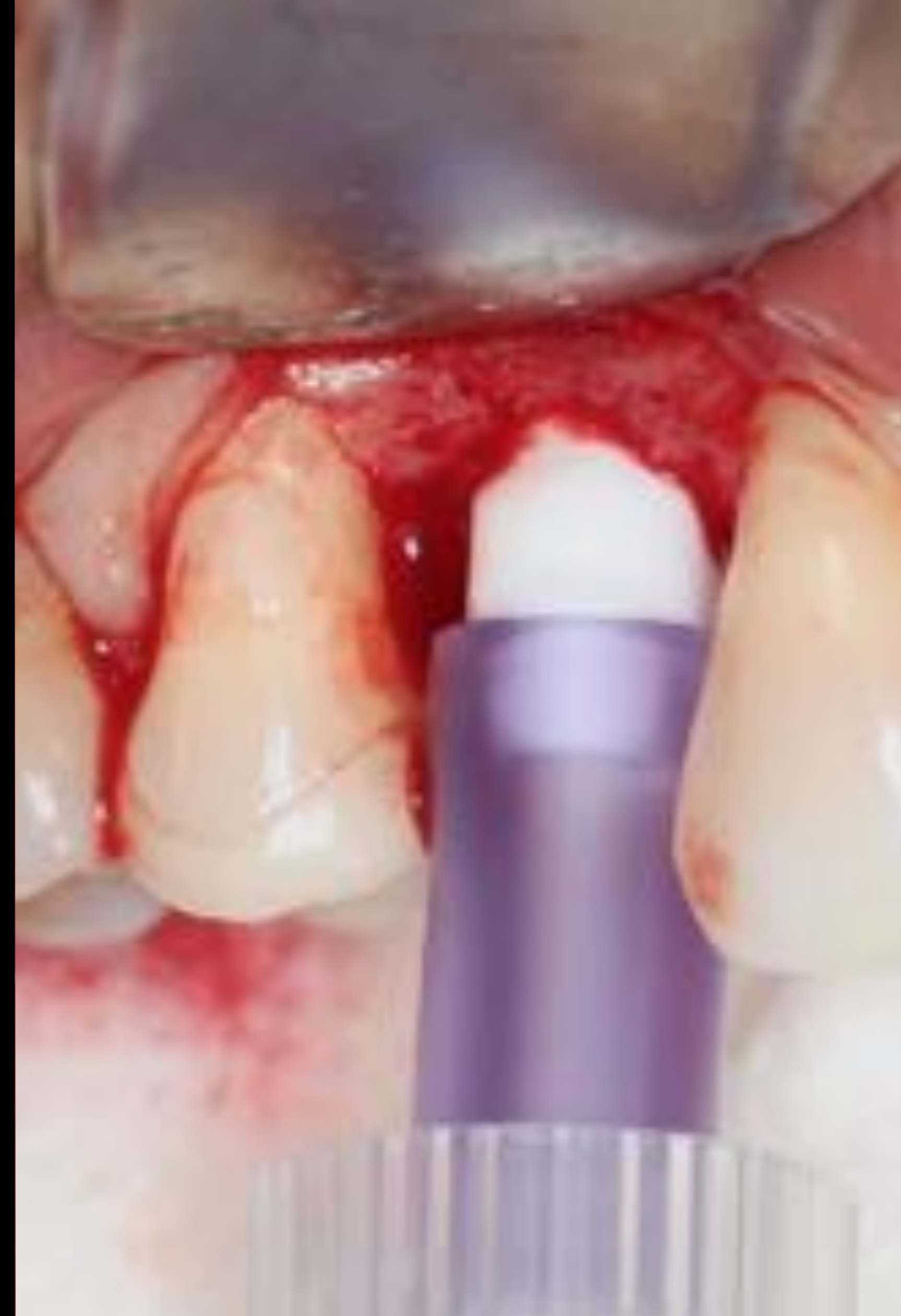
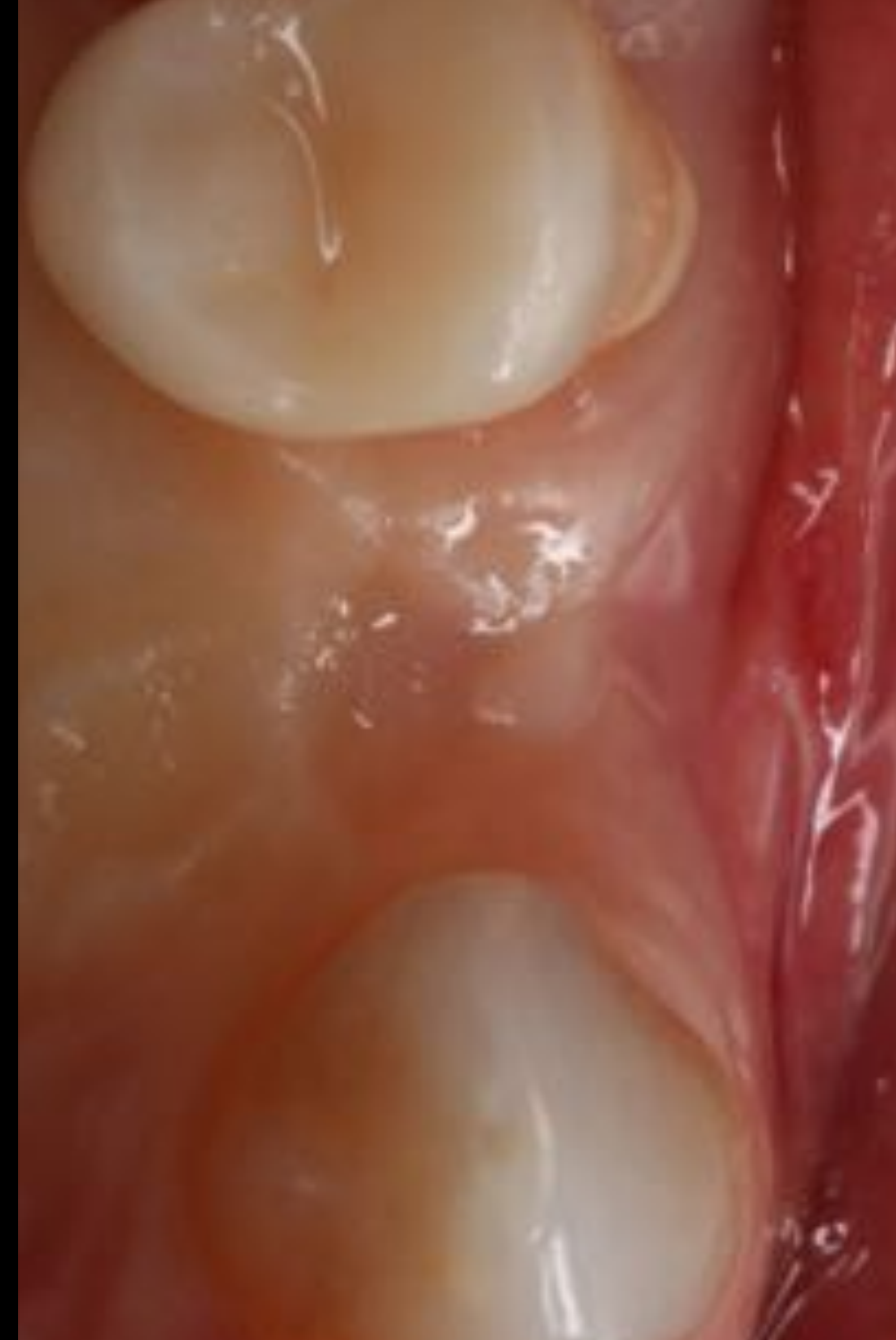
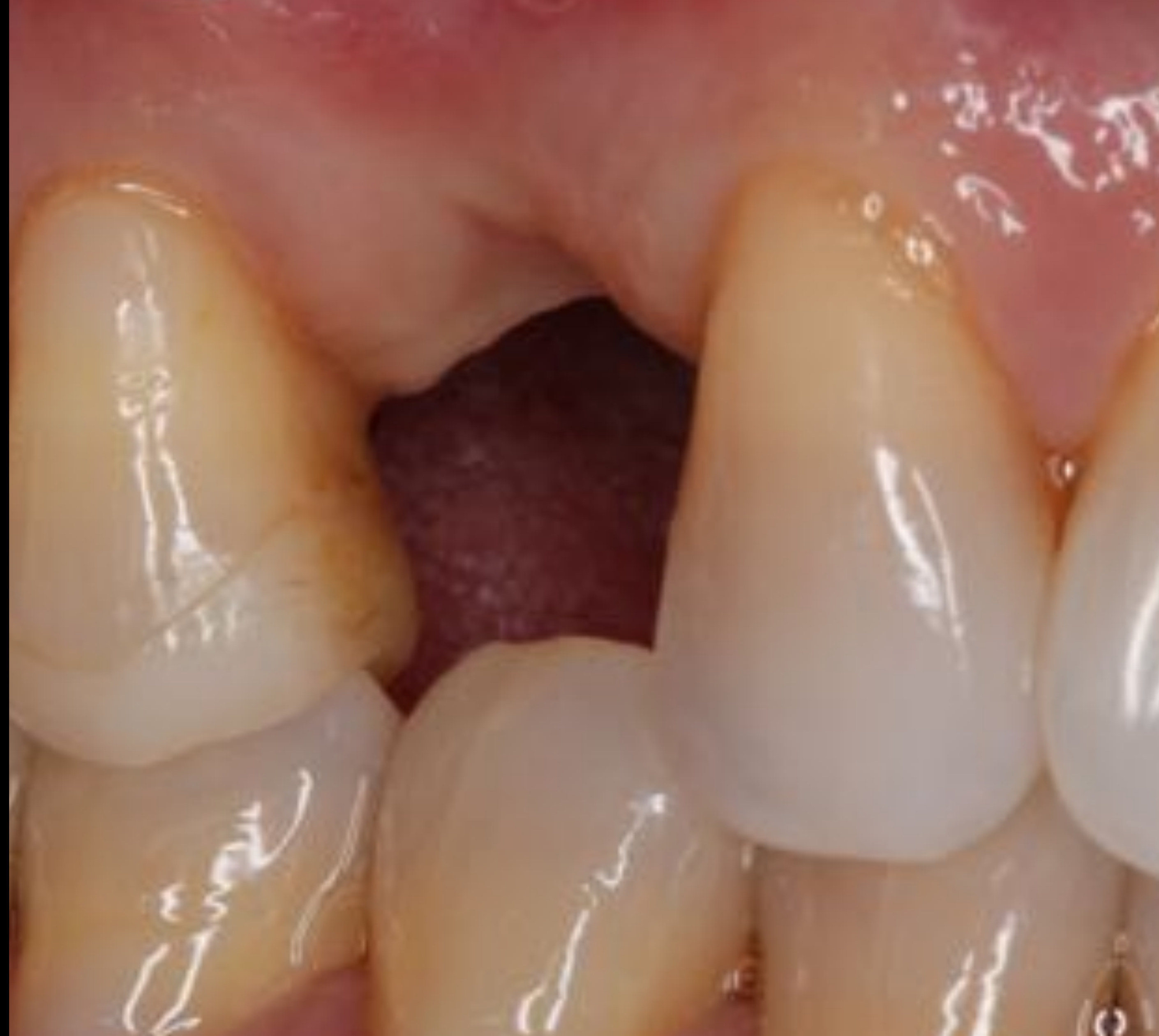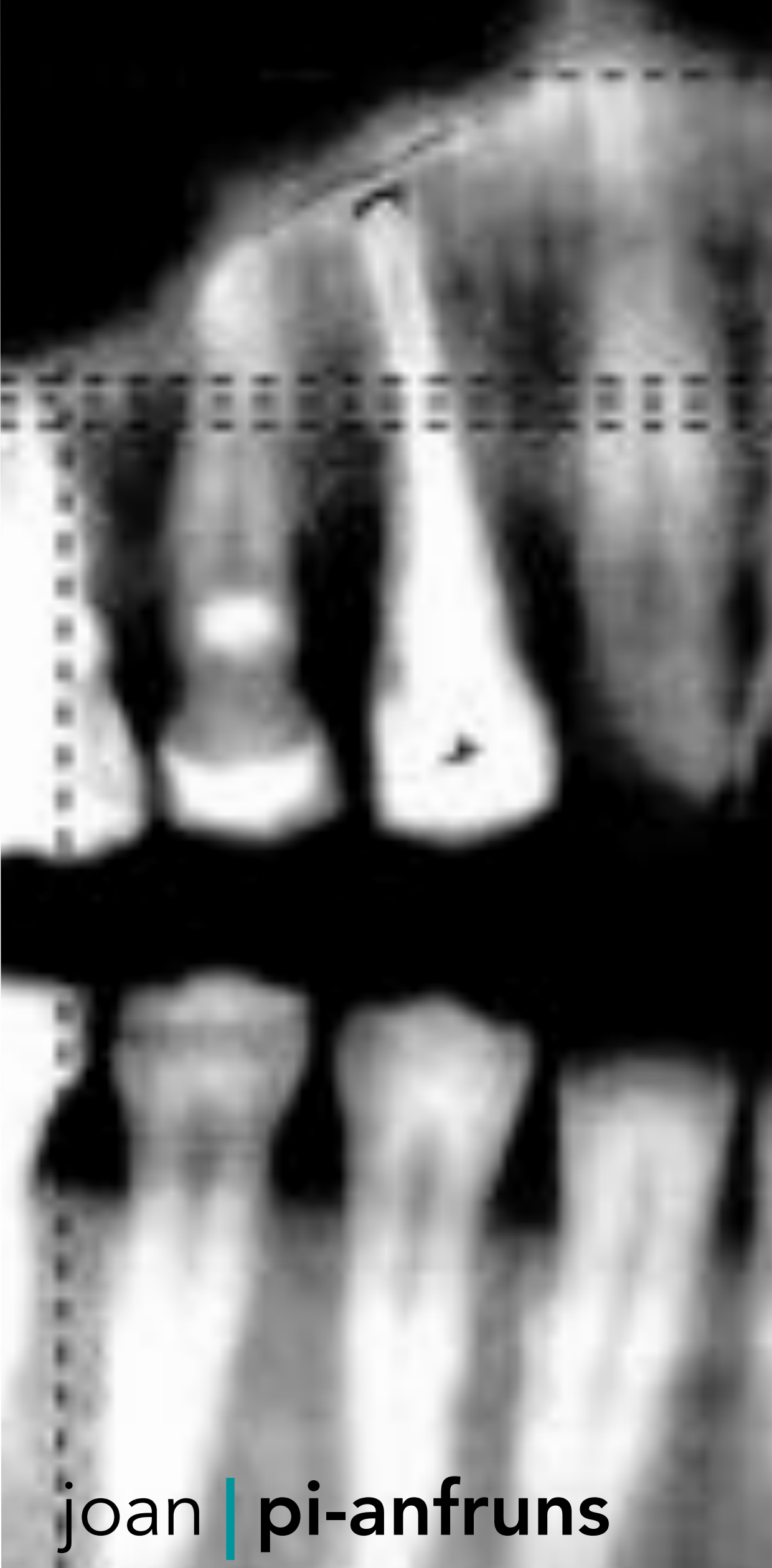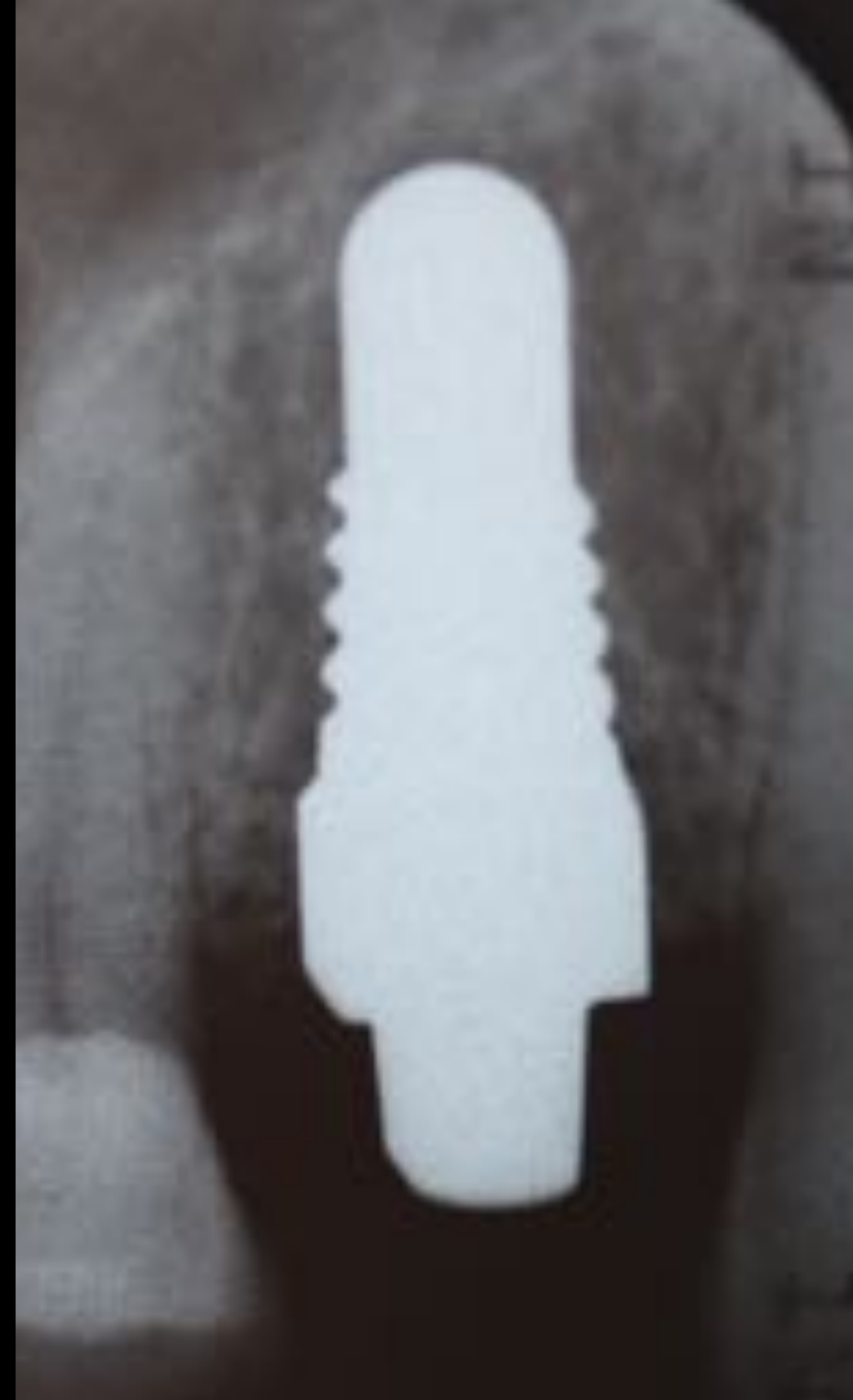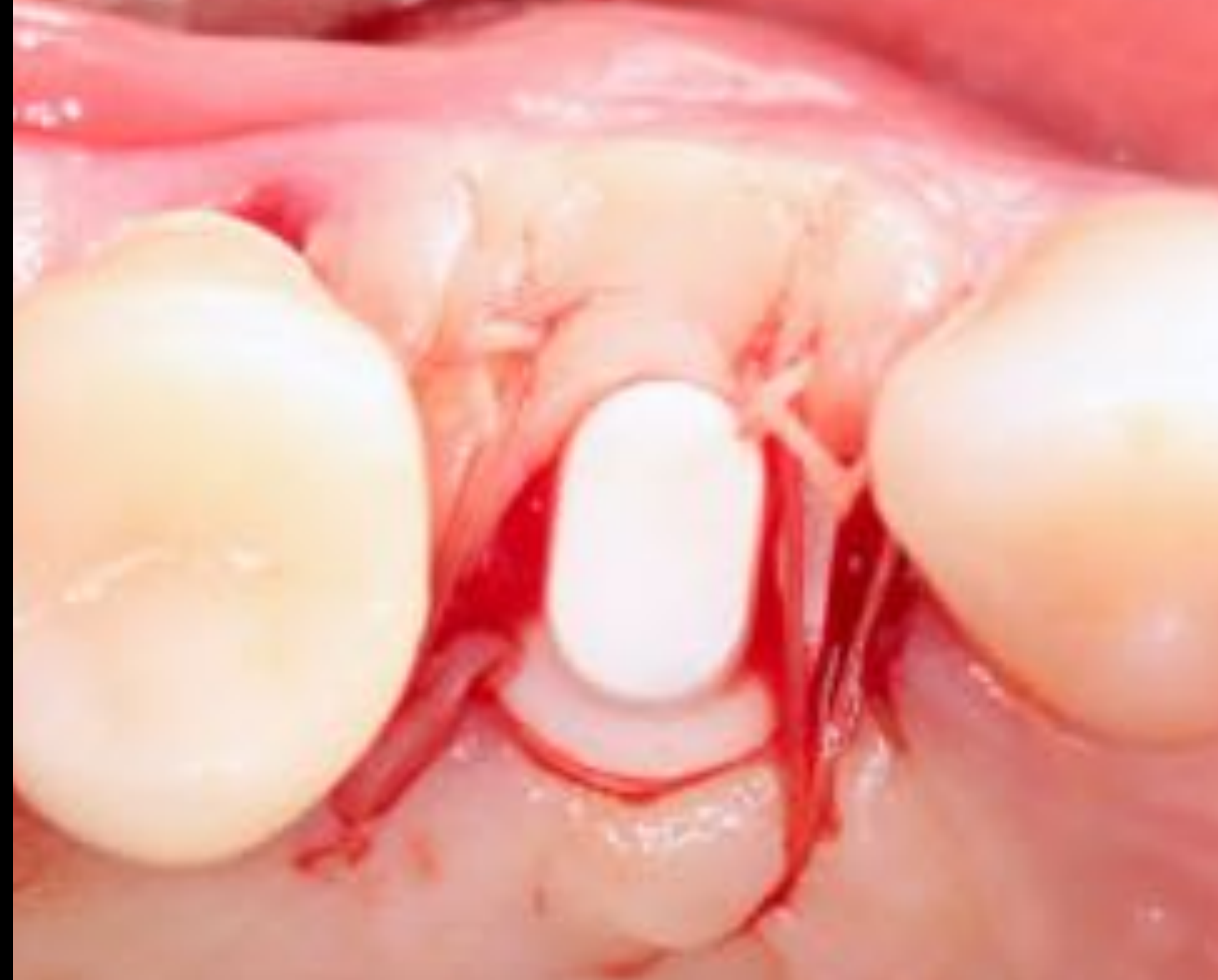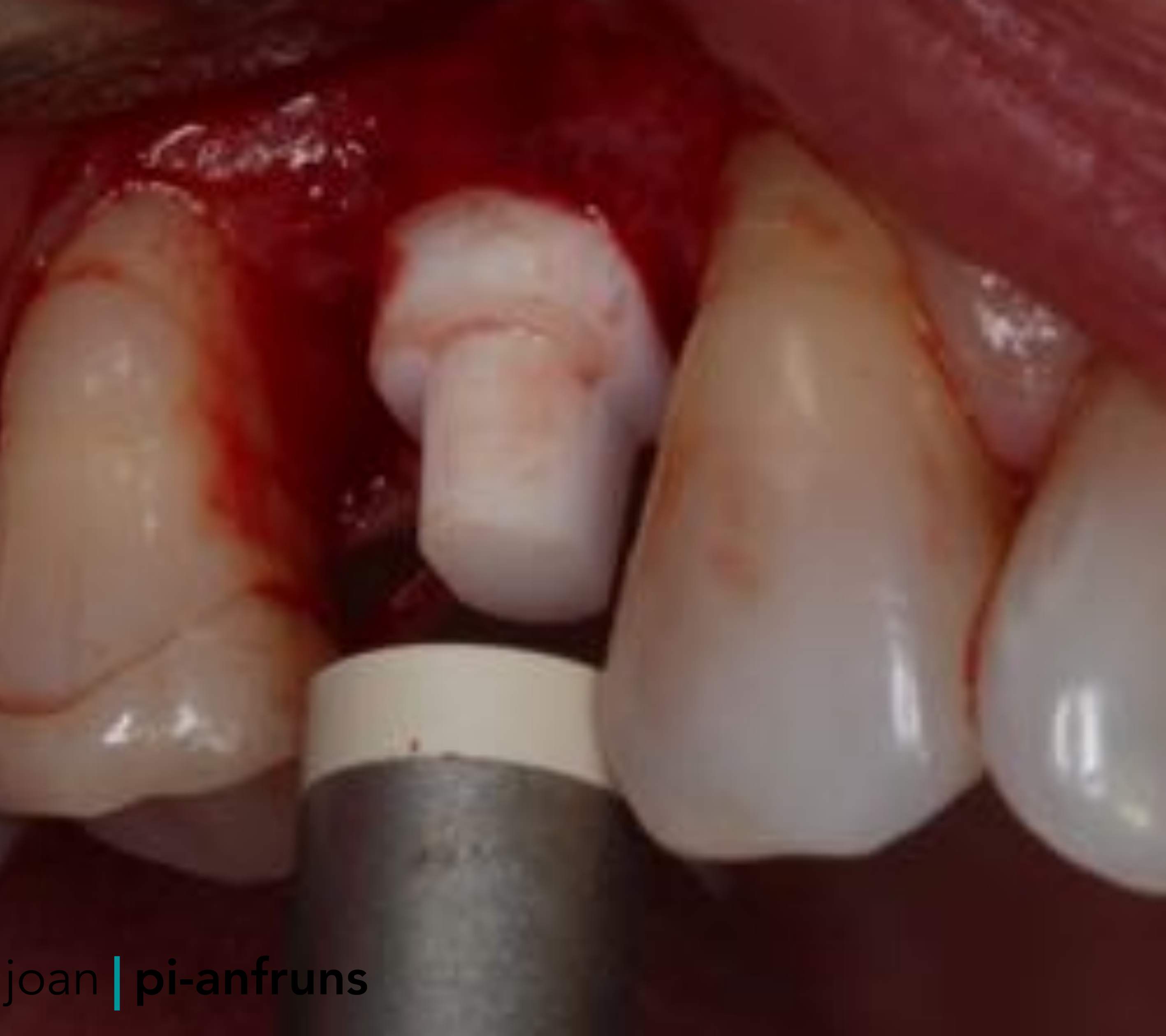CeraRoot
Zirconium Oxide Dental Implants





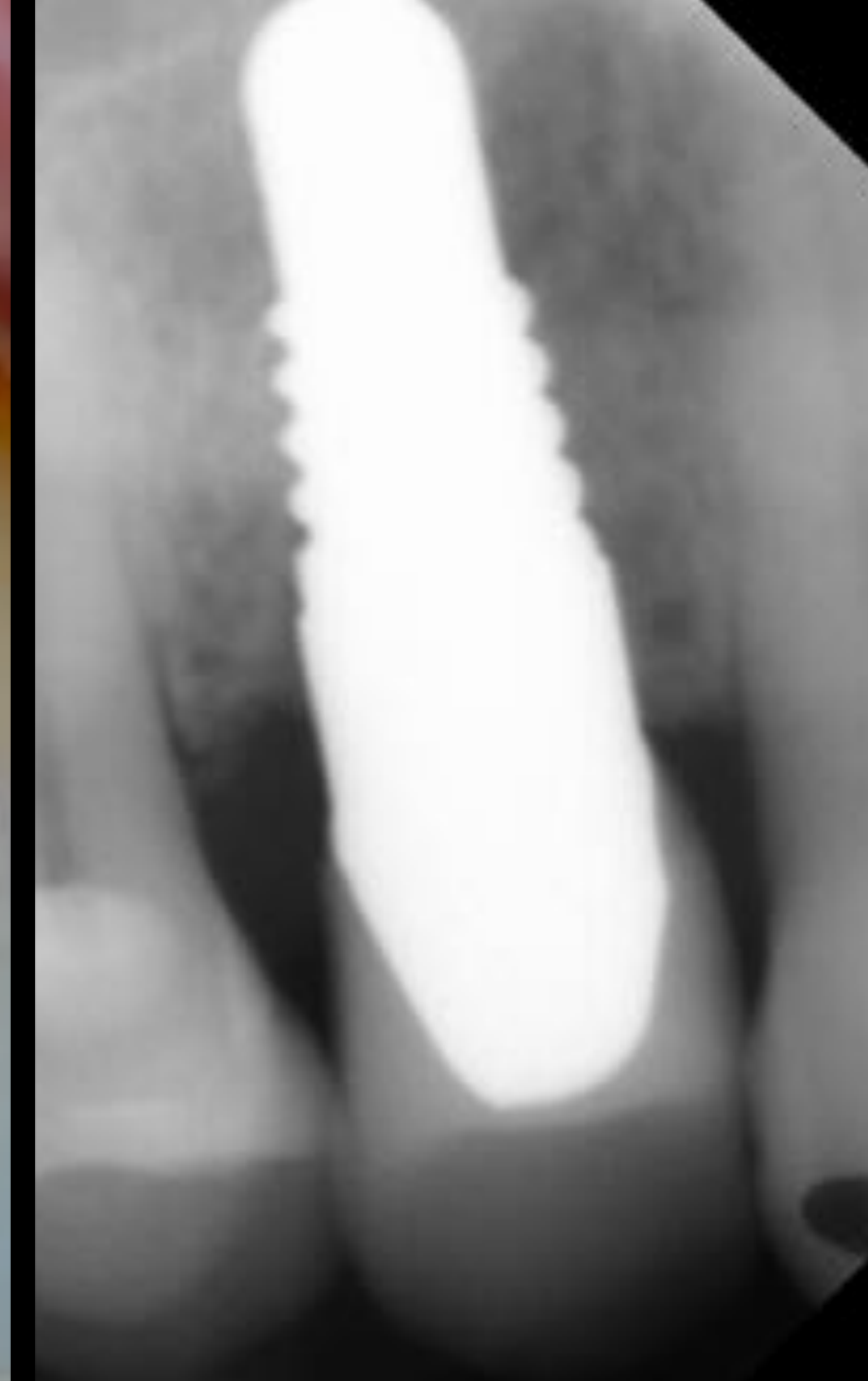
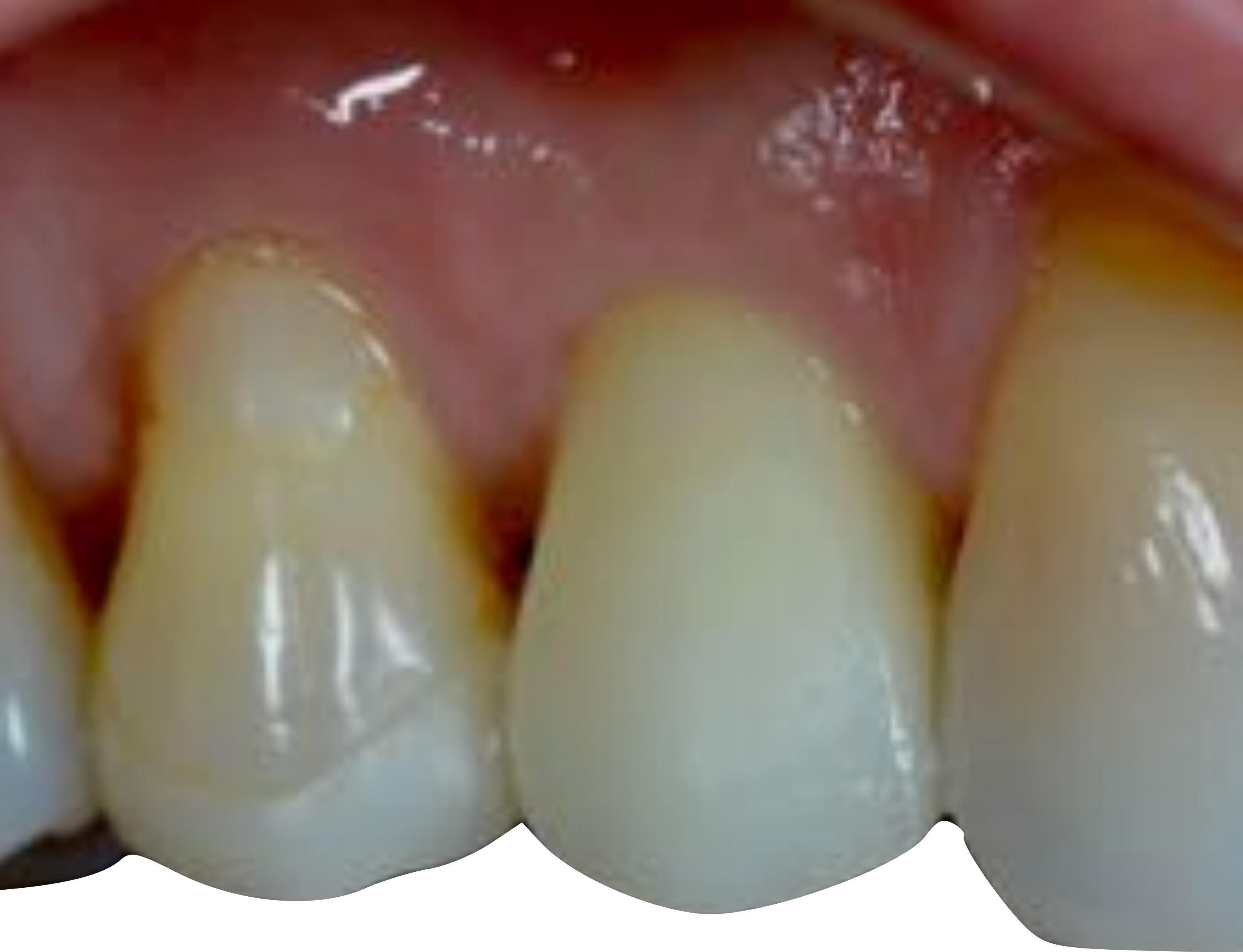





4 months





5 years

2

Ø

1

6



2

Ø



1

6



- Similar healing time (6-12 weeks) and healing pattern

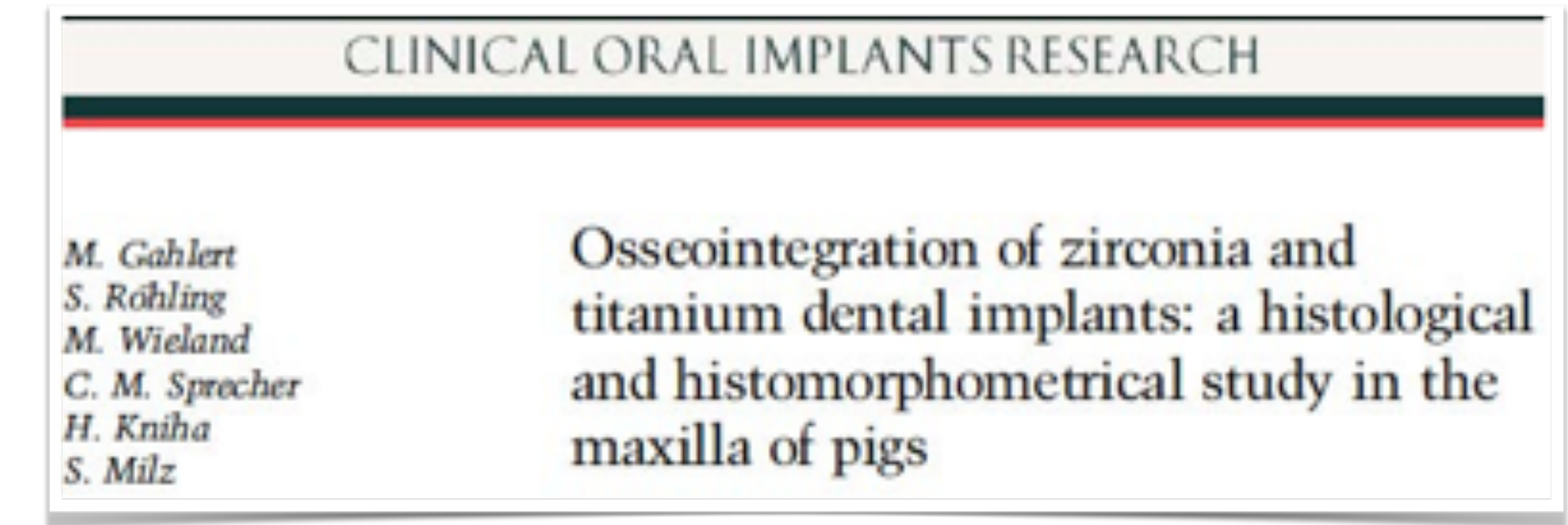
Z
L
A



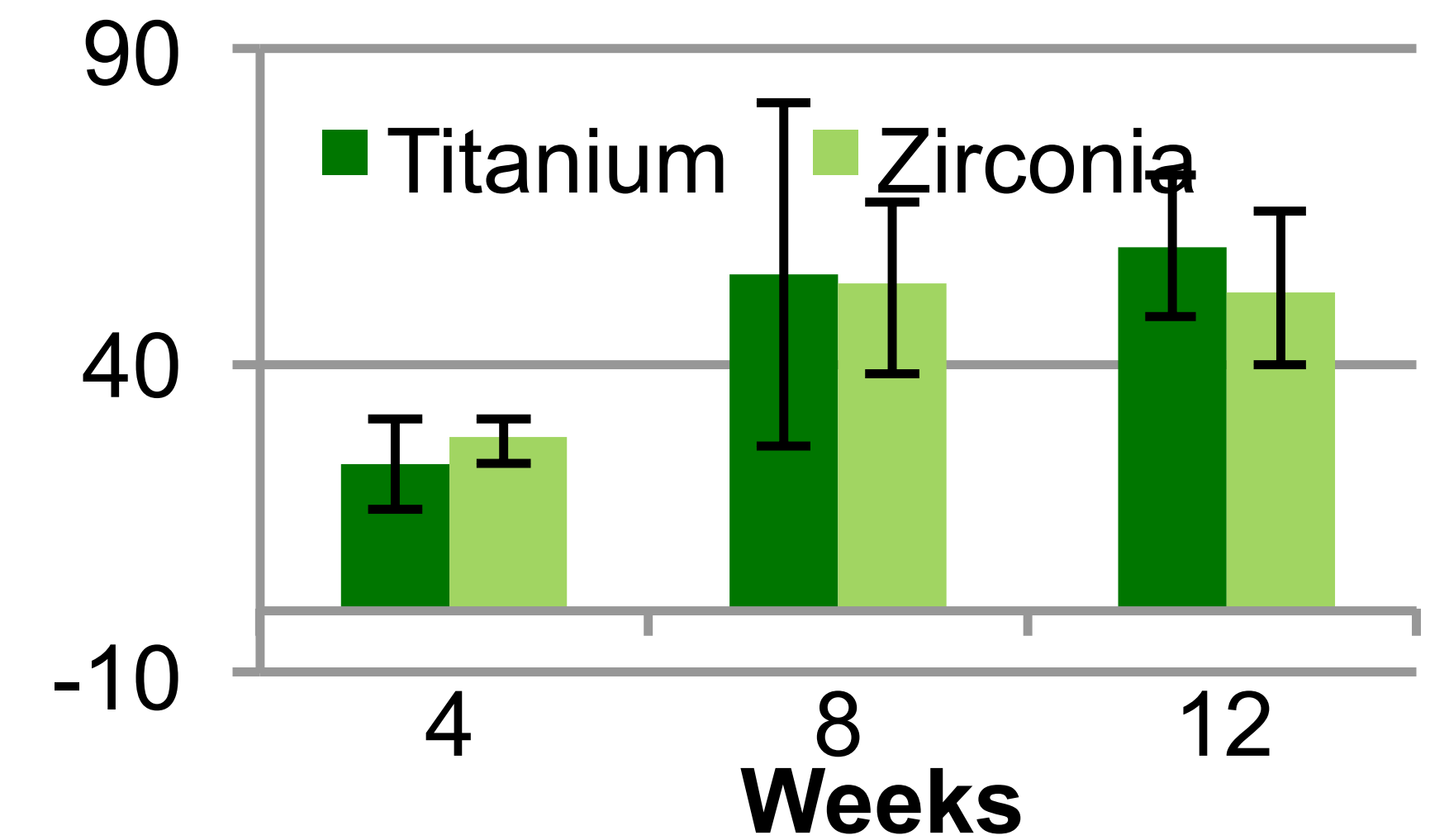
S
L
A

PRE CLINICAL STUDIES

- same **capacity for osseointegration** as Titanium implants
- at none of the time points was there any **statistically significant difference** from the control group



Gahlert M. et al. 2009



PRE CLINICAL STUDIES

- **better** soft tissue response
- **shallower** sulcus depth
- **increased** attached gingiva

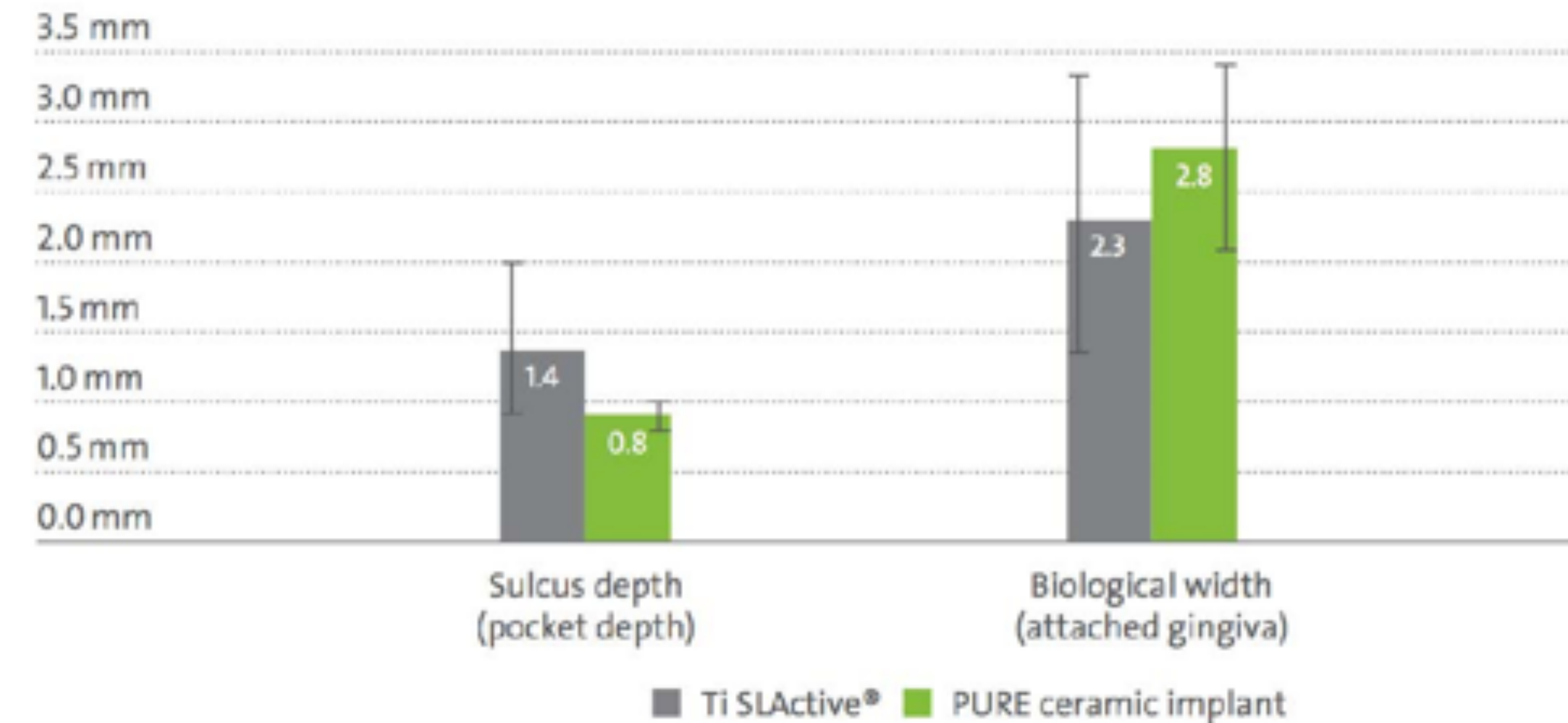
Histological assessment of hard and soft tissues surrounding a novel ceramic implant: a pilot study in the minipig

Antonio Liñares¹, Letizia Gil², Fernando Muñoz³, Benjamin Ewane Pöppinger⁴, Michel Dard⁵, Olivier Dardier⁶ and Juan Blanco-Cordero⁷

¹Periodontology Unit, School of Medicine and Dentistry, University of Zaragoza de Compostela, Santiago de Compostela, Spain; ²Oral, Maxillofacial and Pathology Institute, University of Basel, Basel, Switzerland; ³Department of Veterinary Clinical Sciences, University of Santiago de Compostela, Lugo, Spain; ⁴Department of Maxillofacial Surgery, University of Zurich, Zurich, Switzerland; ⁵Department of Periodontology and Implant Dentistry, College of Dentistry, New York University, New York, NY, USA; ⁶Department of Periodontology, University of Leuven, Leuven, Belgium

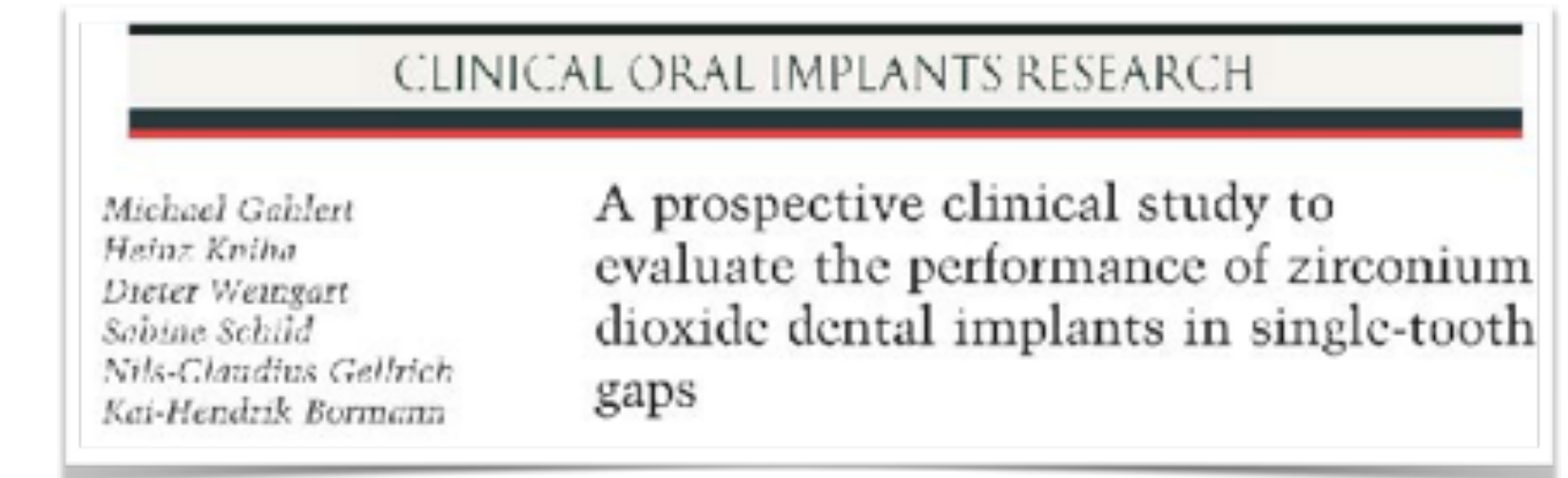
Liñares A, Gil L, Muñoz F, Pöppinger B, Dard M, Dardier O, Blanco-Cordero J. Histological assessment of hard and soft tissue surrounding a novel ceramic implant: a pilot study in the minipig. *J Clin Periodontol* 2016; 43: 1239-1246. doi: 10.1111/jcpe.12347.

Liñares A. et al. 2016

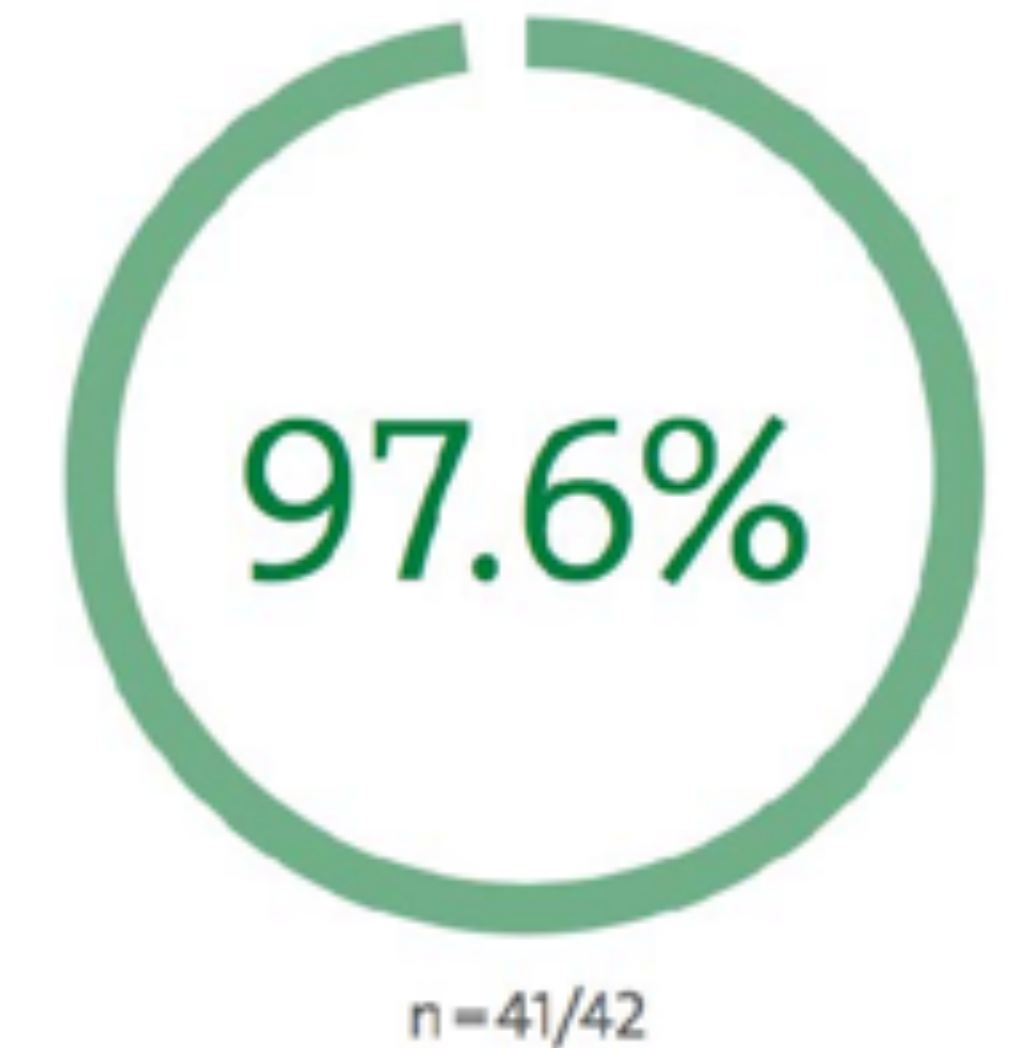

PROSPECTIVE CLINICAL STUDY

- only 1 implant was lost, leading to an implant success and survival rate of 97.6%.
- **no fractures** were observed with the Straumann® PURE Ceramic Implant
- stable marginal bone levels were observed.



Gahlert M. et al. 2015



3 year FOLLOW UP STUDY

Papilla-Crown Height Dimensions around Zirconium Dioxide Implants in the Esthetic Area: A 3-Year Follow-Up Study

Kim Kniha, DMD,¹ Karl Andreas Schlegel, MD, DDS, PhD,¹ Heinz Kniha, MD, DDS, PhD,² Ali Modabber, MD, DDS, PhD,³ Friedrich Neukam, MD, DDS, PhD,¹ & Kristian Kniha, DMD

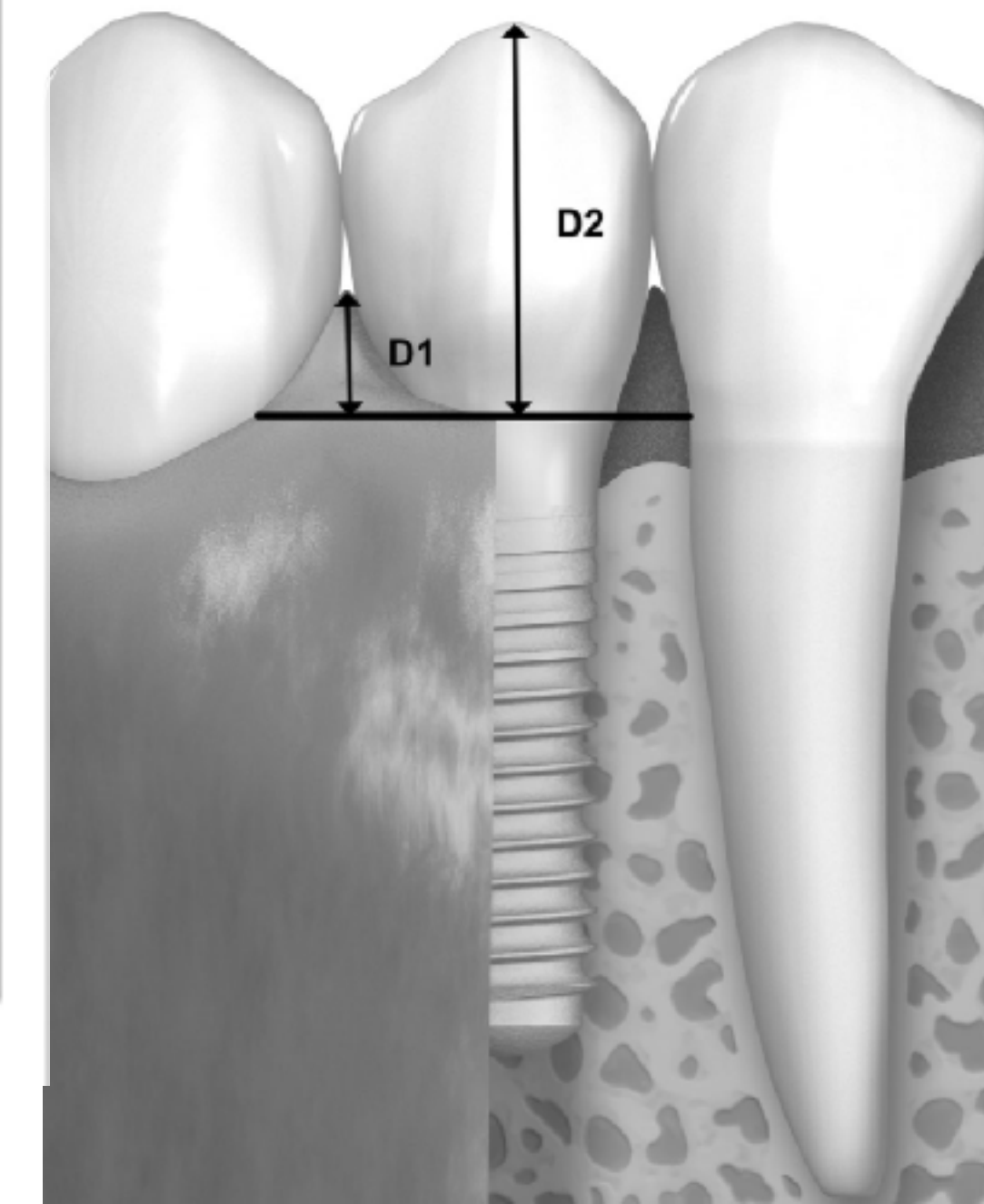
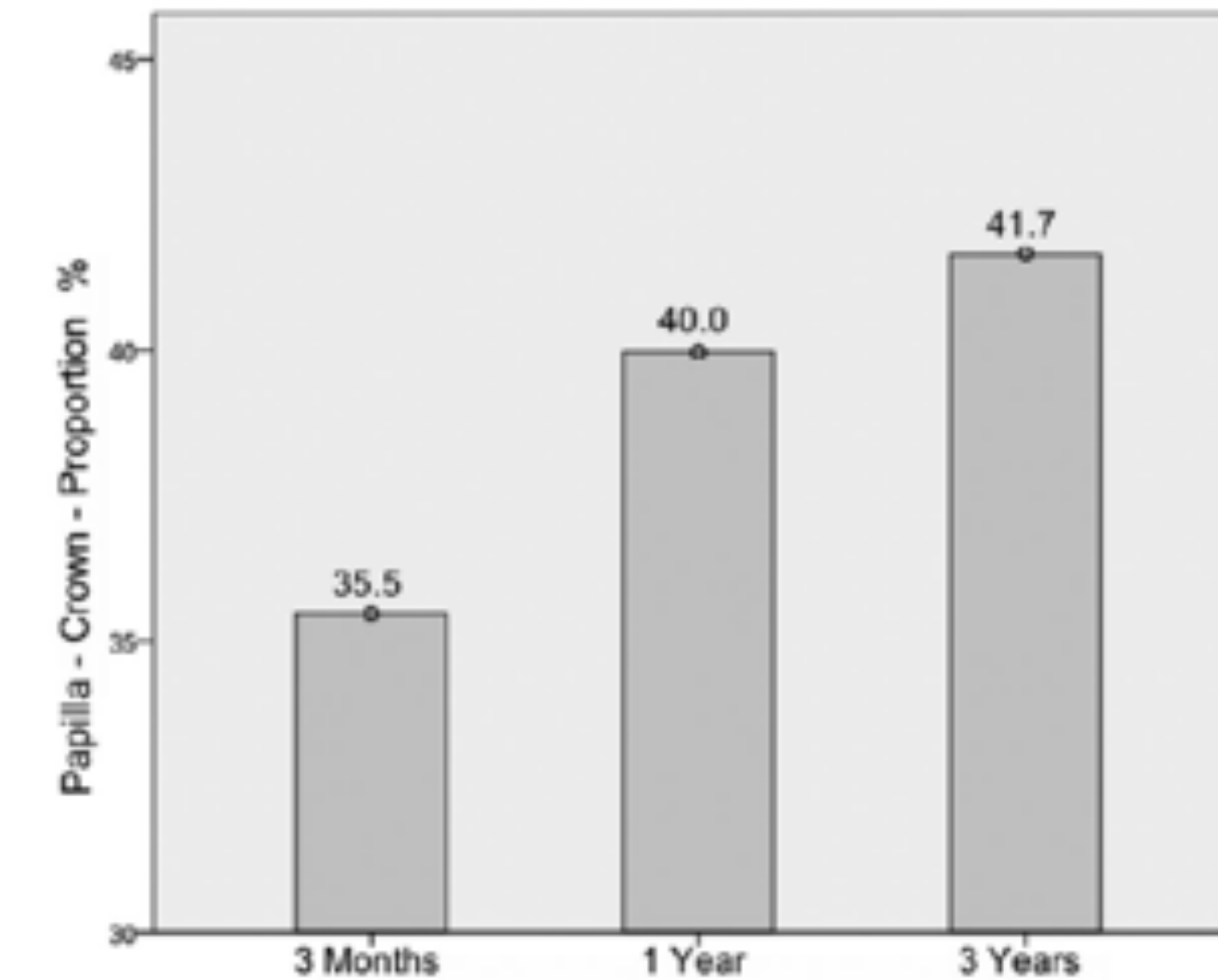
¹Department of Oral and Cranio-Maxillofacial Surgery, Friedrich-Alexander-University Erlangen-Nürnberg (FAU), Germany

²Private Dental Clinic, Drs. Kniha and Gehert, Munich, Germany

³Department of Oral and Cranio-Maxillofacial Surgery, University Hospital Aachen, Germany

Kniha K et al. 2018

- papilla-crown proportion **improved** from 35.5% after 3 months to 41.7% after 3 years
- papilla-crown proportion of **40%** was observed after 3 years
- no correlation between **thin/thick** biotype



Bone response to functionally loaded, two-piece zirconia implants: A preclinical histometric study

Simone F. M. Janner^{1,2} | Michael Gahlert^{3,4} | Dieter D. Bosshardt⁵ | Stefan Roehling^{1,3} | Stefan Milz⁶ | Frank Higginbottom⁷ | Daniel Buser² | David L. Cochran¹

¹Department of Periodontics, University of Texas Health Science Center at San Antonio, San Antonio, TX, USA

²Department of Oral Surgery and Stomatology, School of Dental Medicine, University of Bern, Bern, Switzerland

³Clinic for Oral and Cranio-Maxillofacial Surgery, HighTech Research Center, University Hospital Basel, University of Basel, Basel, Switzerland

⁴Private Practice, Munich, Germany

⁵Robert K. Schenk Laboratory of Oral Histology, School of Dental Medicine, University of Bern, Bern, Switzerland

⁶Anatomische Anstalt, Ludwig-Maximilians-University, Munich, Germany

⁷Private Practice, Dallas, TX, USA

Correspondence

Simone F. M. Janner, Department of Oral Surgery and Stomatology, Bern, Switzerland. Email: simone.janner@zmk.unibe.ch

Funding information

This study was funded with a research grant from the International Team for Implantology, Basel, Switzerland (ITI Grant No. 858_2012). The study materials were kindly provided by Institut Straumann AG. D. L. Cochran lectures and consults for Institut Straumann AG and has received previous research funding from Institut Straumann AG.

Abstract

Objective: To evaluate the bone response to a two-piece zirconia implant with a control titanium implant in the canine mandible 4 and 16 weeks after restoration.

Material and Methods: Zirconia and titanium implants were alternately placed in healed mandibular molar and premolar sites of five canines. Full-arch tooth restorations were cemented after 6 weeks of transmaxillary healing, followed by full functional loading of the implants. Histologic and histometric analyses were performed on orofacial and mesiodistal undecalcified sections of the specimens upon sacrifice after 4 and 16 weeks of functional loading. Bone-to-implant contact (BIC), multinucleated giant cells-to-implant contact (MIC), crestal bone level (CBL), and peri-implant bone density were histometrically assessed.

Results: All 60 implants and 60 restorations were still in function after 4 and 16 weeks of loading in both test and control groups. No implant loss, no implant fracture, and no chipping of the restorations could be detected. Histometric analyses showed no statistically significant differences between zirconia and titanium implants in BIC, crestal bone level, and peri-implant bone density at both time points. At 4 and 16 weeks, the crestal bone level around zirconia implants showed a statistically significant increase in its distance from the implant shoulder. No significant differences were found between zirconia and titanium implants in crestal bone level on both implant types and both time points and decreased significantly overtime.

Conclusion: The present two-piece zirconia implant showed a similar bone response compared to the titanium implant with similar surface morphology after 4 and 16 weeks of loading.

KEYWORDS

acid-etch, dental aesthetics, crestal bone, dental implants, dog, histomorphometric, osseointegration, zirconia implant



Dimensions of hard and soft tissue around adjacent compared with single-tooth, zirconia implants

K. Kniha^{a,*}, A. Modabber^a, H. Kniha^b, S.C. Möhlhenrich^c, F. Hölzle^d

^a Department of Oral and Cranio-Maxillofacial Surgery, University Hospital Aachen, Pauwelsstraße 30, Aachen 52074, Germany

^b Private Dental Clinic Drs Kniha and Gahlert, Theatinerstraße 1, Munich 80333, Germany

^c Department of Orthodontics, University Hospital Aachen, Pauwelsstraße 30, 52074, Germany

^d Department of Anatomy Munich, Ludwig-Maximilians-University Munich, Pettenkoferstr. 11, 80336, Germany

Accepted 10 November 2017

Available online 24 November 2017

Abstract

Preservation or regeneration of the papilla has always been a challenge around consecutive implants. In many studies, many studies have evaluated the papilla's behaviour and patterns based on surgical technique and pre-implantation. However, its behaviour around zirconia implants is scarce. The aim of this study was to evaluate papilla behaviour around zirconia implants (tooth-implant group) and between consecutive implants (implant-implant group). Ninety patients with 122 zirconia implants (Straumann PURE Ceramic Implant) were examined at the one-year follow-up. We measured the effect of the distance: first, the distance from the base of the crowns to the contact with bone at the implant site (D1); secondly, to the contact with the bone at the adjacent tooth site (D2); and thirdly on the papillary deficit (D3). In both the tooth-implant group and the implant-implant group, D1 was significantly associated with the papillary deficit (D3), whereas D2 was the major determinant factor (Spearman's ρ = 0.48). We conclude that the ideal distance from the base of the contact point to the bone contact at the adjacent tooth in both groups is <6 mm. The height of the bone on the teeth was significantly greater than that of the papilla.

© 2017 The British Association of Oral and Maxillofacial Surgeons. Published by Elsevier Ltd. All rights reserved.

K. Kniha^a, K. A. Modabber^a,
^aDepartment of O
 Surgery, Friedrich
 Erlangen-Nürnberg
^bPrivate Dental Cl
 Munich, Germany
 Cranio-Maxillofac
 Hospital Aachen, G

Abstract

Key words: dental implants; aesthetics; gingiva; papilla; zirconia

Accepted for publication 10 November 2017



Papilla-Crown Height Dimensions around Zirconia Implants in the Esthetic Area: A 3-Year Follow-Up Study

Kim Kniha, DMD,¹ Karl Andreas Schlegel, MD, DDS, PhD,¹ Heinz Kniha, MD, DDS, PhD,¹ Ali Modabber, MD, DDS, PhD,² Friedrich Neukam, MD, DDS, PhD,¹ & Kristian Kniha, MD, DDS, PhD,³

¹Department of Oral and Cranio-Maxillofacial Surgery, Friedrich-Alexander-University Erlangen-Nürnberg, Erlangen, Germany

²Private Dental Clinic, Drs. Kniha and Gahlert, Munich, Germany

³Department of Oral and Cranio-Maxillofacial Surgery, University Hospital Aachen, Germany

Keywords

Ceramic dental implants; dental crown; gingiva; papilla; zirconia.

Correspondence

Kristian Kniha, Department of Oral and Cranio-Maxillofacial Surgery, University Hospital Aachen, Pauwelsstraße 30, 52074 Aachen, Germany. E-mail: kkniha@ukaachen.de

Kristian Kniha

<http://orcid.org/0000-0001-8579-2622>

The authors report no conflicts of interest related to this study and do not have any financial interest in the companies whose materials are included in this article.

Accepted November 16, 2017

doi: 10.1111/jopr.12766

Abstract

Purpose: Soft tissue interactions with ceramic dental implants have been shown to have favorable esthetic outcomes. The relationship between the crown proportion around zirconia implants in the esthetic area and the relation between the gingival biotype and changes in gingival biotype over time.

Materials and Methods: This was a prospective study. The crown proportion around zirconia implants in the esthetic area was assessed after 3 months, 1 year, and 3 years. The relationship between the gingival biotype and changes in gingival biotype over time was assessed.

Results: The papilla-crown proportion improved over time. The papilla-crown proportion improved after 3 months, 1 year, and 3 years (41.7% after 3 years). The gingival biotype was stable over time. Significant papillary fill was observed after 3 months and 3 years ($p < 0.001$).

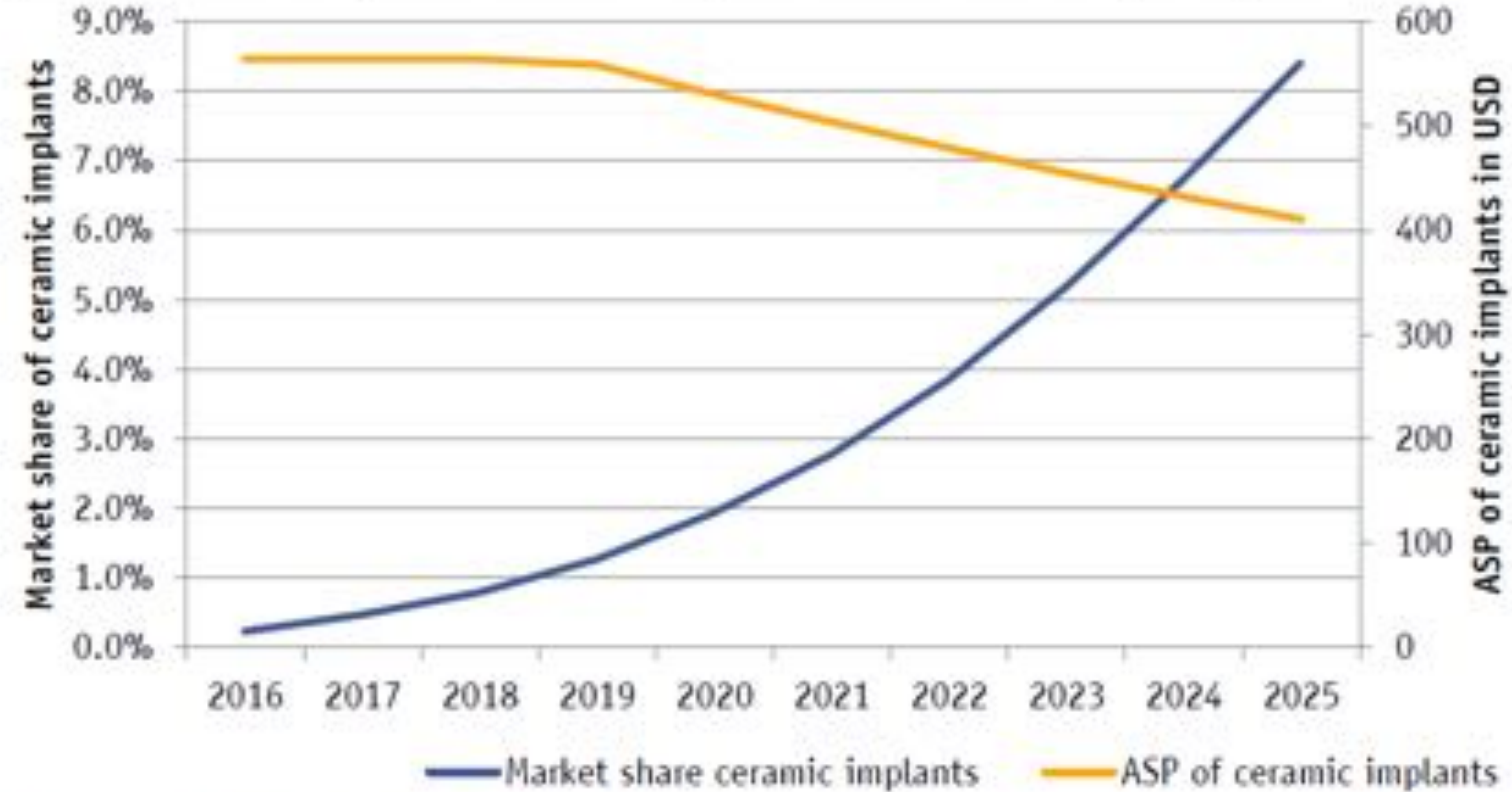
Conclusions: An ideal papilla-crown proportion was observed after 3 years. A thin or thick gingival biotype was associated with soft tissue alterations.

CURRENTLY AVAILABLE



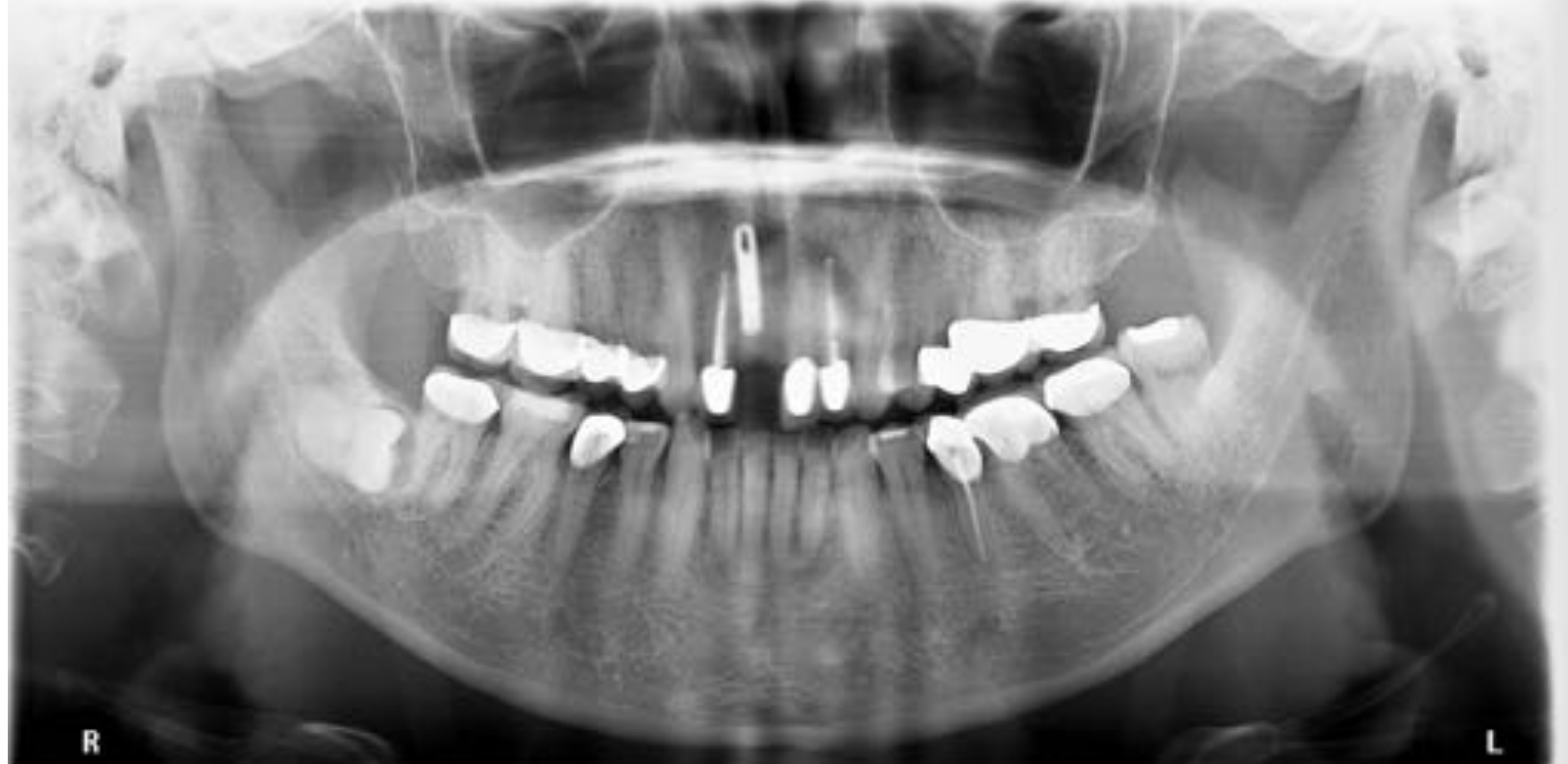MARKET SHARE

Expected trends in global ceramic implant market shares (units) and ASP

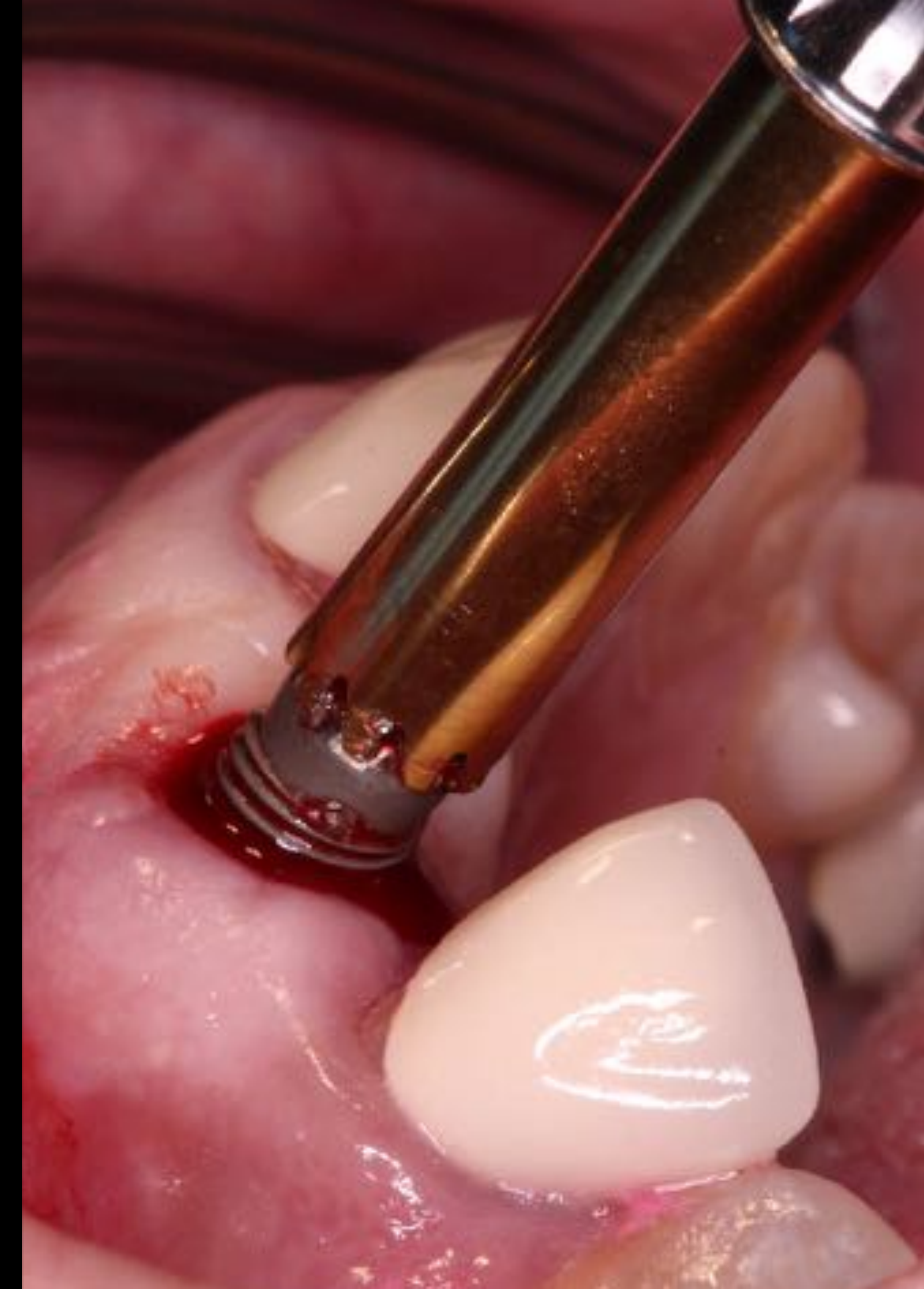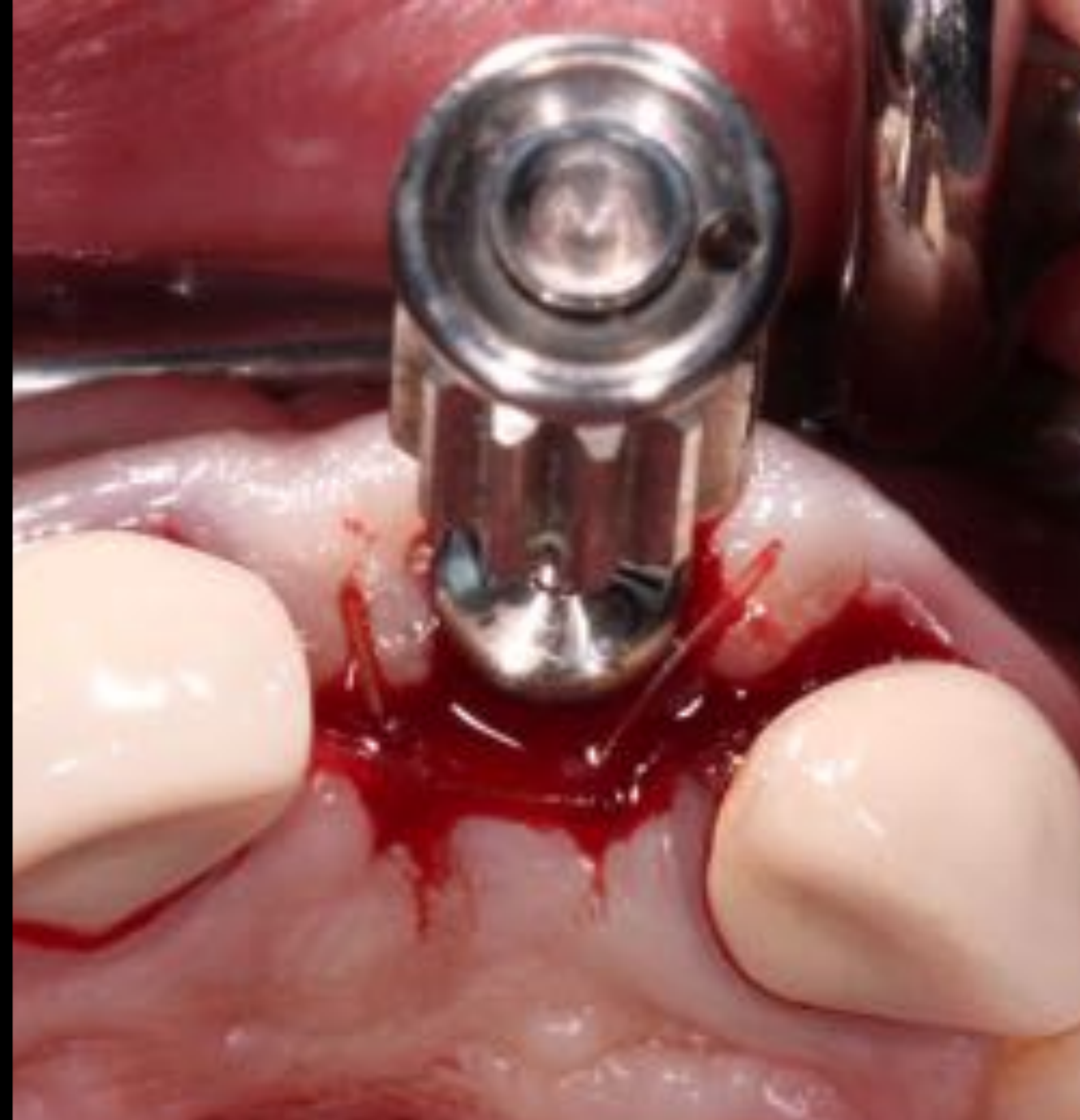

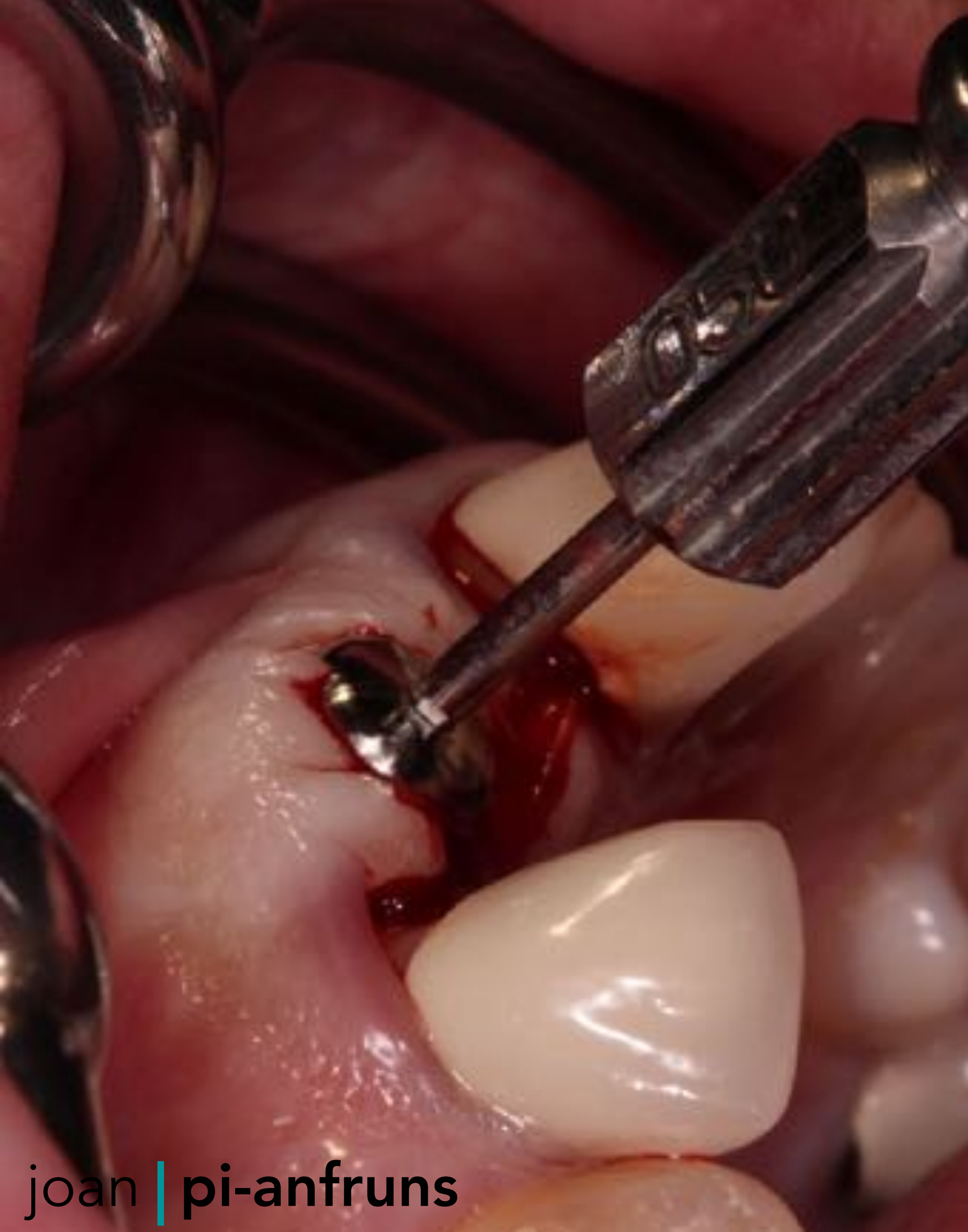
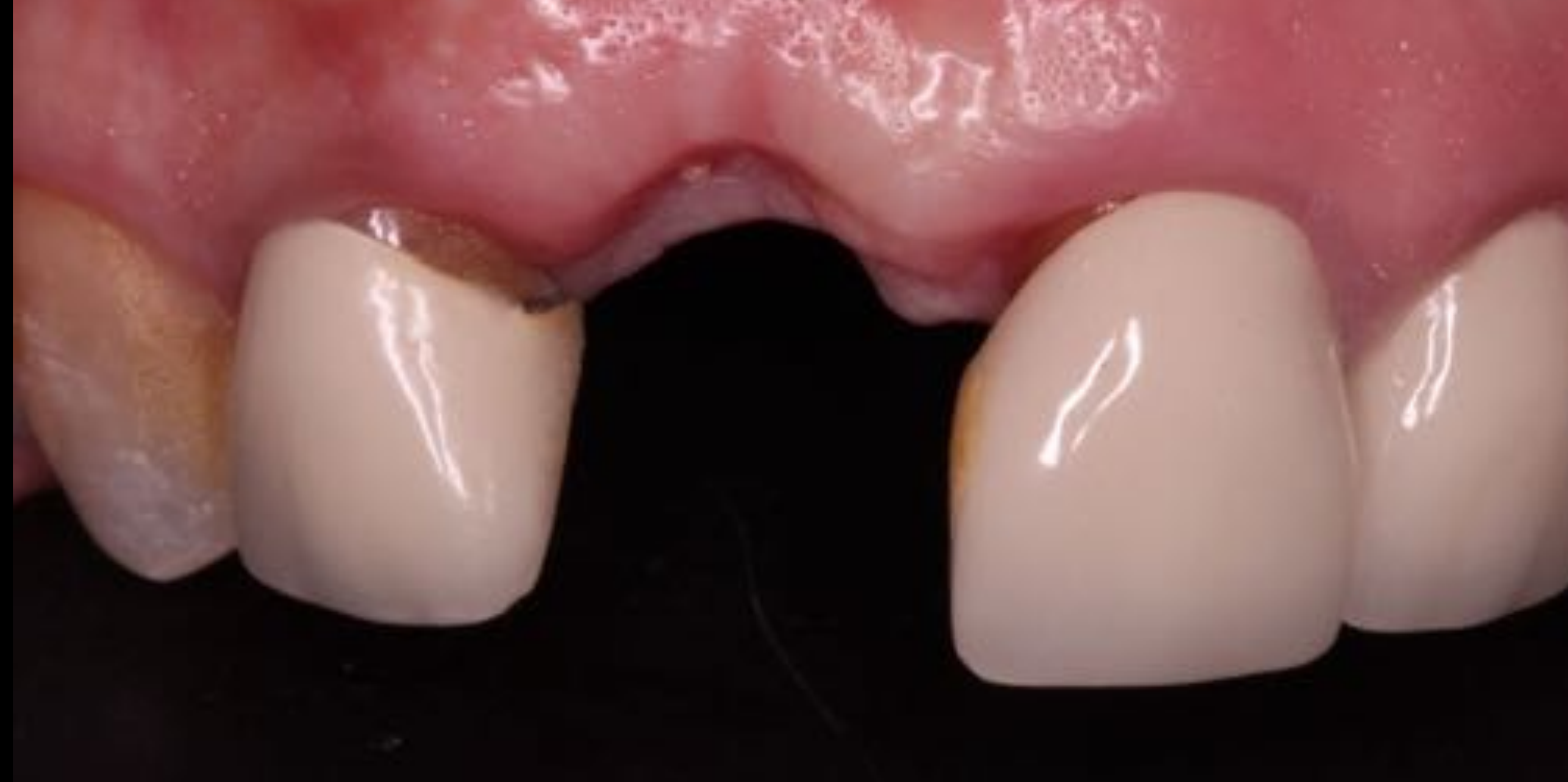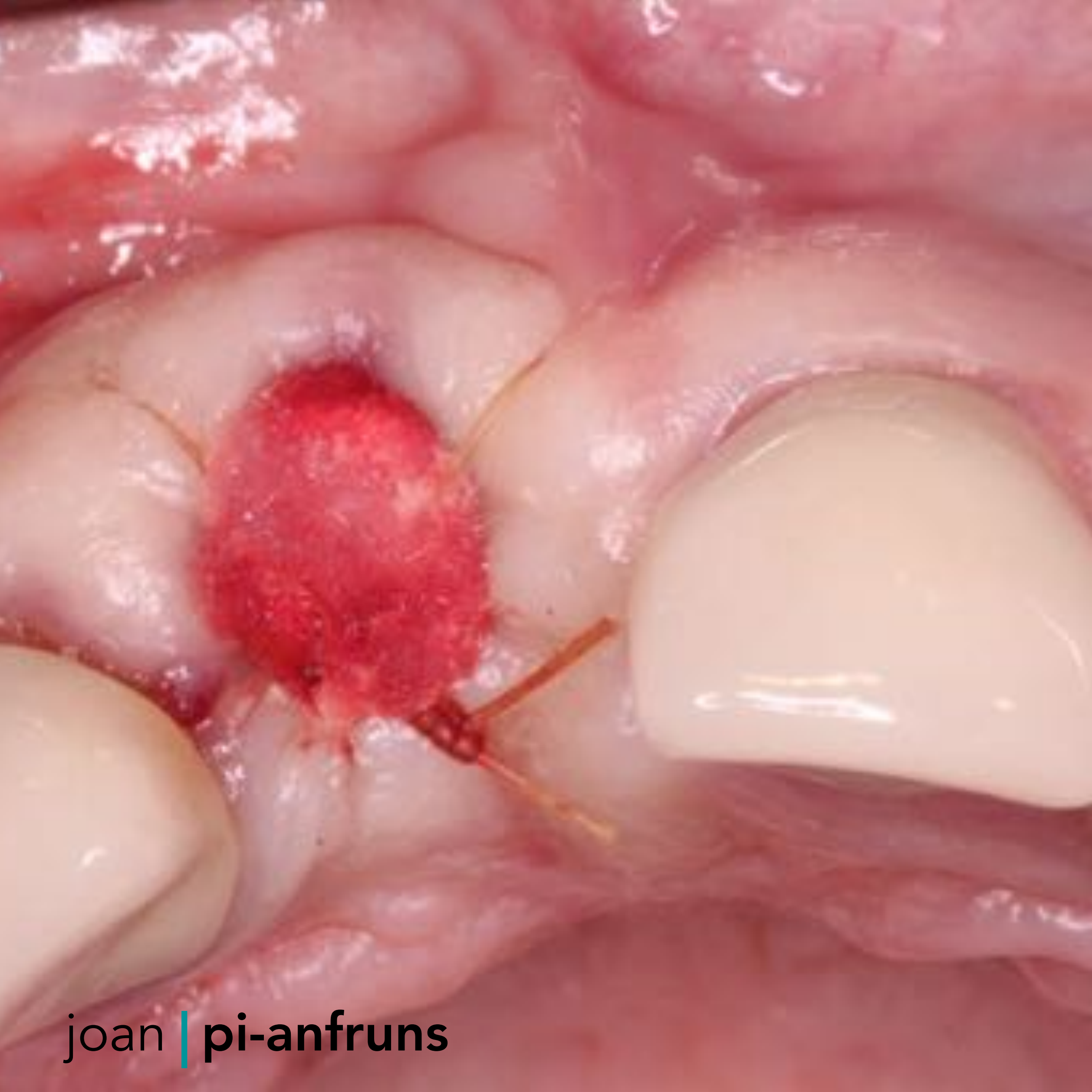
Source: Vontobel Equity Research

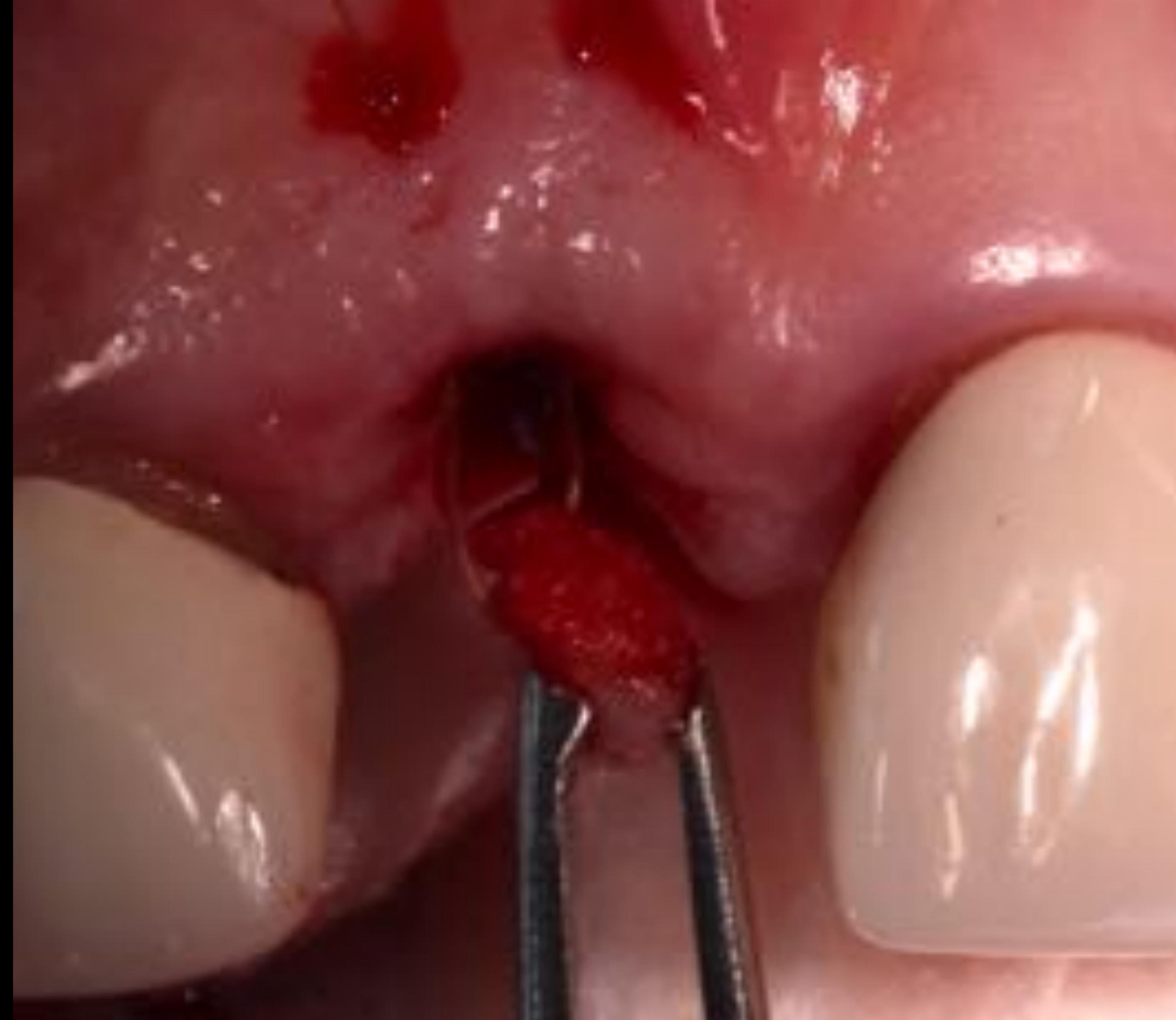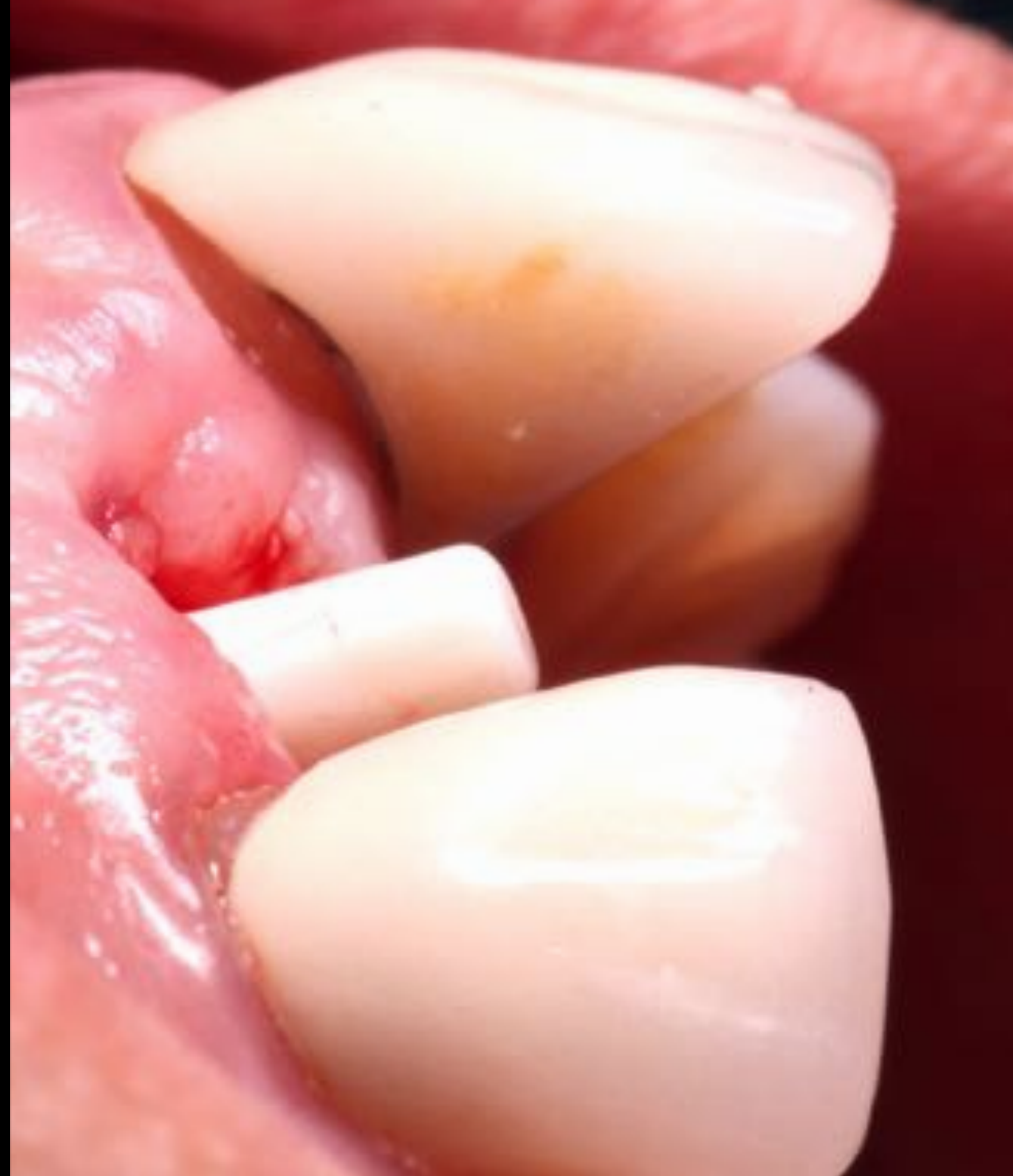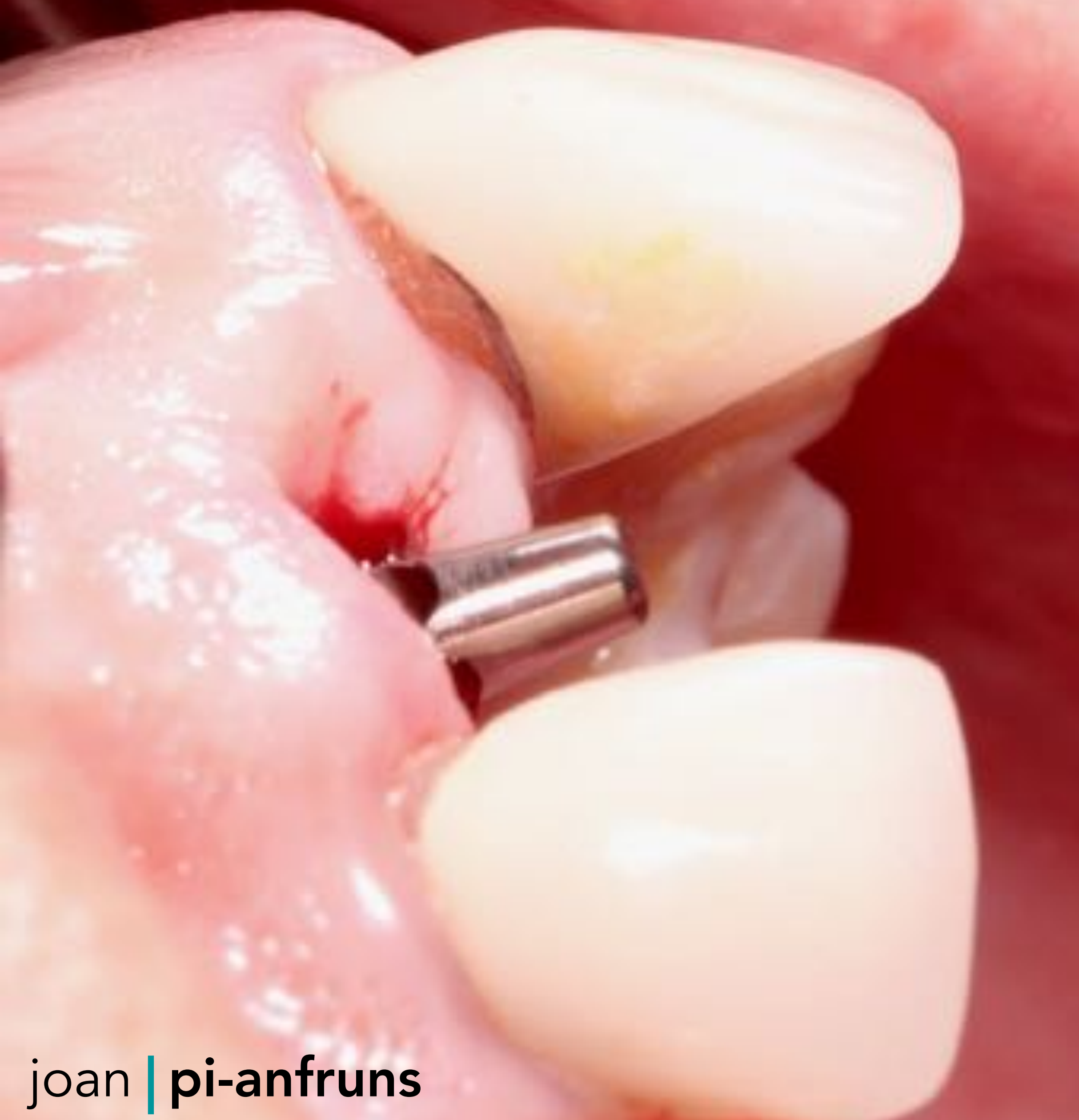Volume and trend estimated based on competitor information and customer feedback. 1-piece source: 2012_11_28 Business Case 1&2-piece ceramic implant.xls // 2-piece source: 20150526_BC_2_piece_global_forecast.xlsx

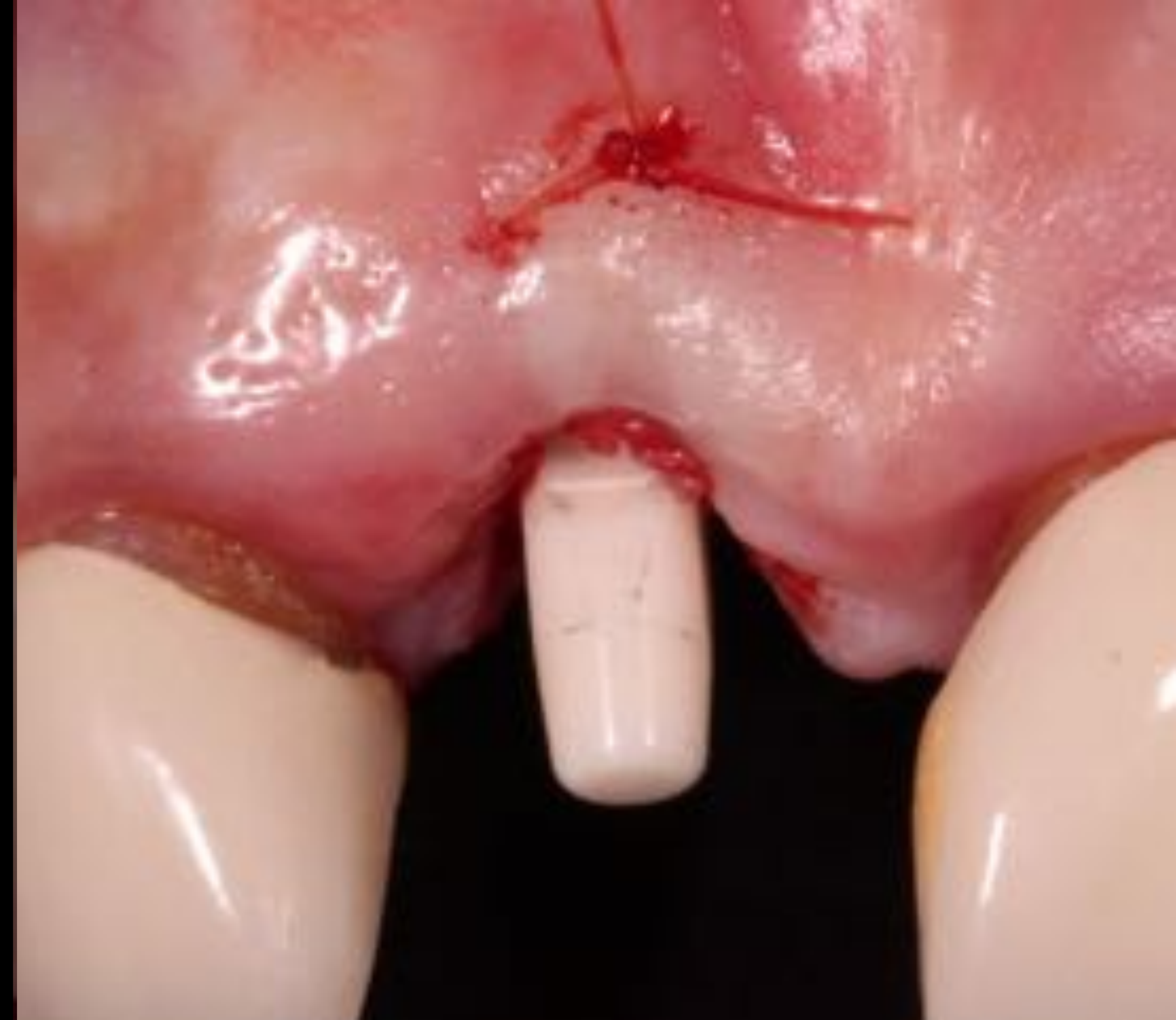



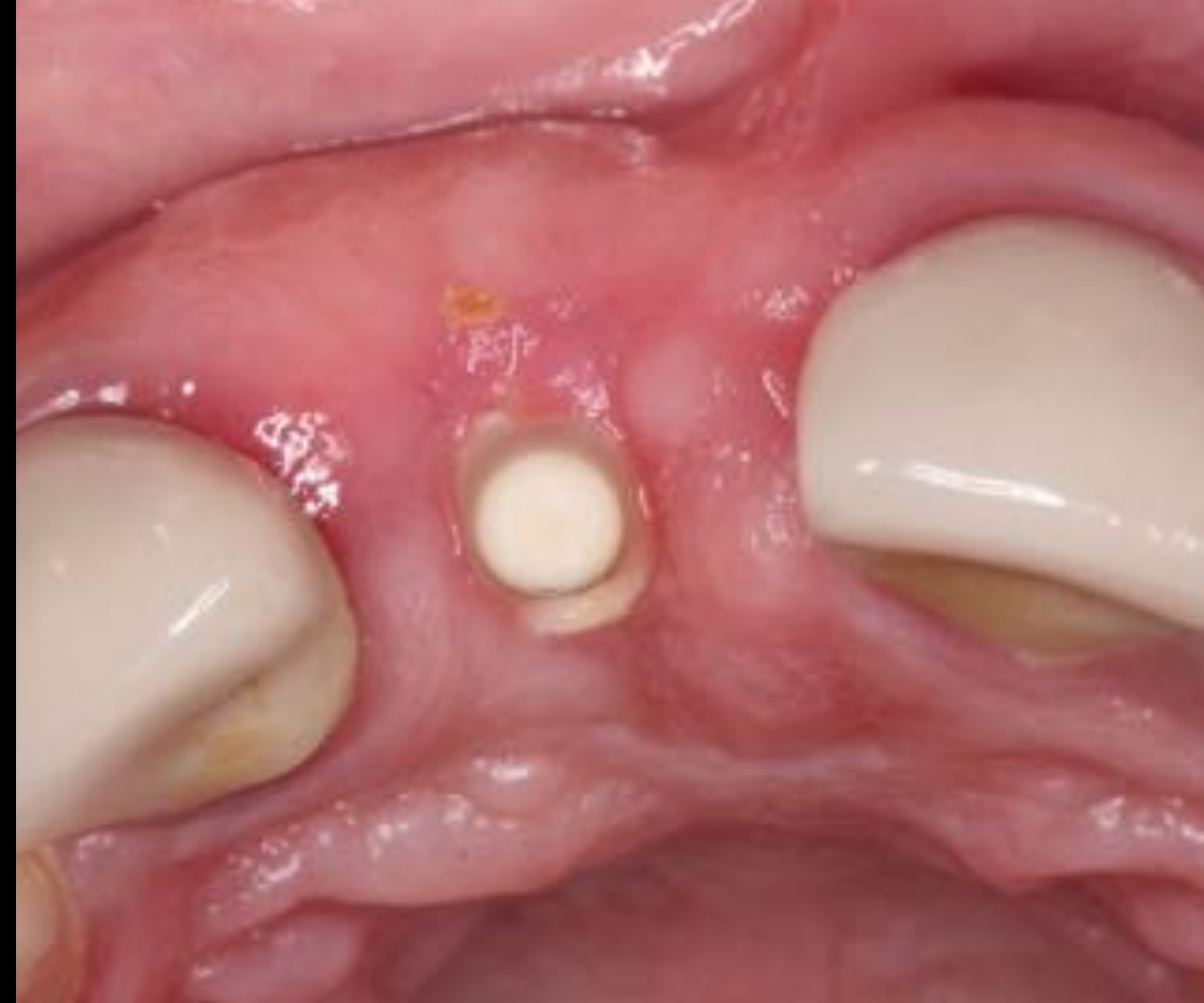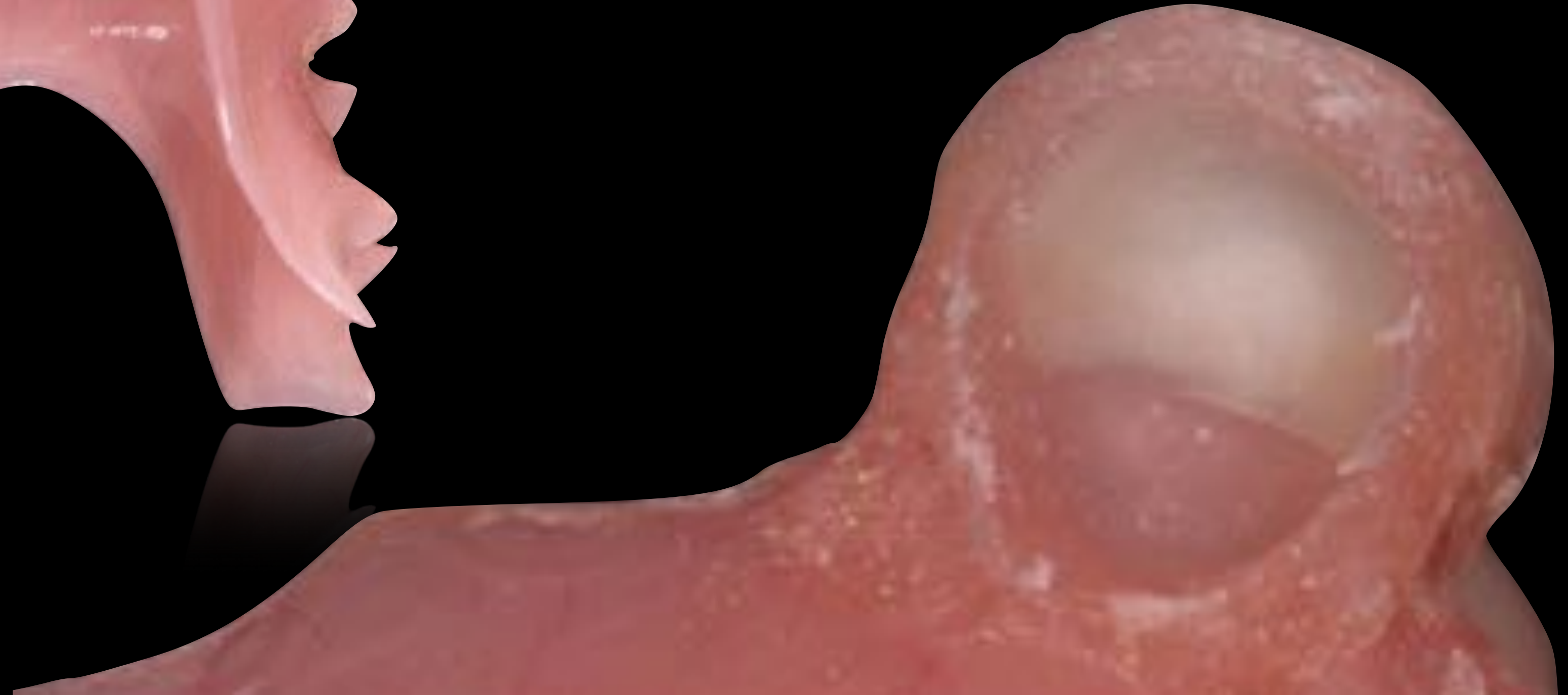




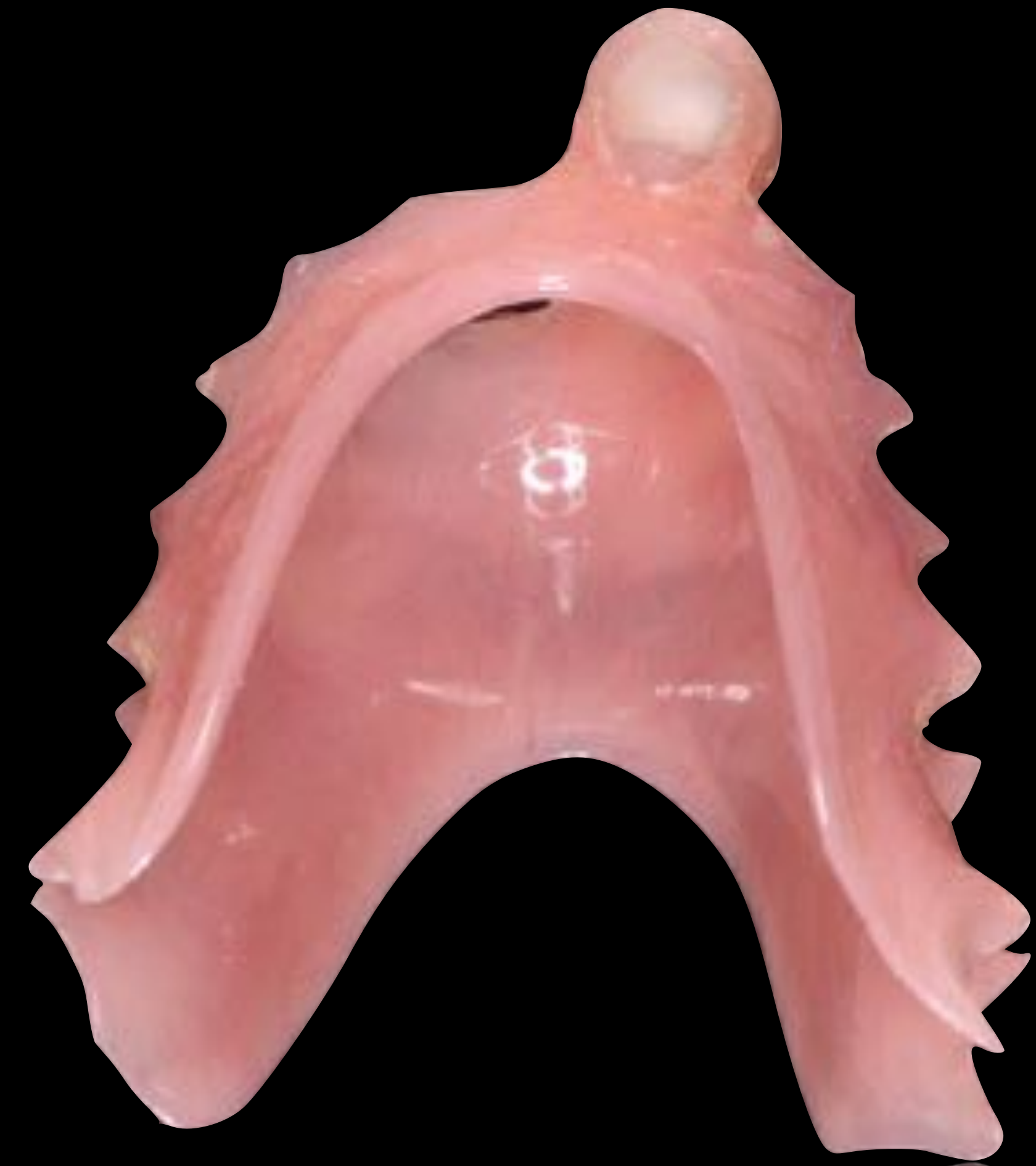


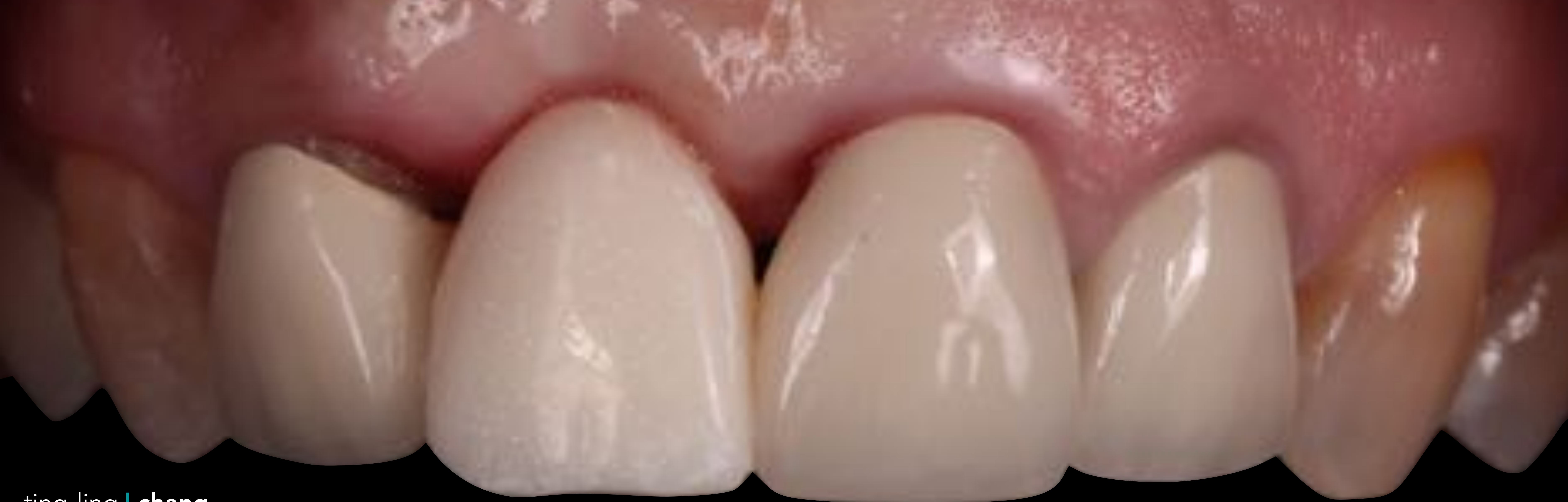
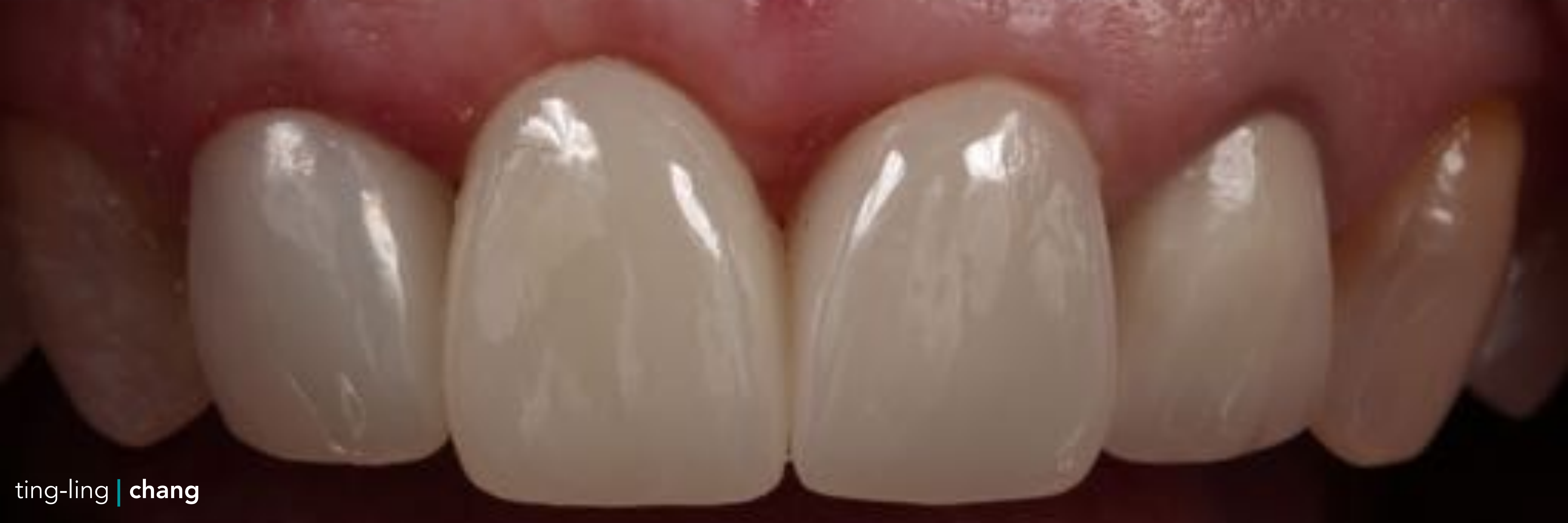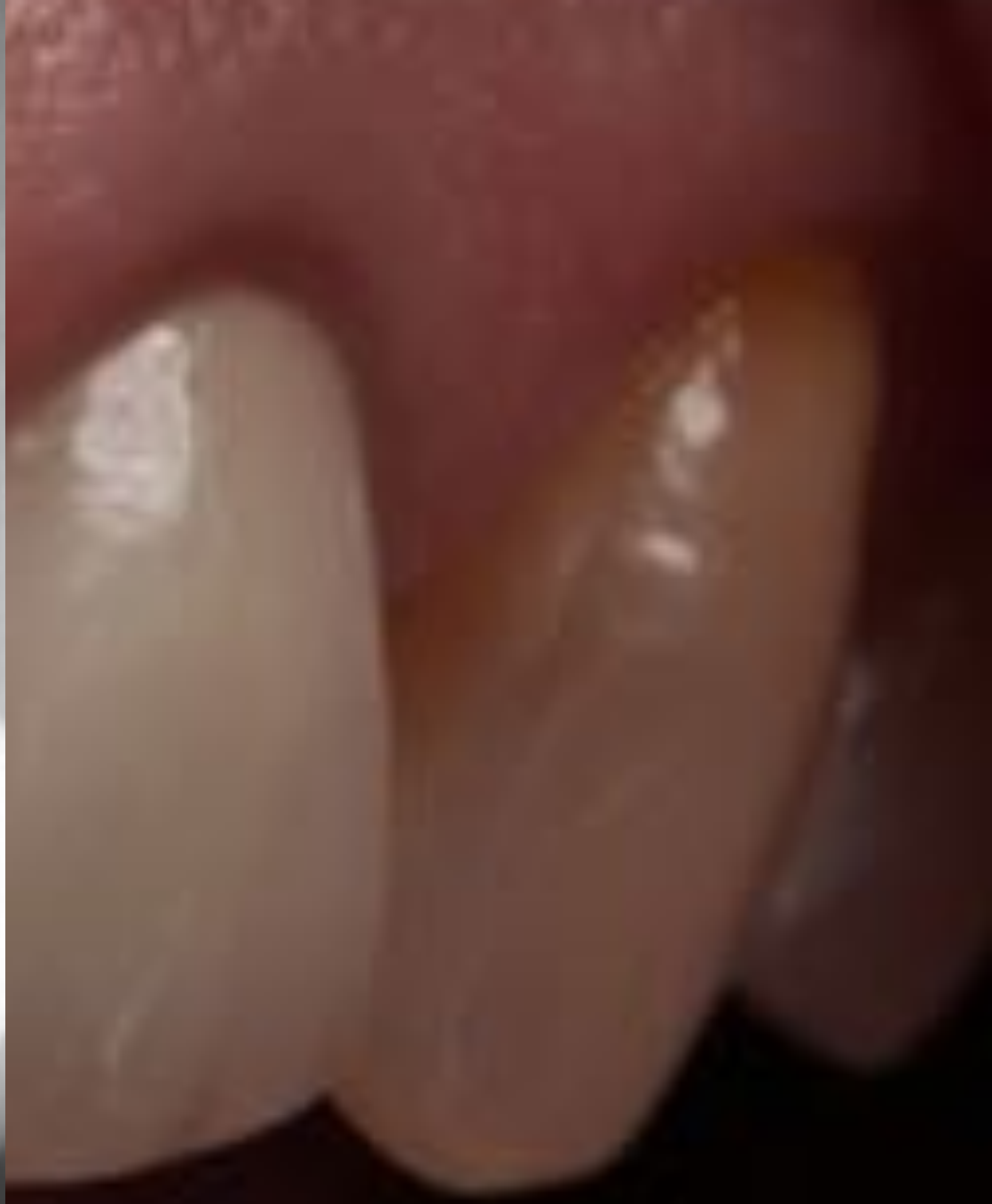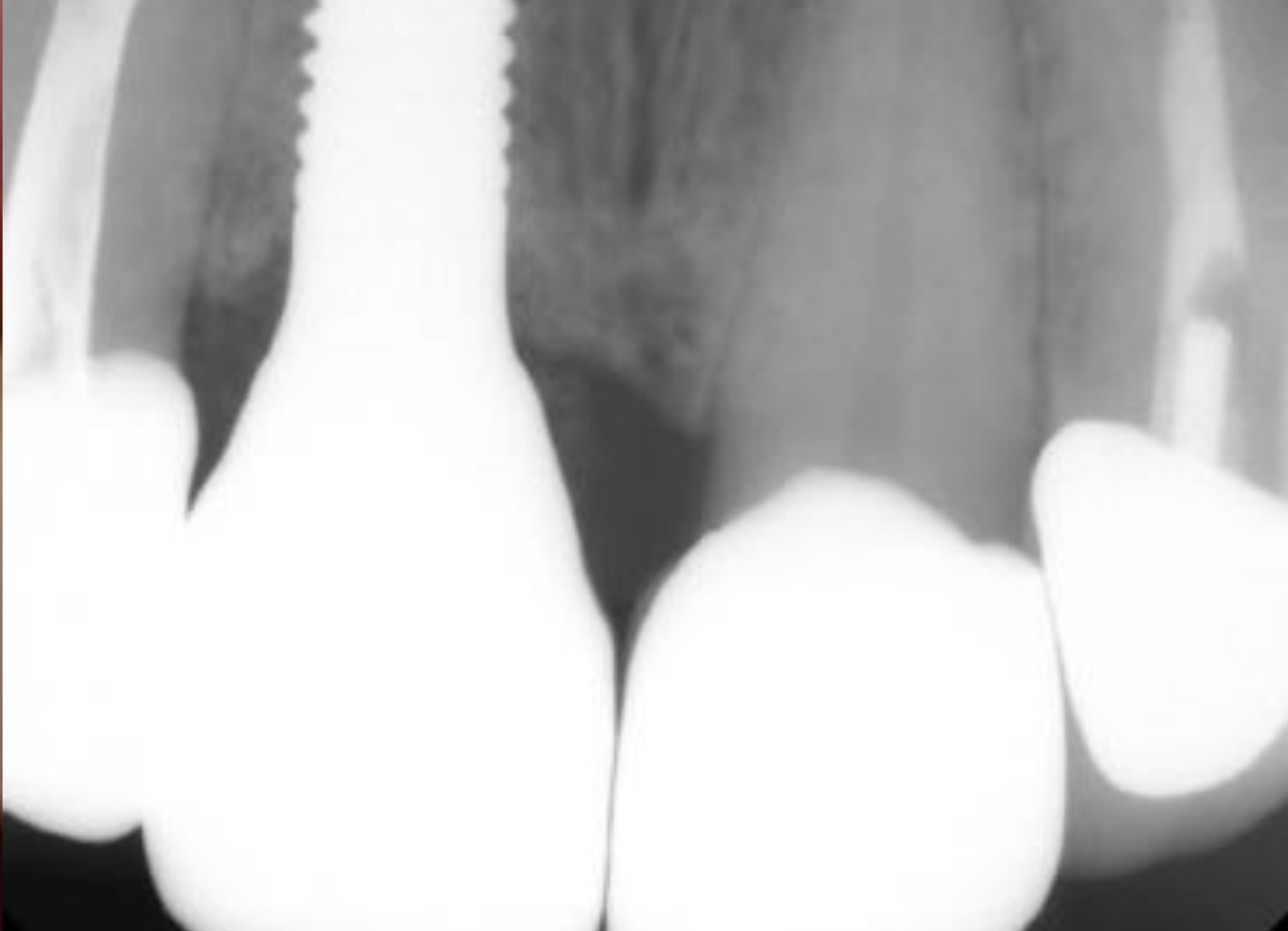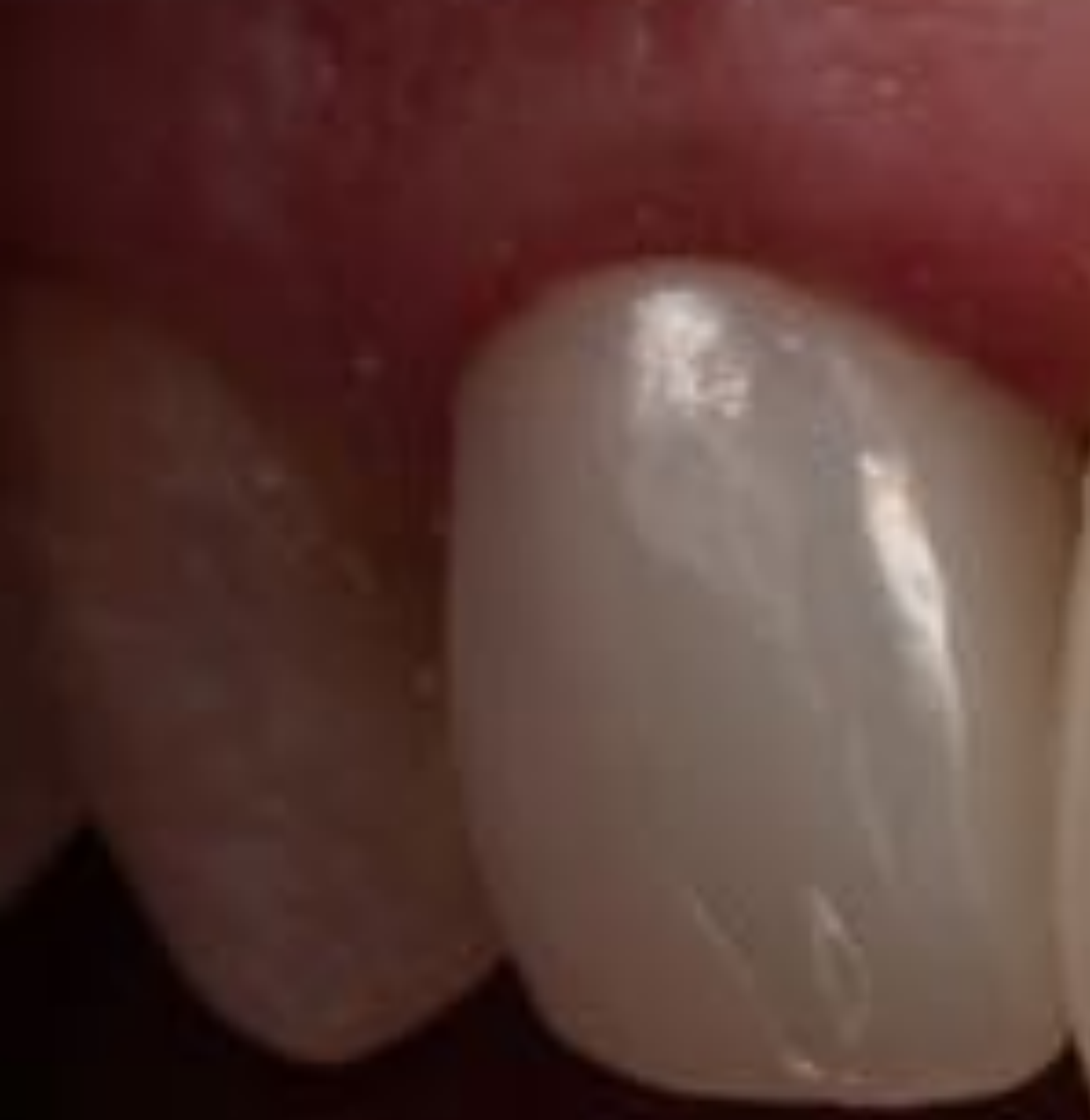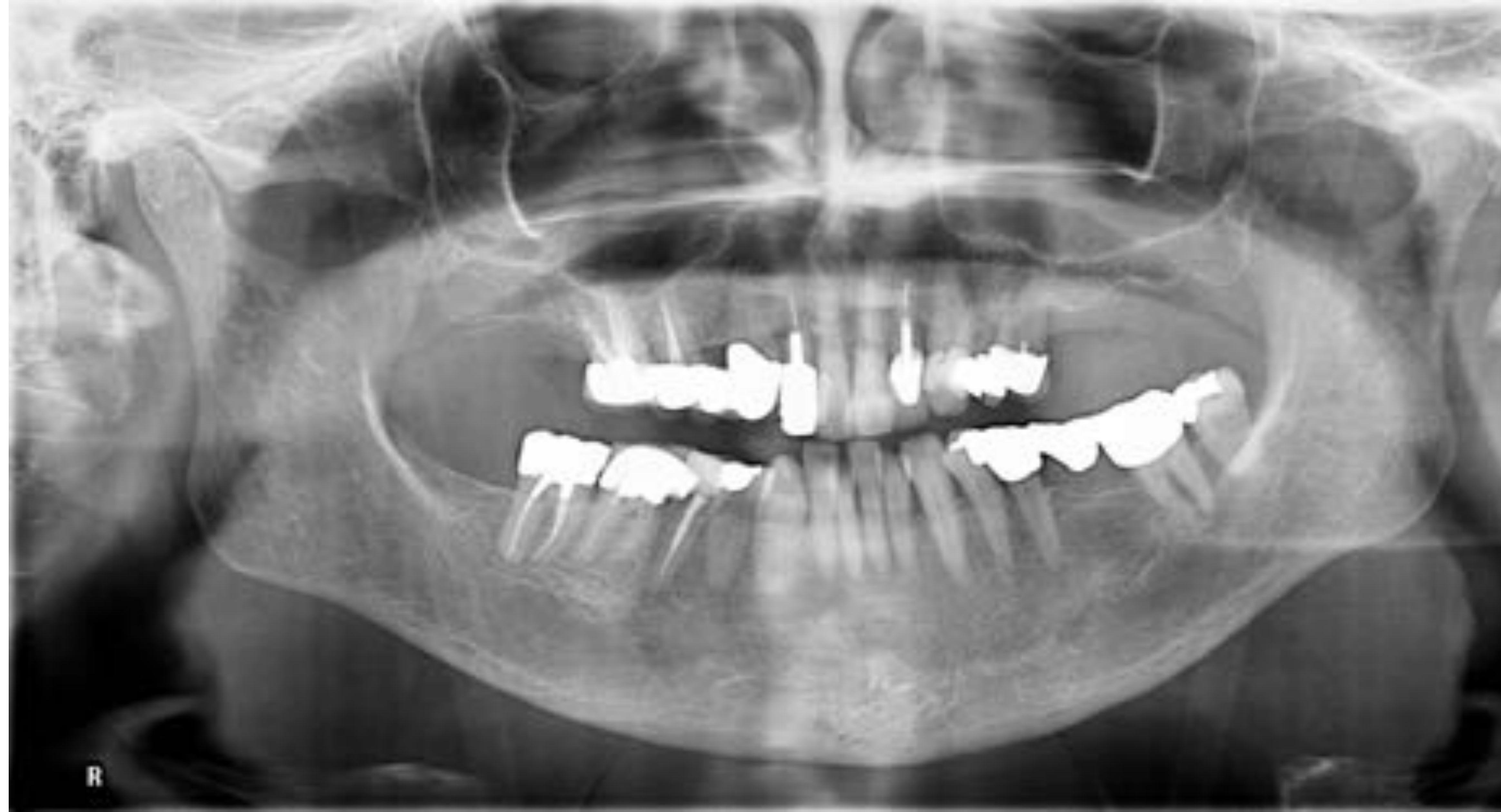3 months

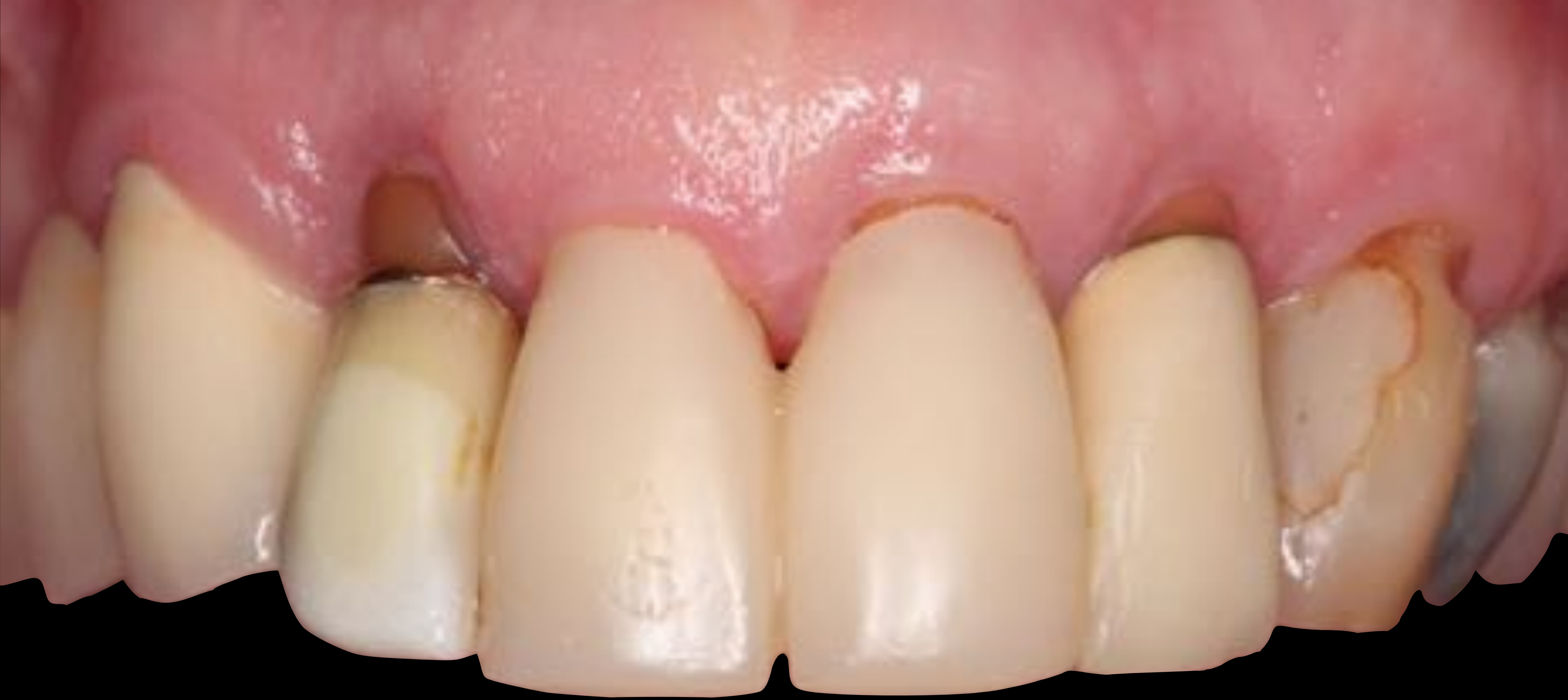

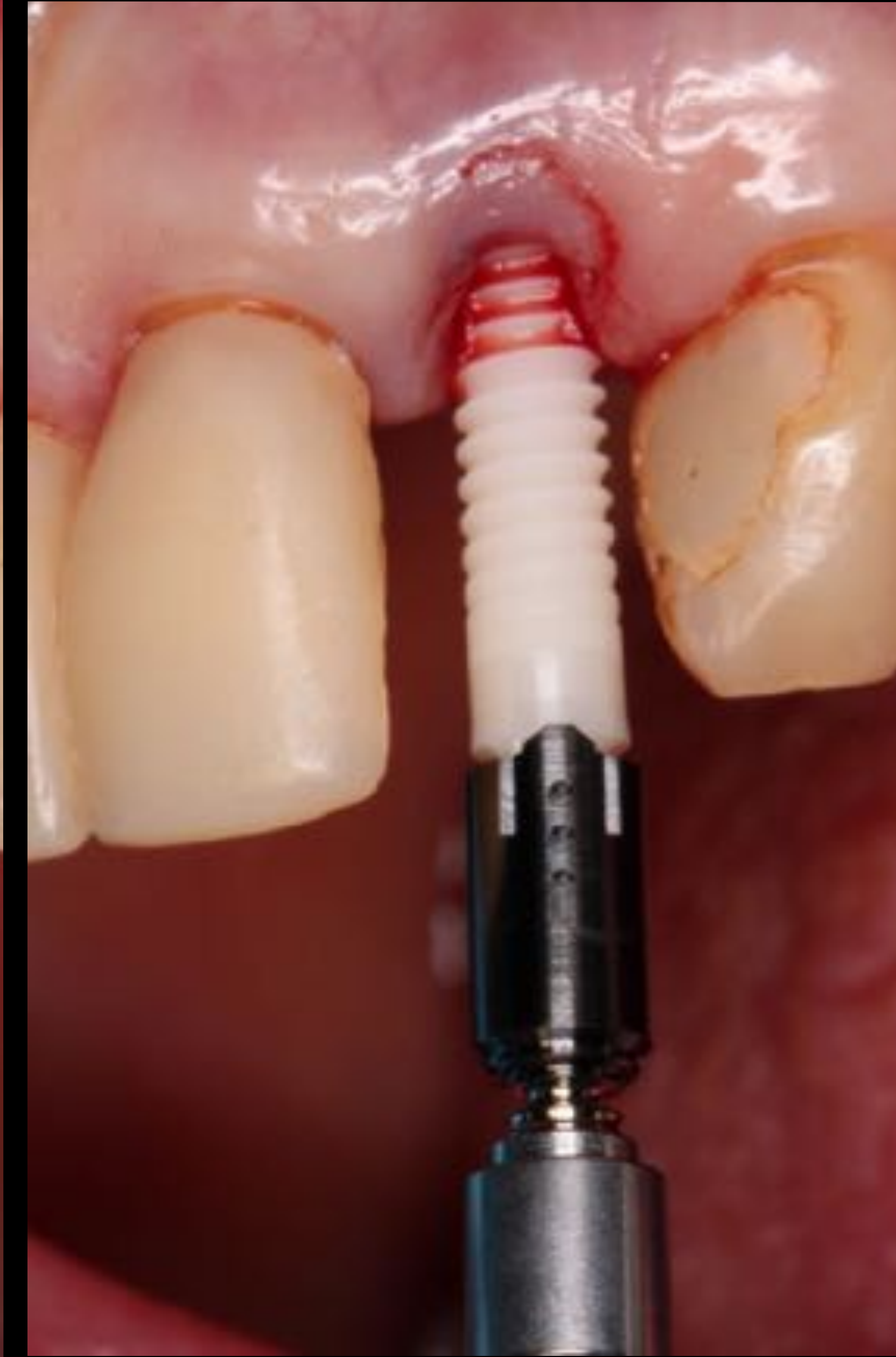

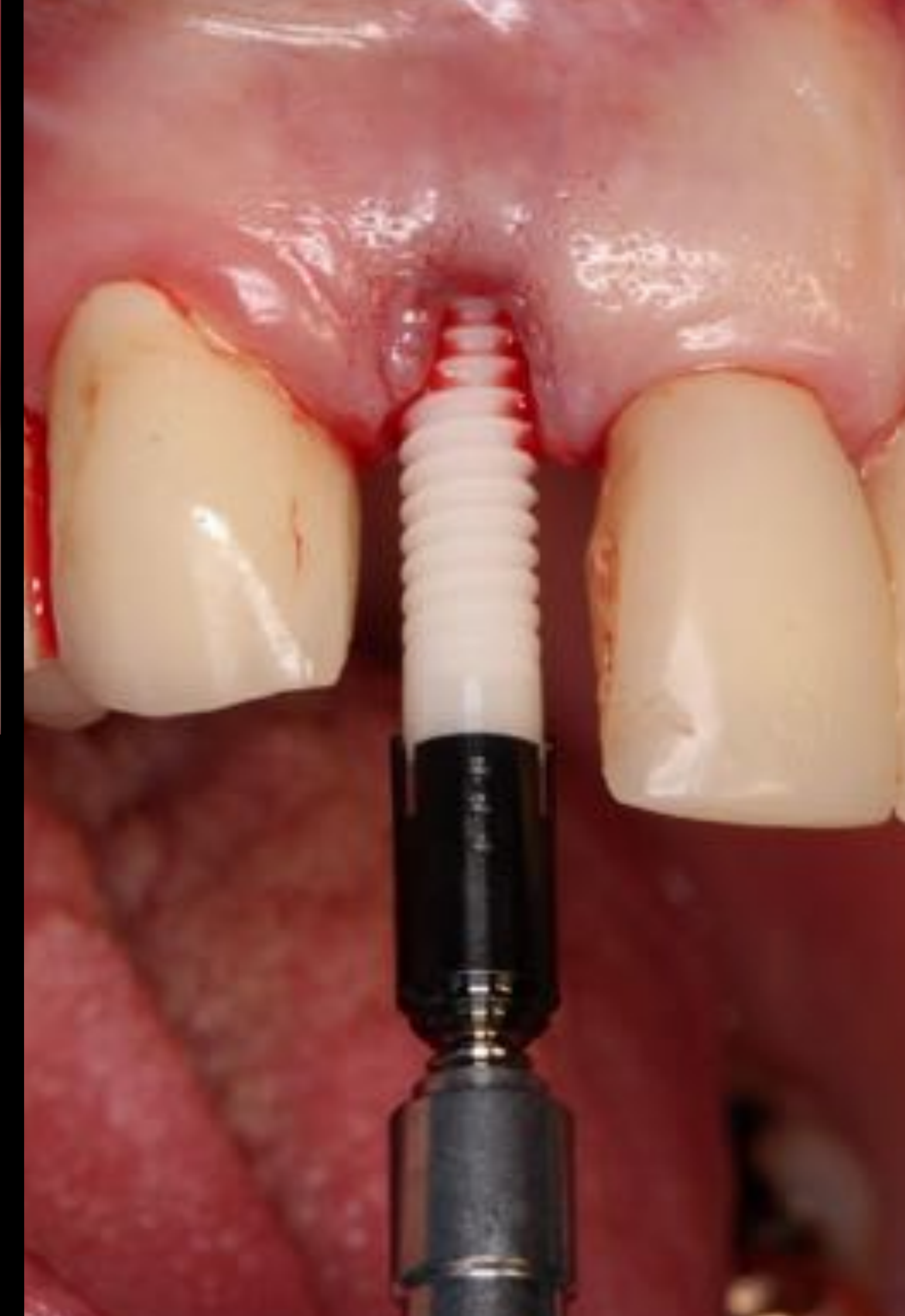
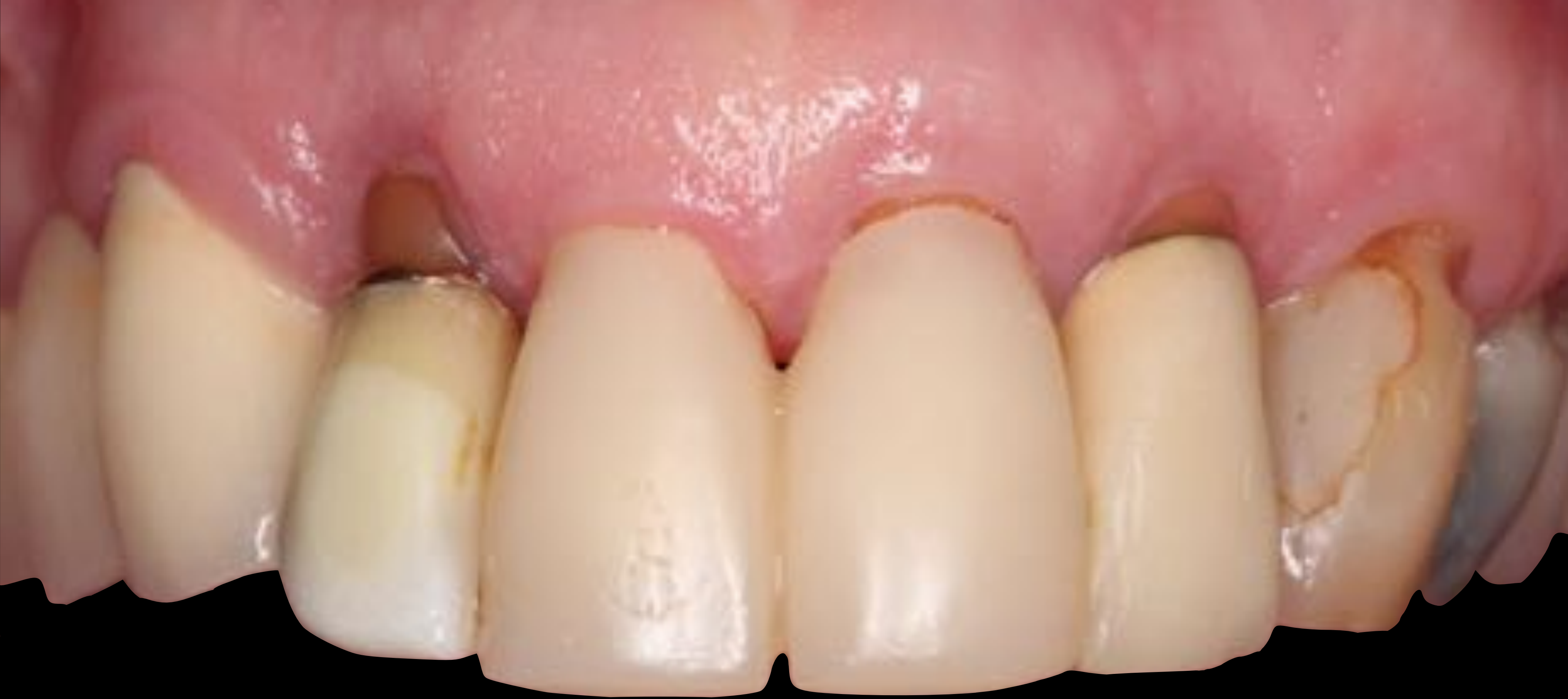


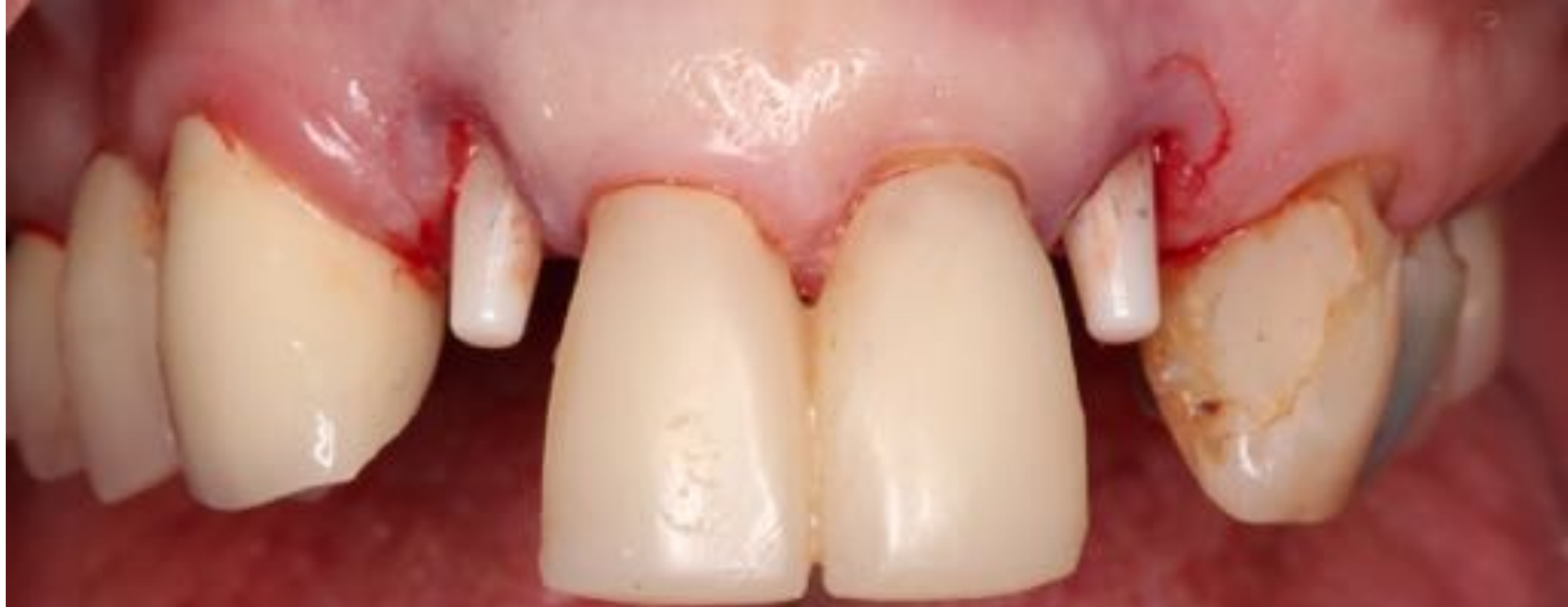


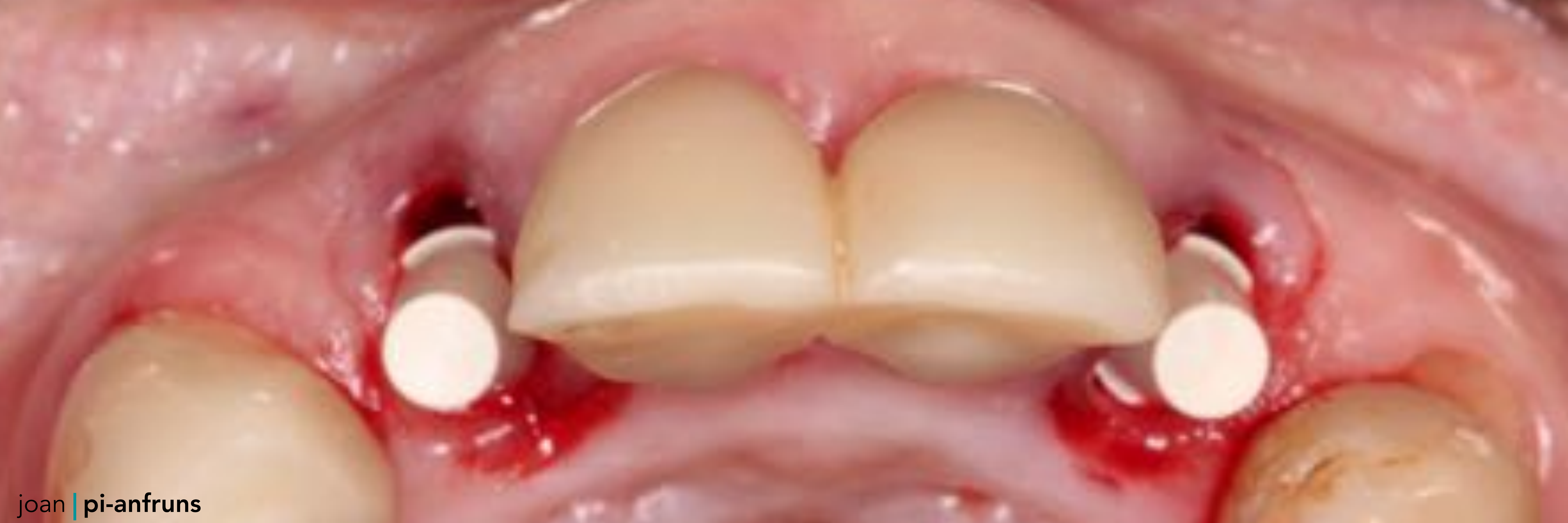


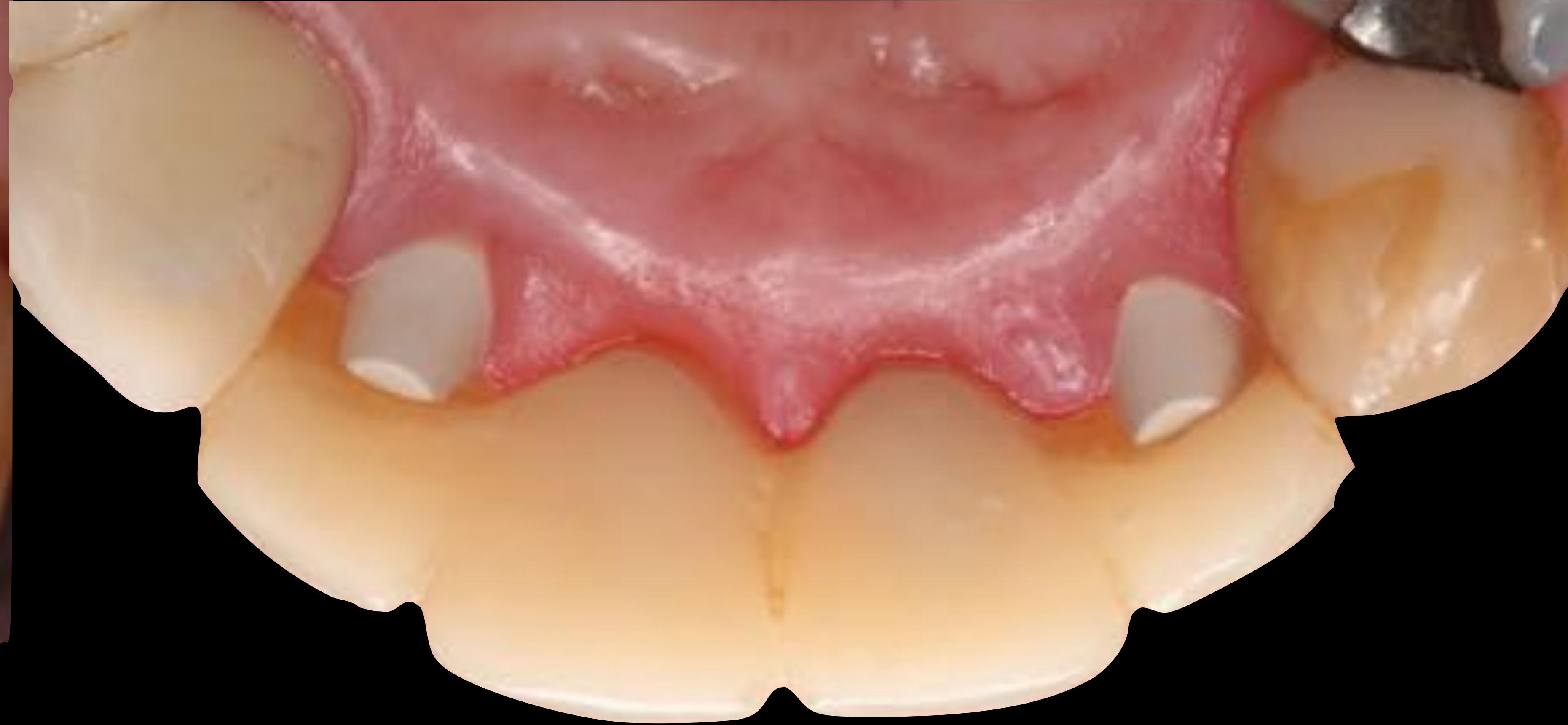
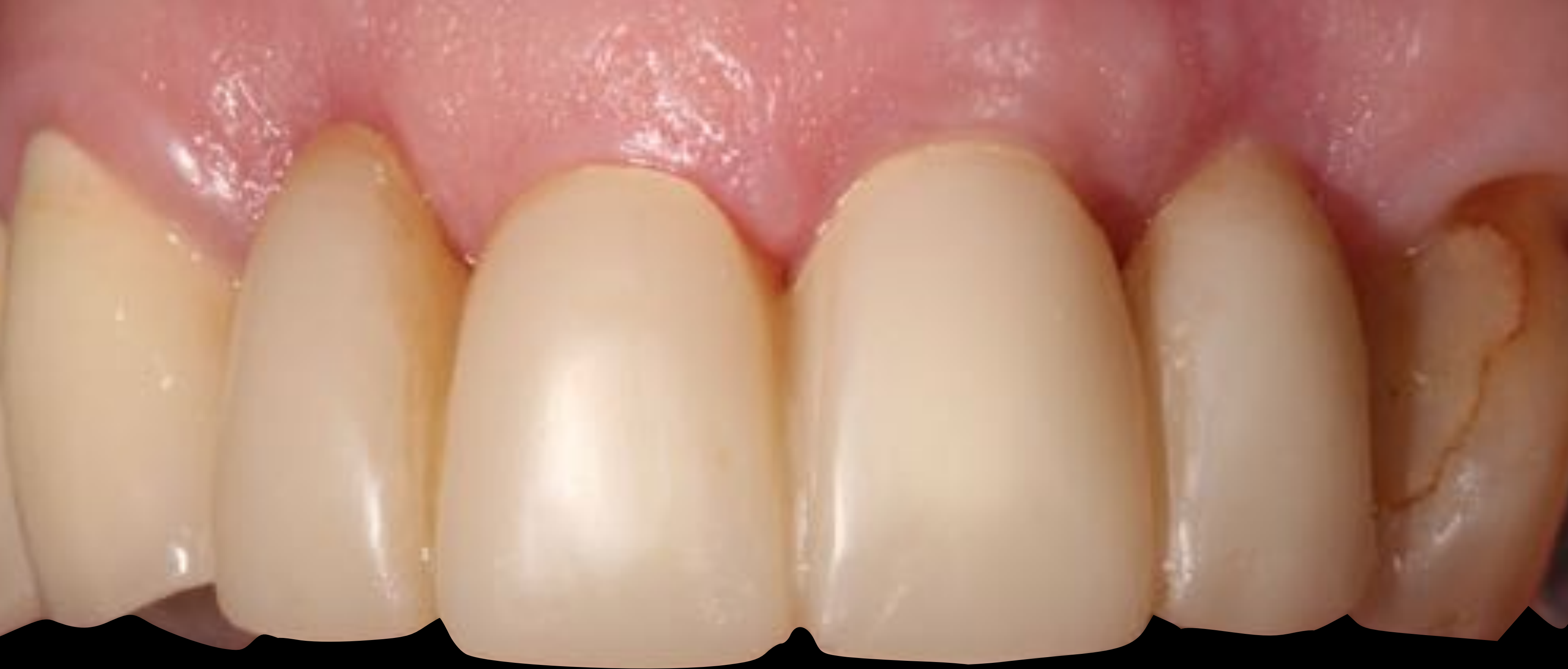


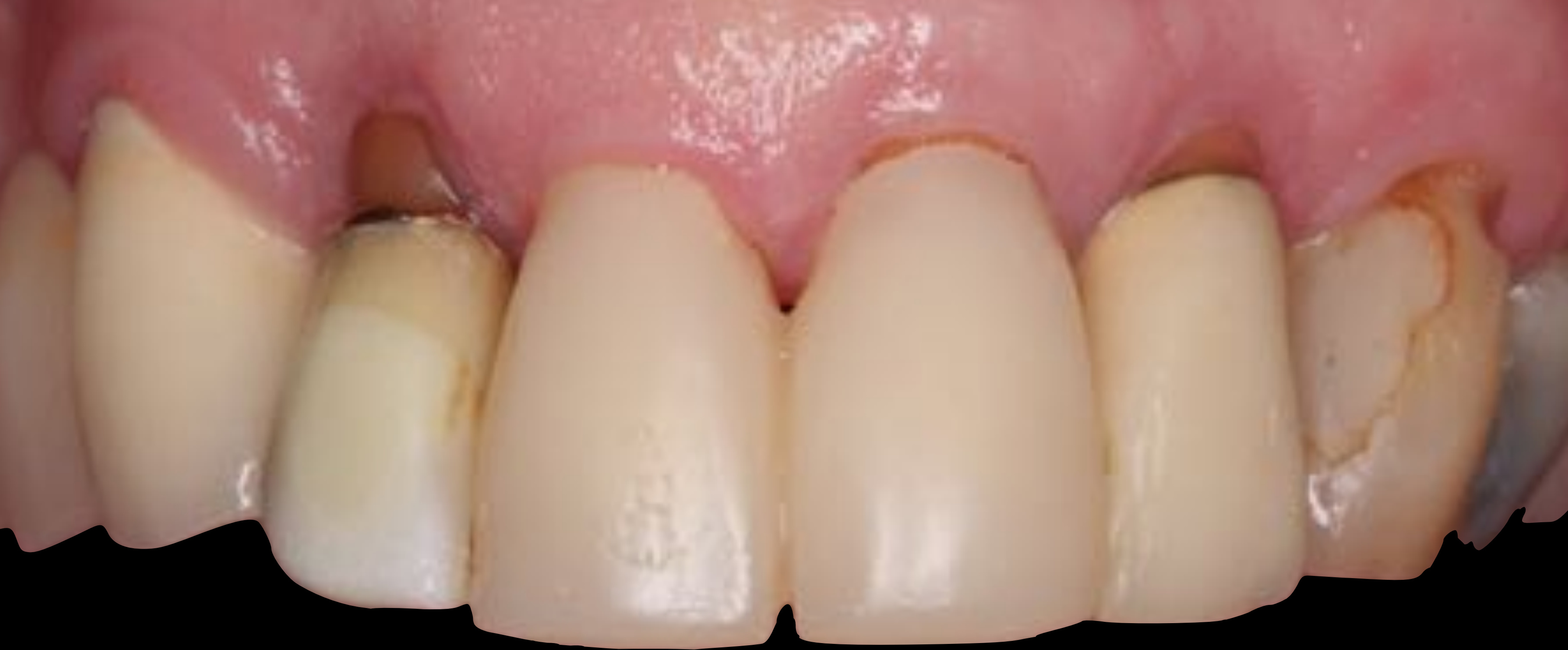


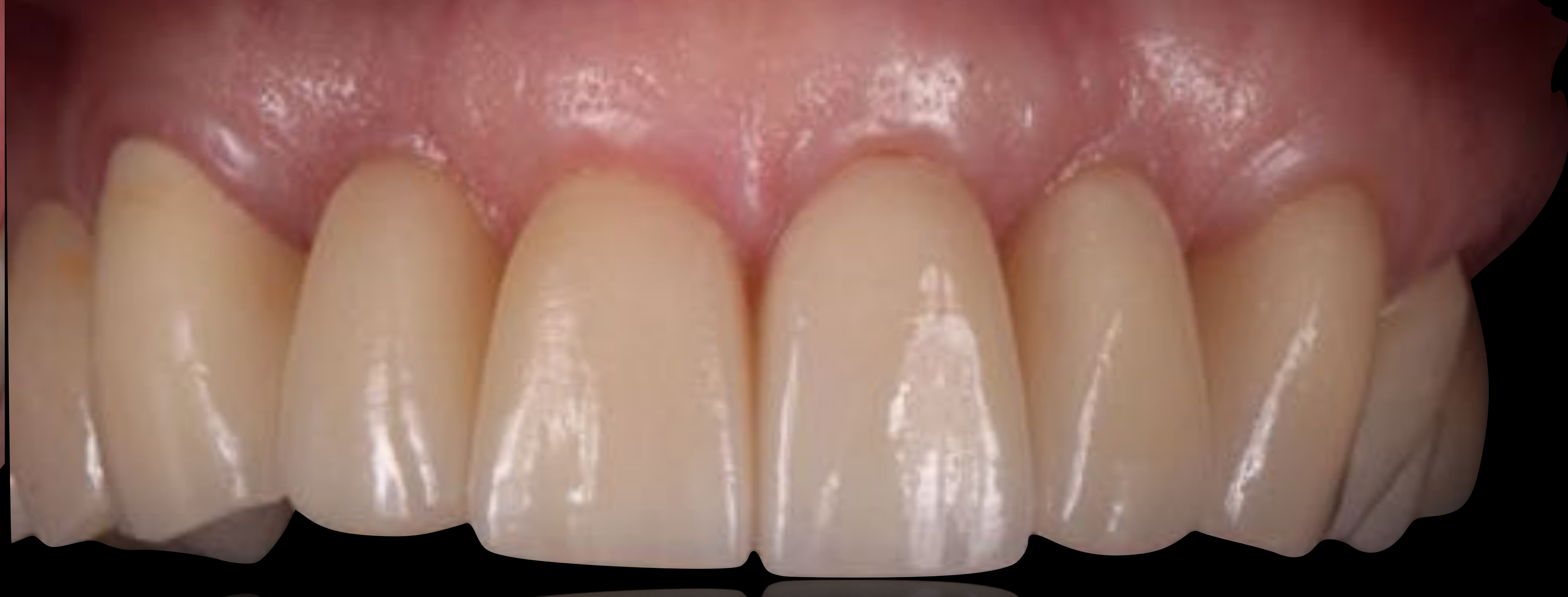



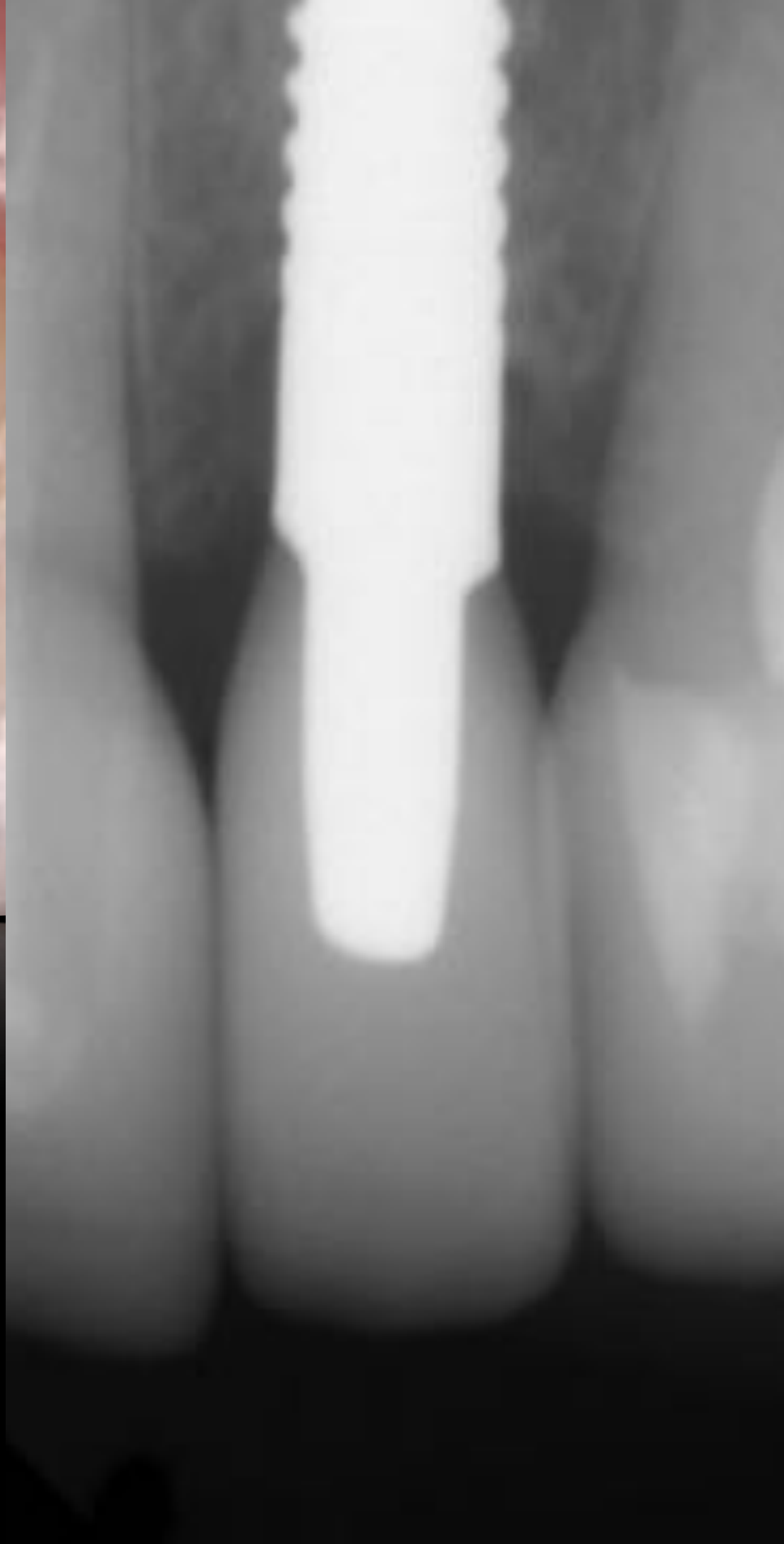
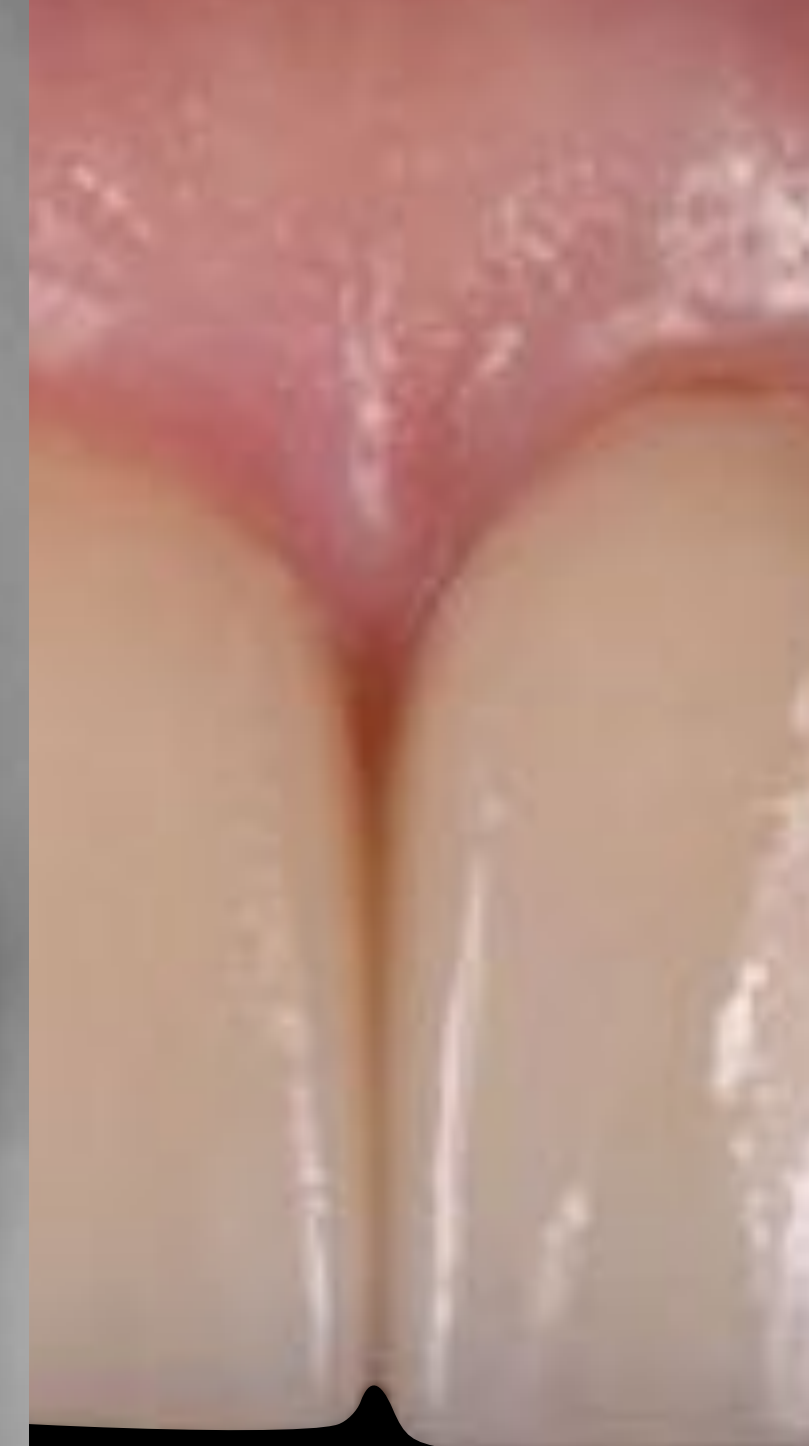
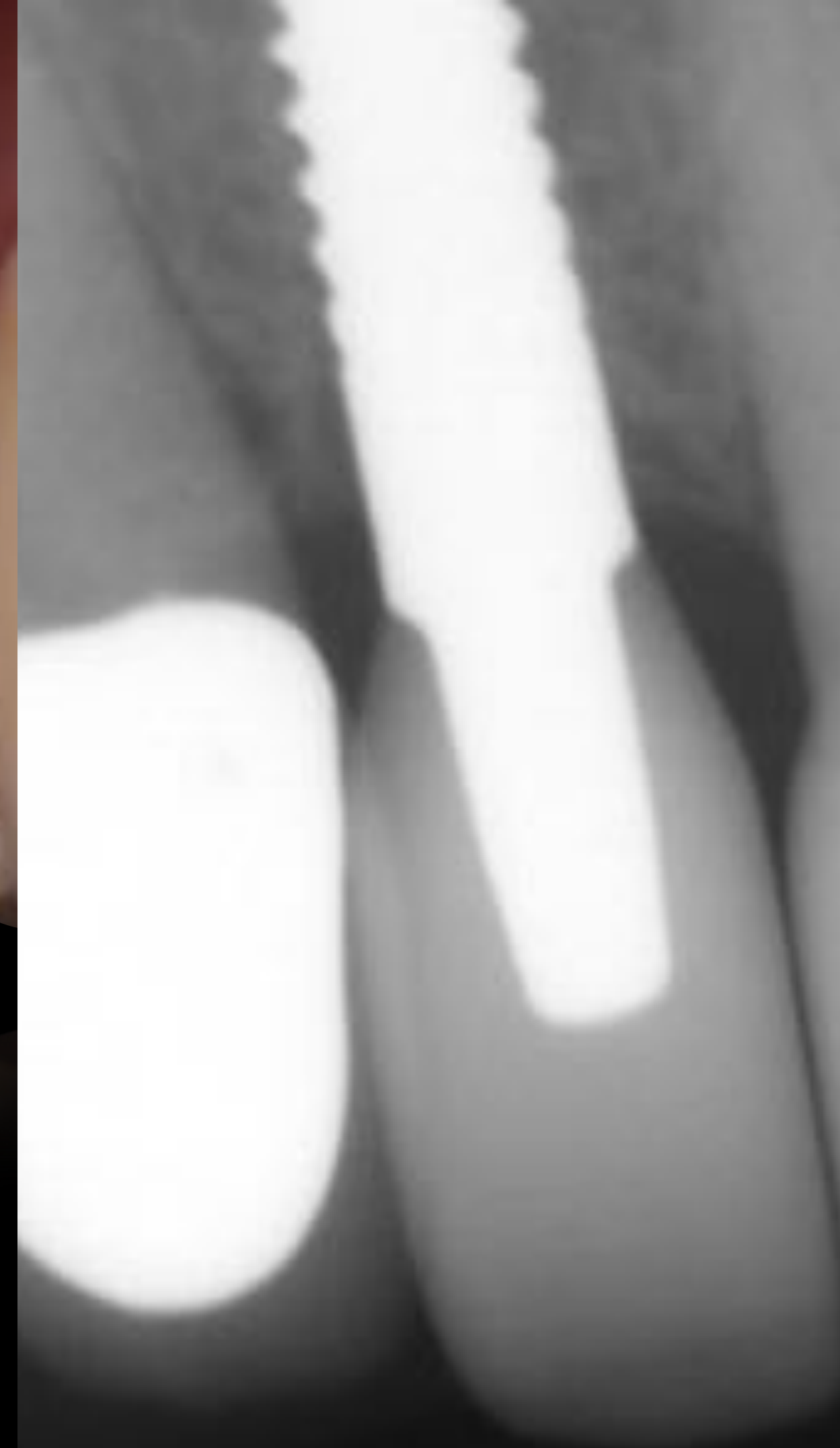ZIRCONIA IMPLANTS LIMITATIONS

surgical



ZIRCONIA IMPLANTS LIMITATIONS

- surgical precision

surgical



ZIRCONIA IMPLANTS LIMITATIONS

- surgical precision
- margin placement

surgical



ZIRCONIA IMPLANTS LIMITATIONS

- surgical precision
- margin placement
- one piece, non-submerged

surgical



ZIRCONIA IMPLANTS LIMITATIONS

- surgical precision
- margin placement
- one piece, non-submerged
- primary stability

surgical



ZIRCONIA IMPLANTS LIMITATIONS

- surgical precision
- margin placement
- one piece, non-submerged
- primary stability
- grafting

surgical

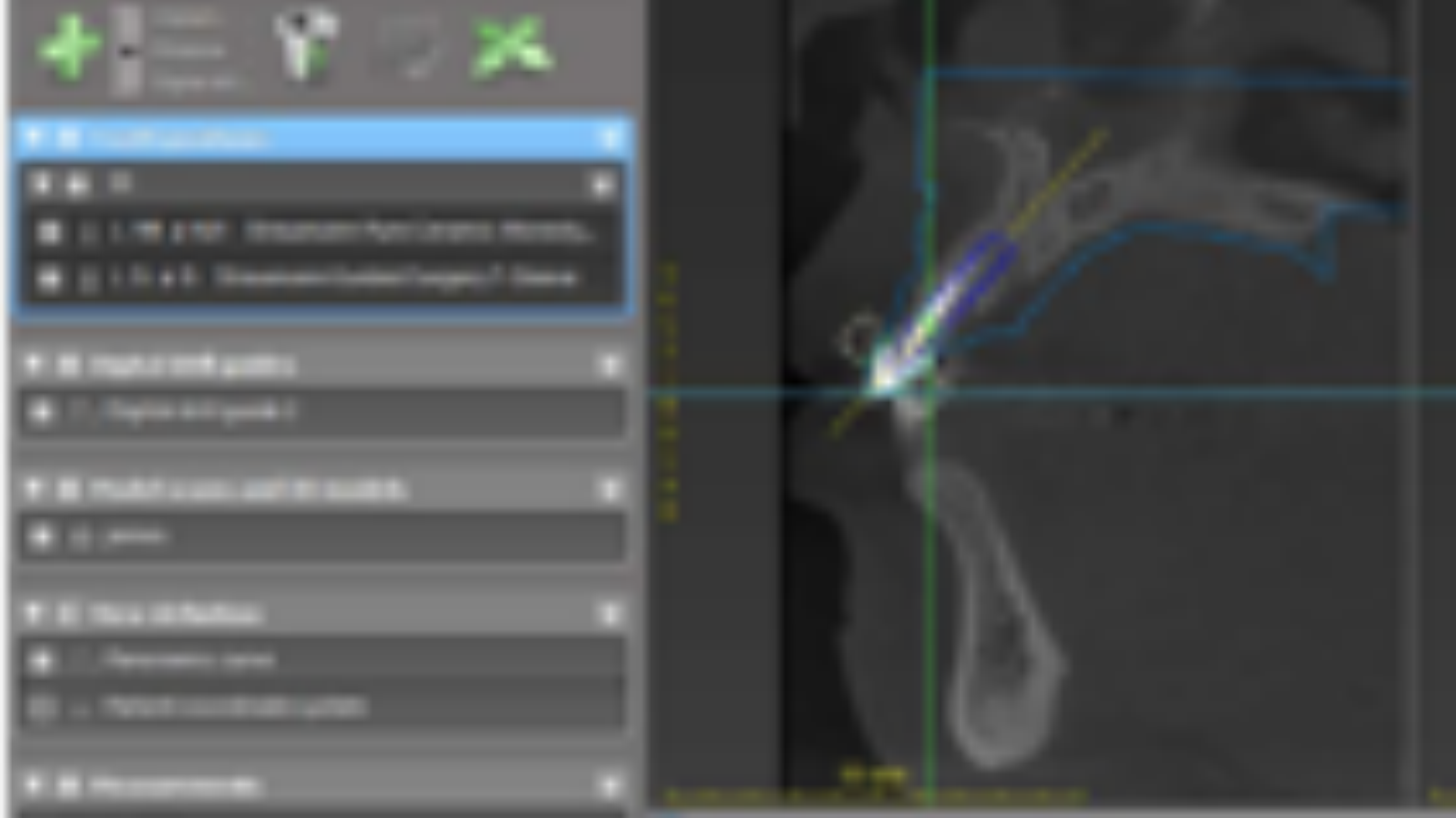


ZIRCONIA IMPLANTS LIMITATIONS

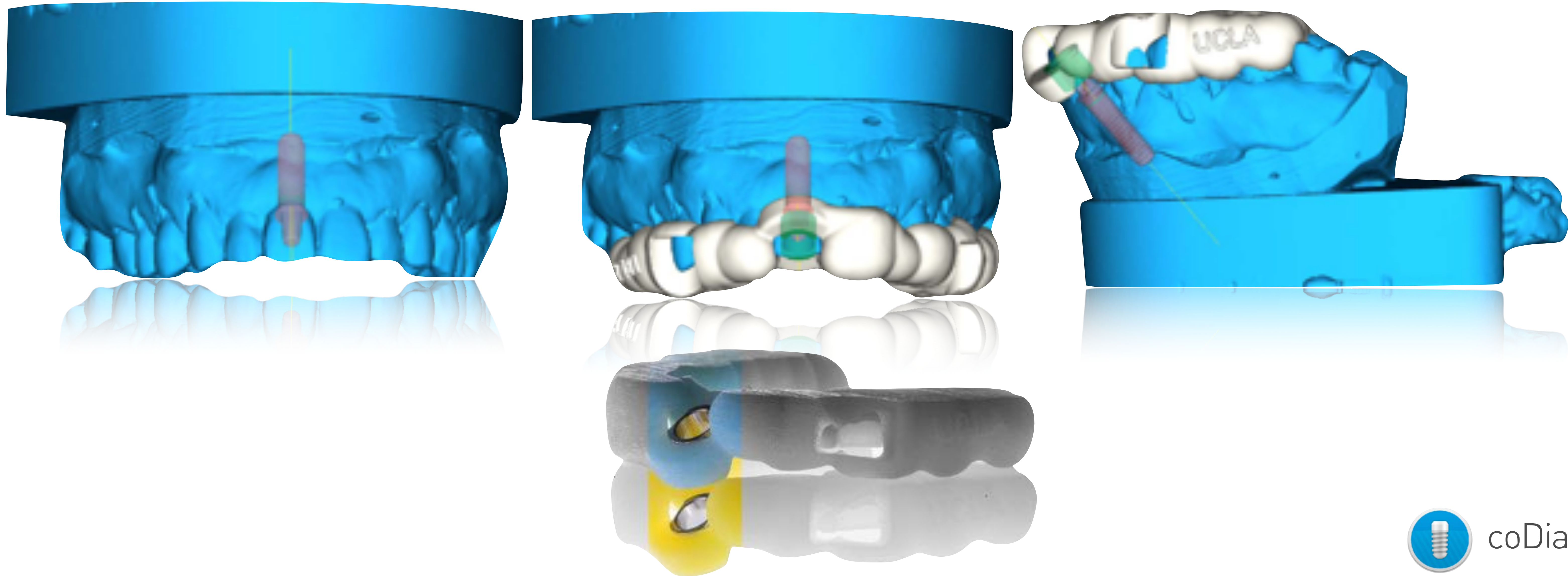
- surgical precision
- margin placement
- one piece, non-submerged
- primary stability
- grafting
- multiple units

surgical

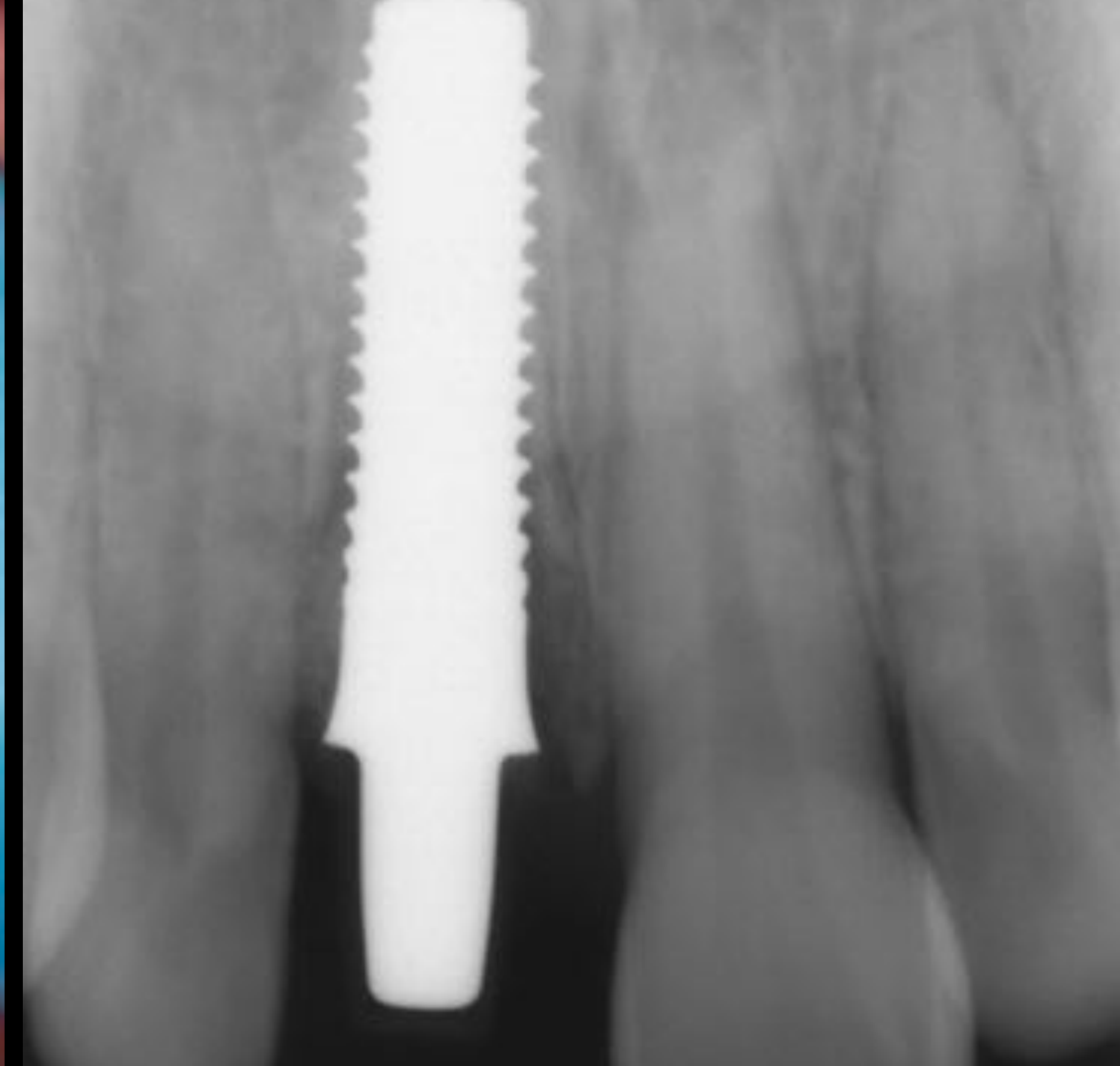
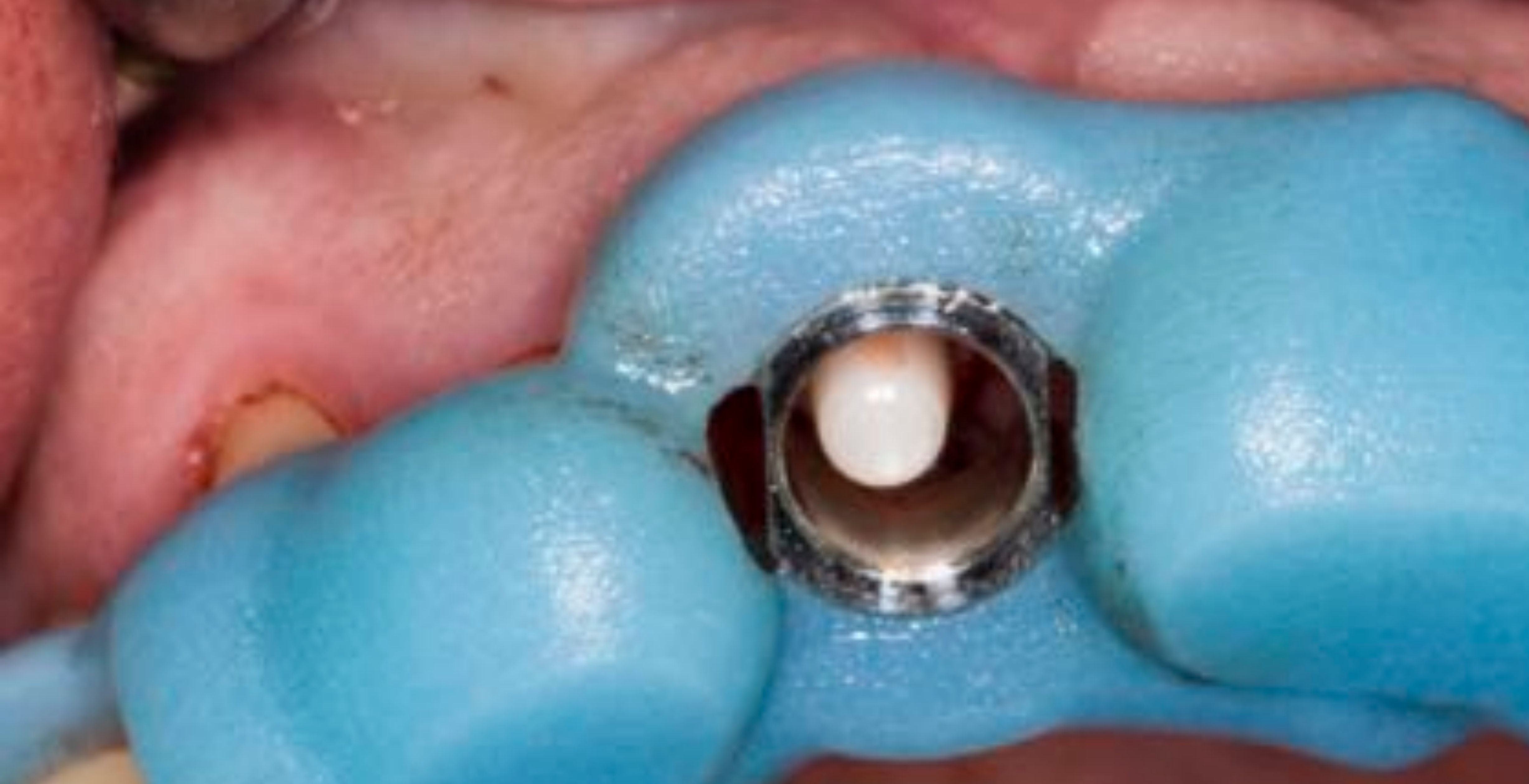


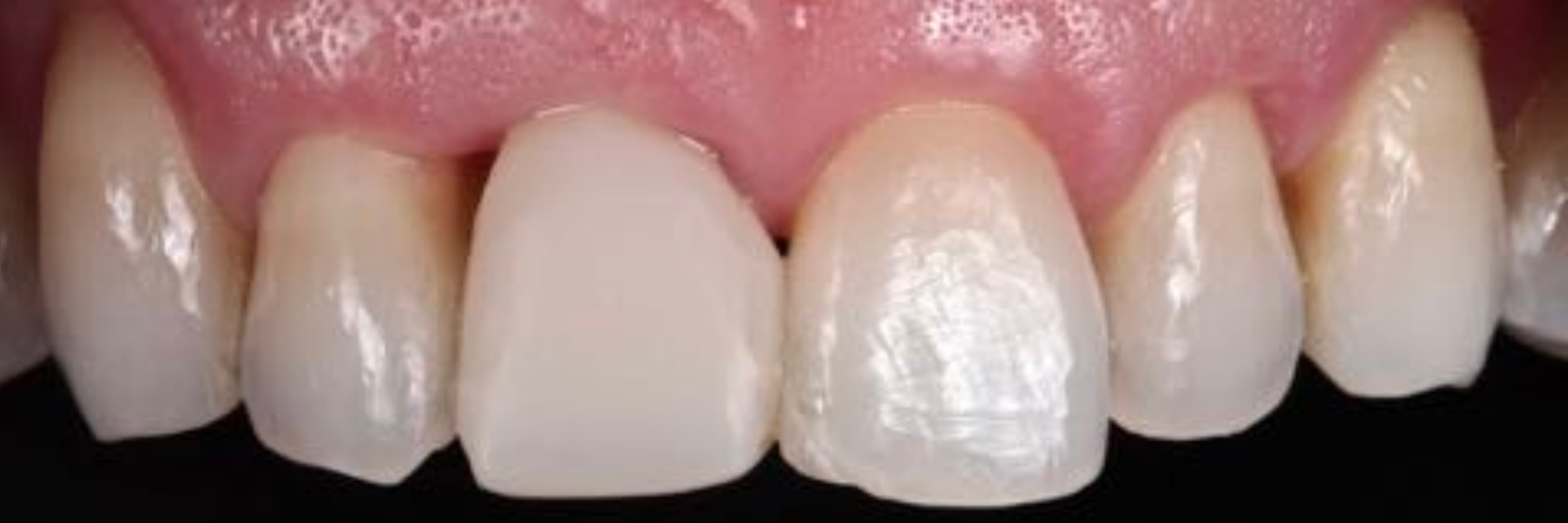
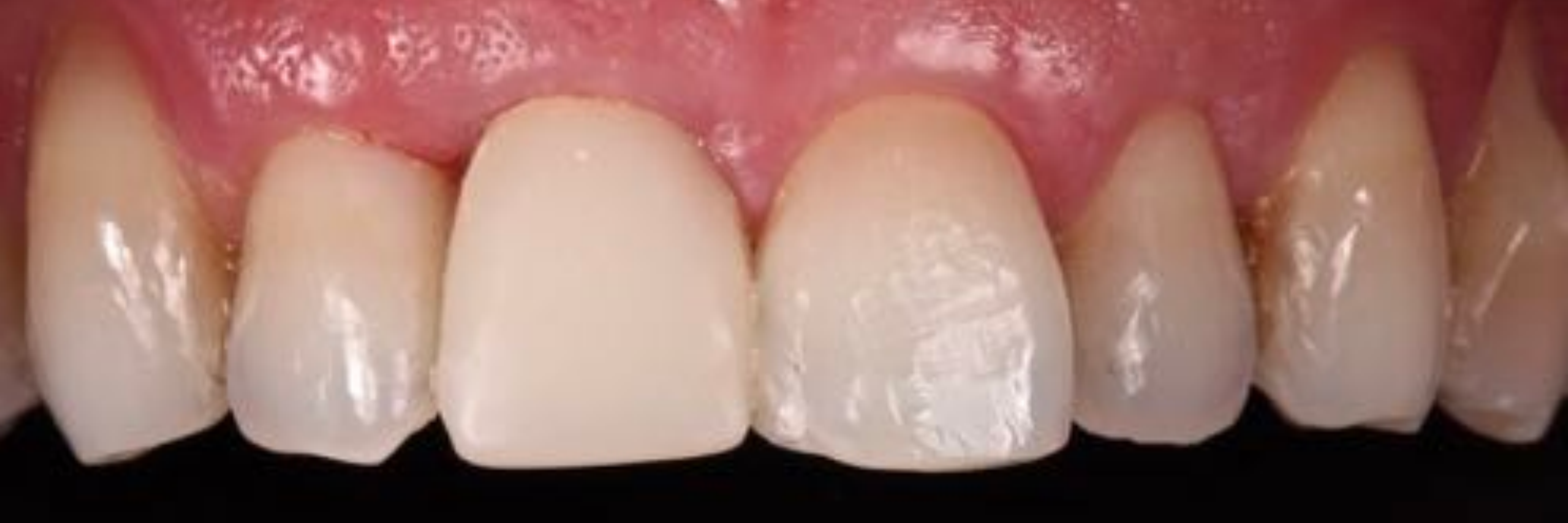coDiagnostiXTM

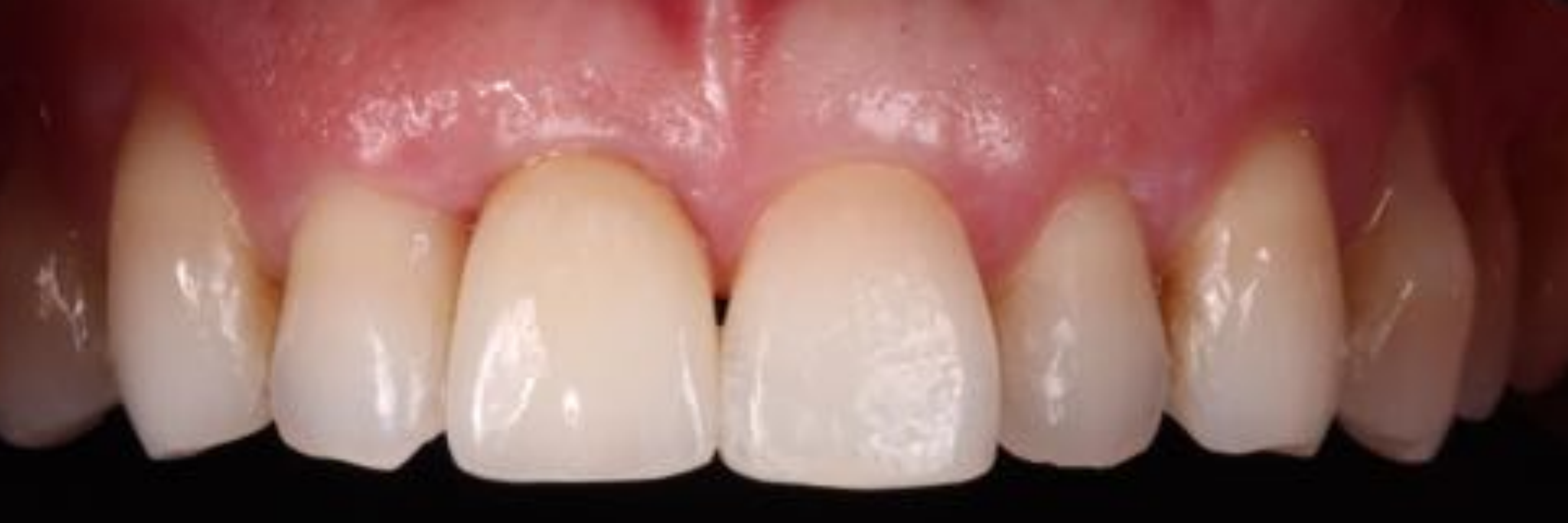

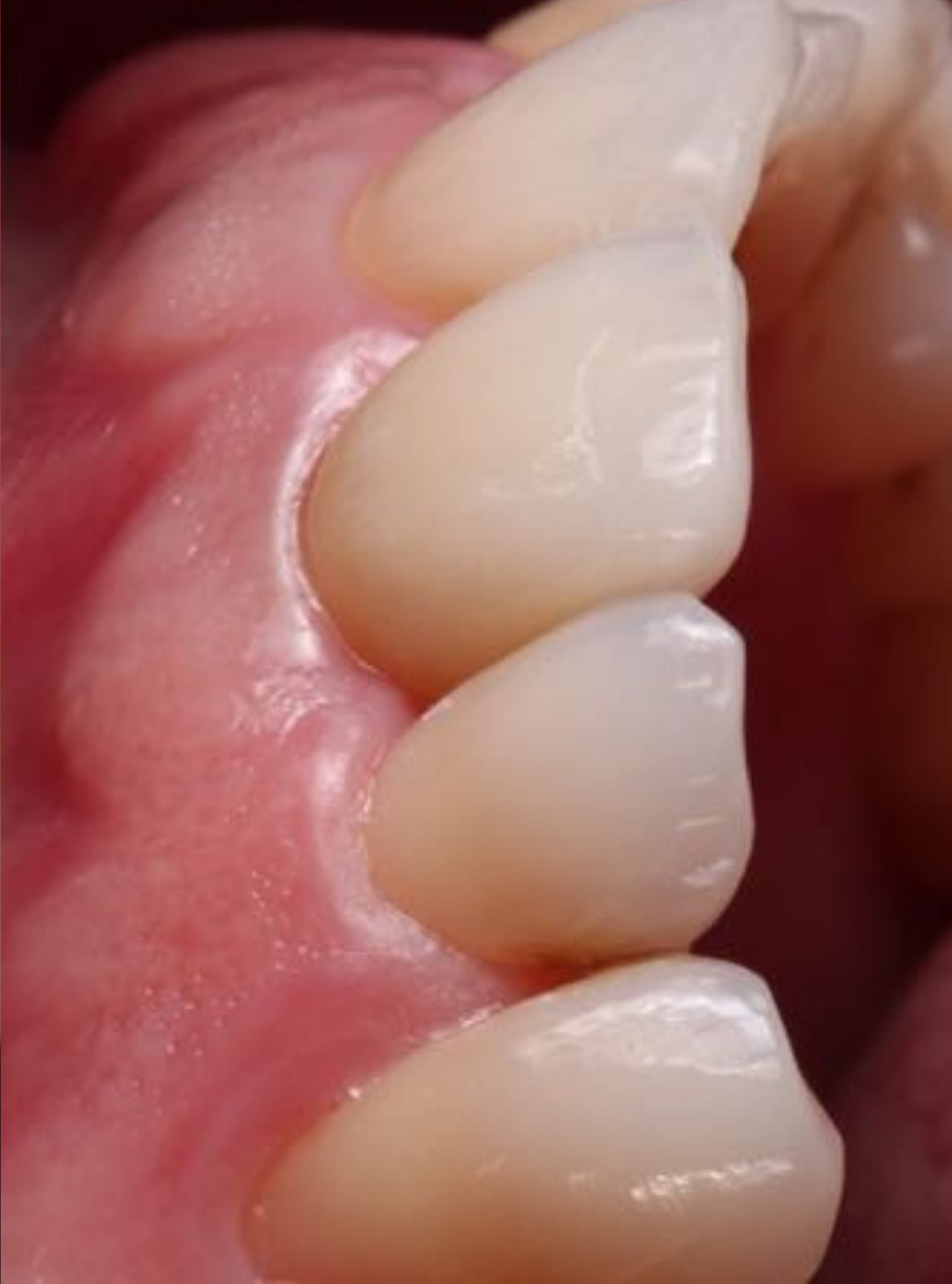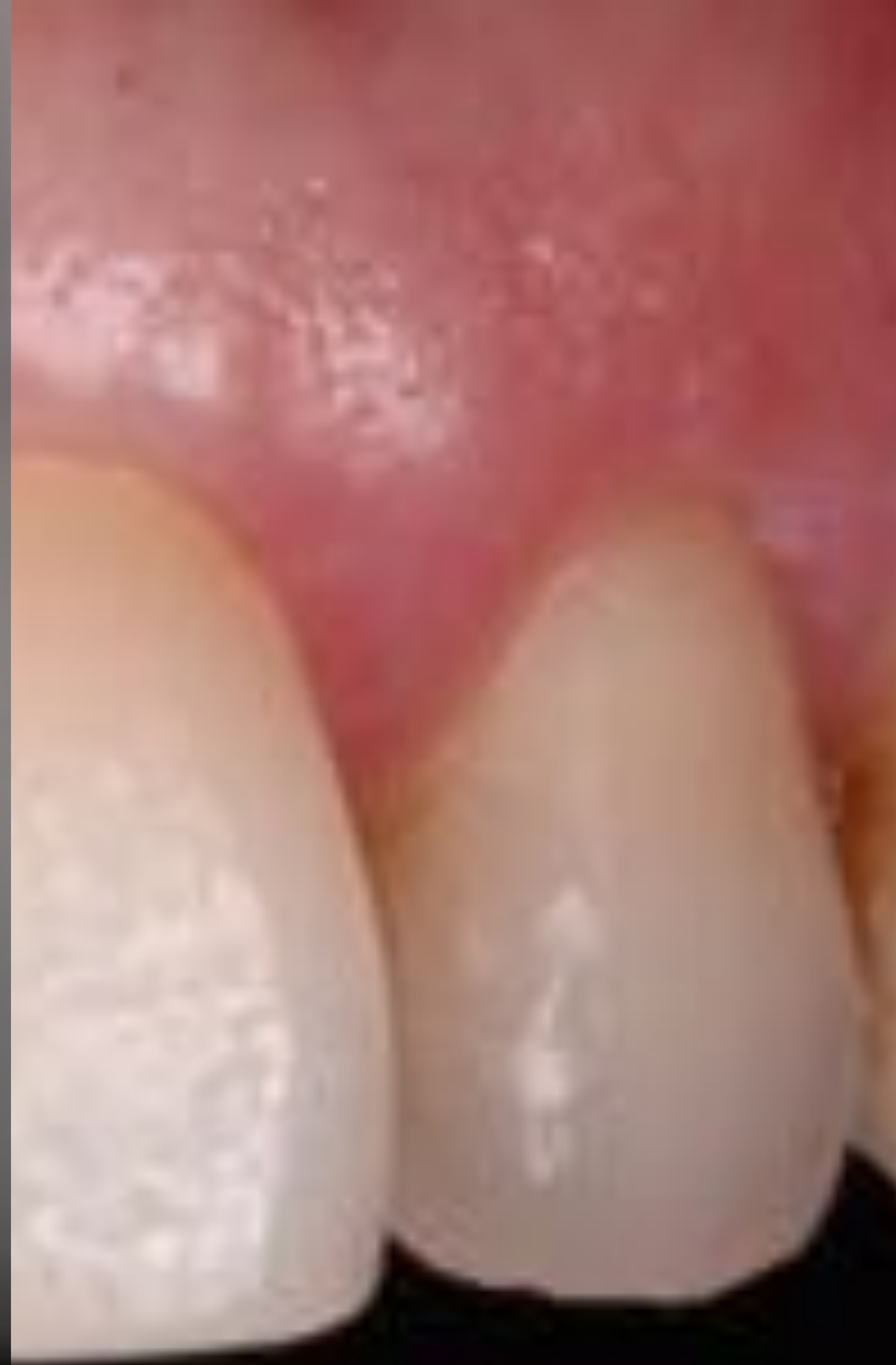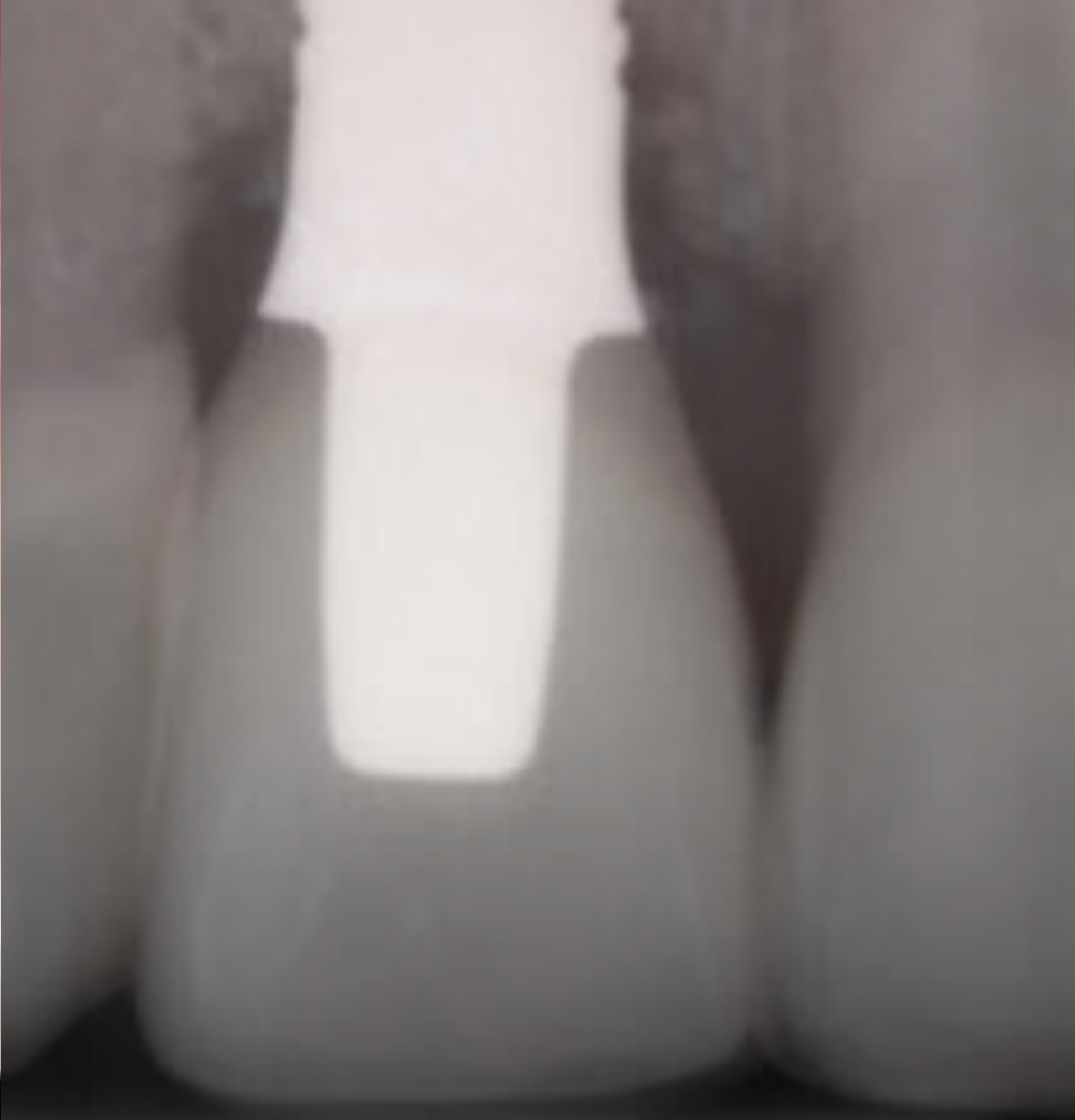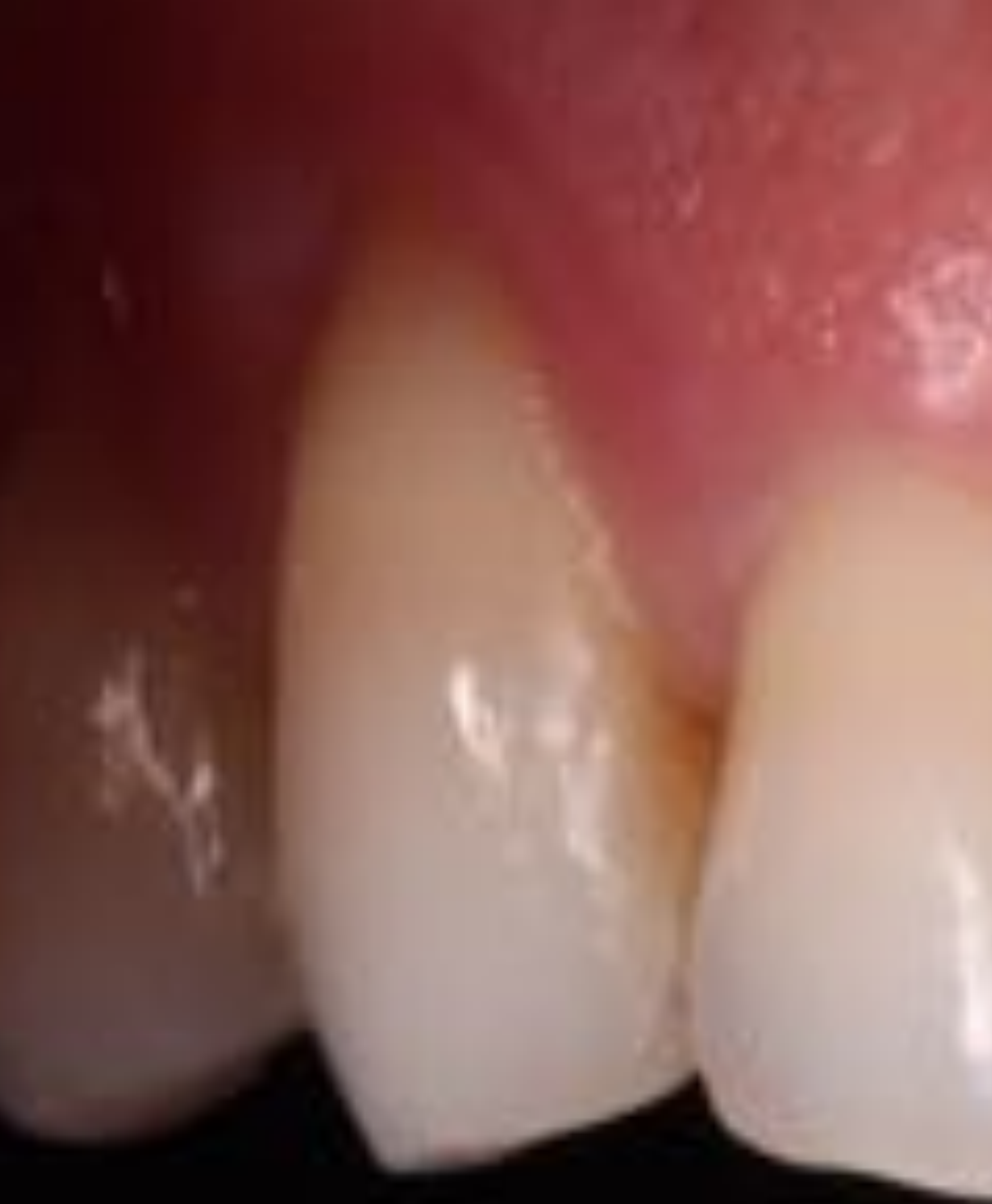coDiagnostiX™





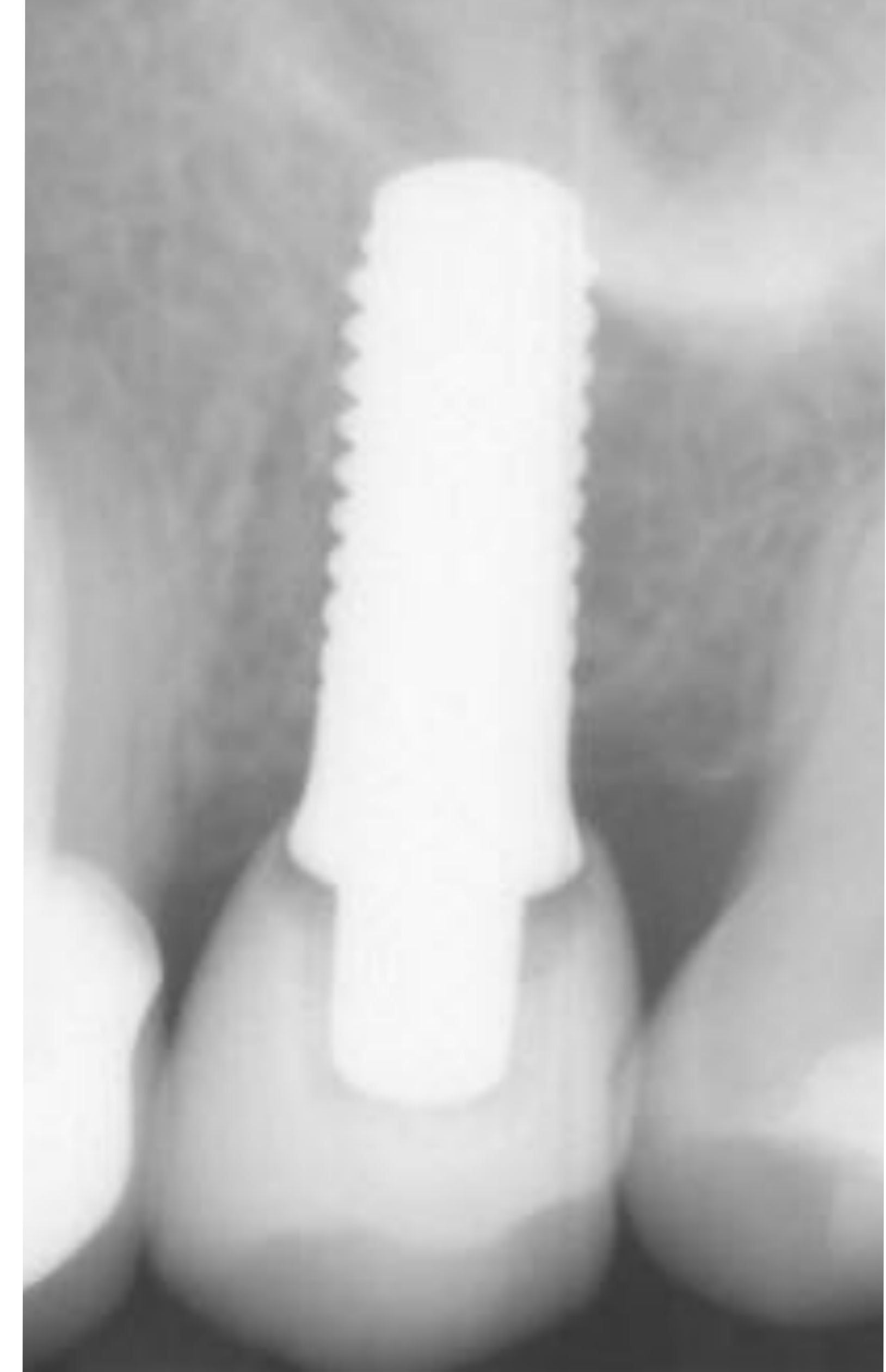





ZIRCONIA IMPLANTS LIMITATIONS

prosthetic



ZIRCONIA IMPLANTS LIMITATIONS

- cement-retained

prosthetic



ZIRCONIA IMPLANTS LIMITATIONS

- cement-retained
- mesial and distal margin control

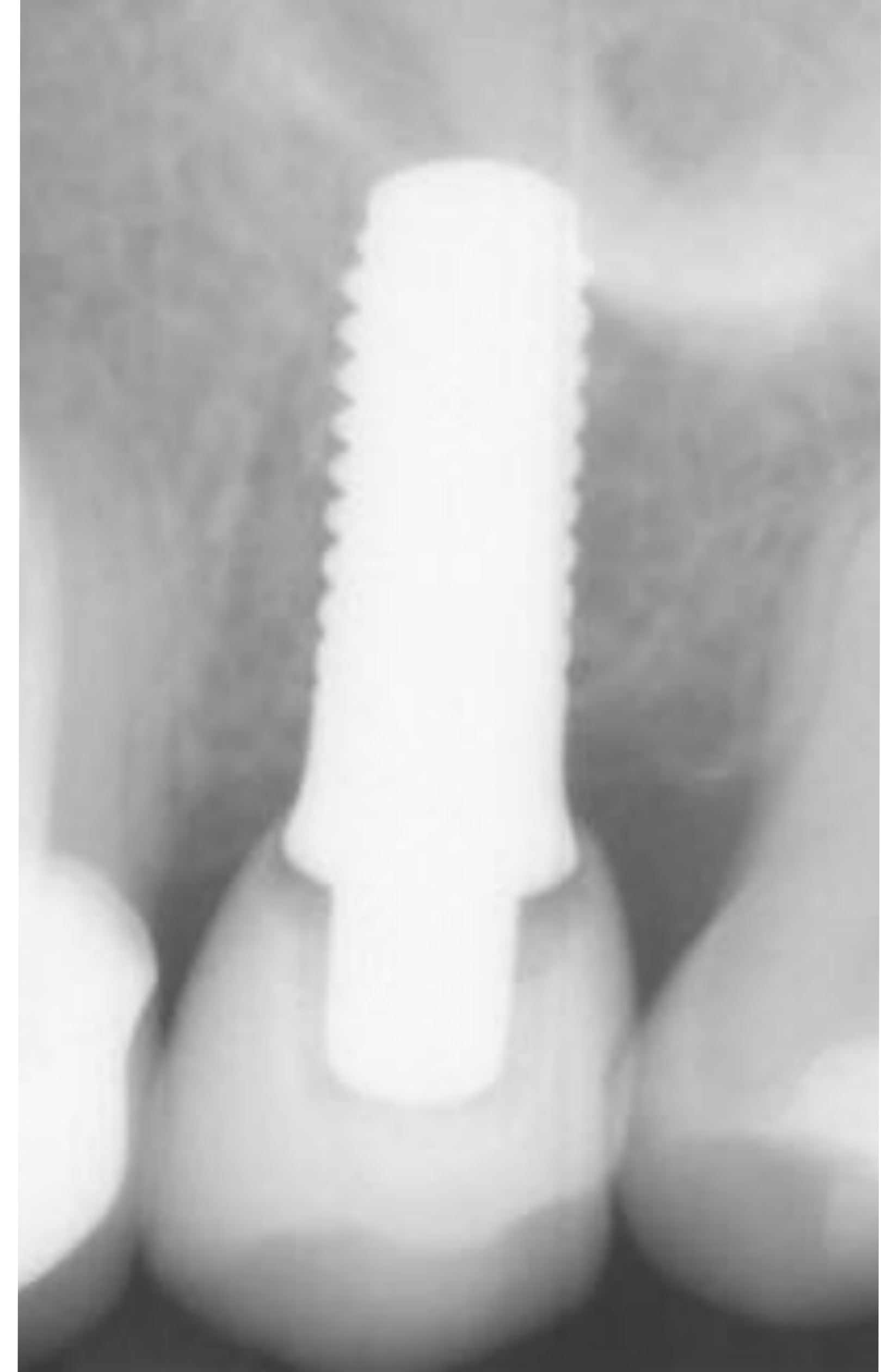prosthetic



ZIRCONIA IMPLANTS LIMITATIONS

- cement-retained
- mesial and distal margin control
- emergence profile

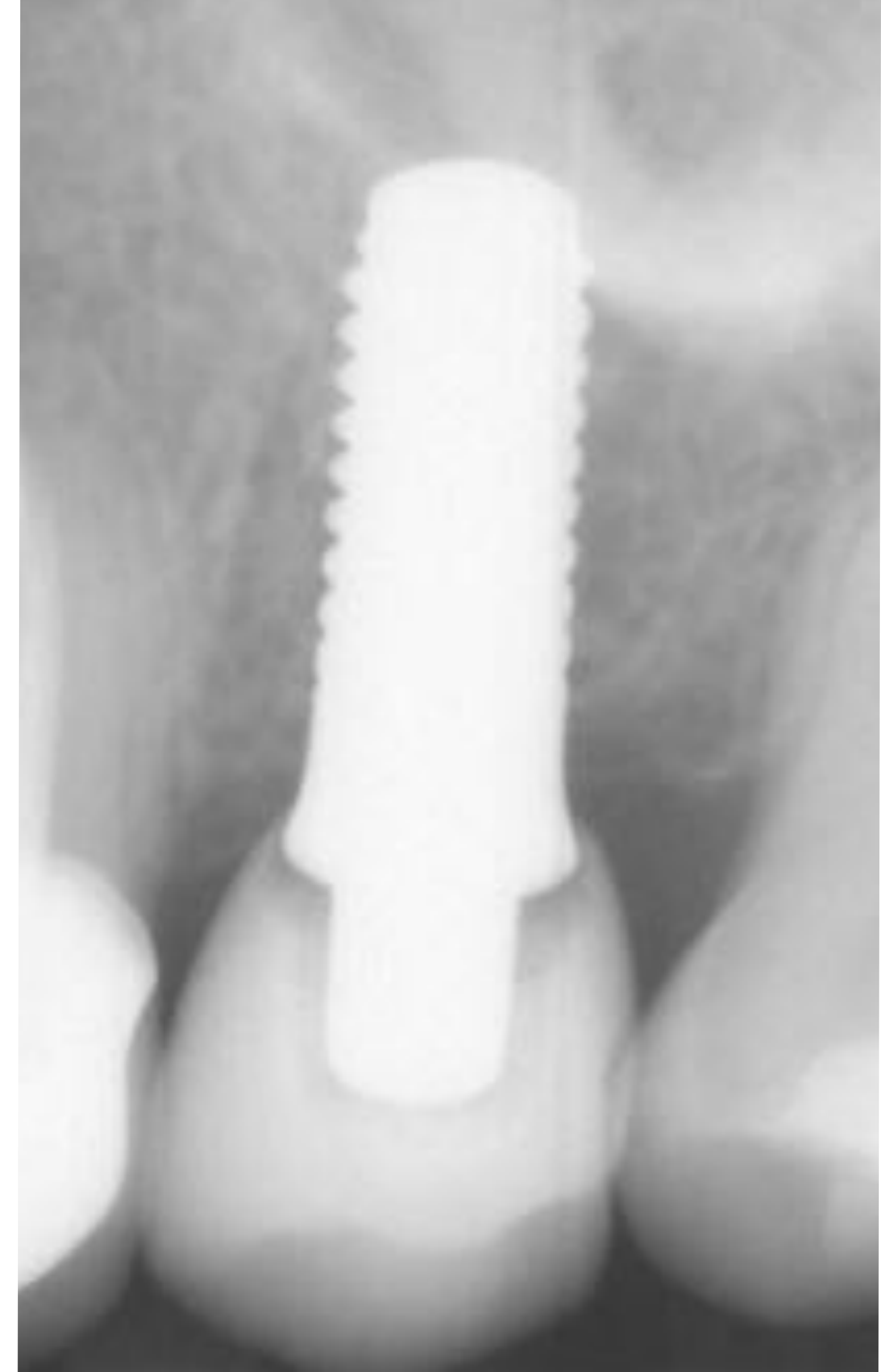
prosthetic



ZIRCONIA IMPLANTS LIMITATIONS

- cement-retained
- mesial and distal margin control
- emergence profile
- **DO NOT PREP/MODIFY**

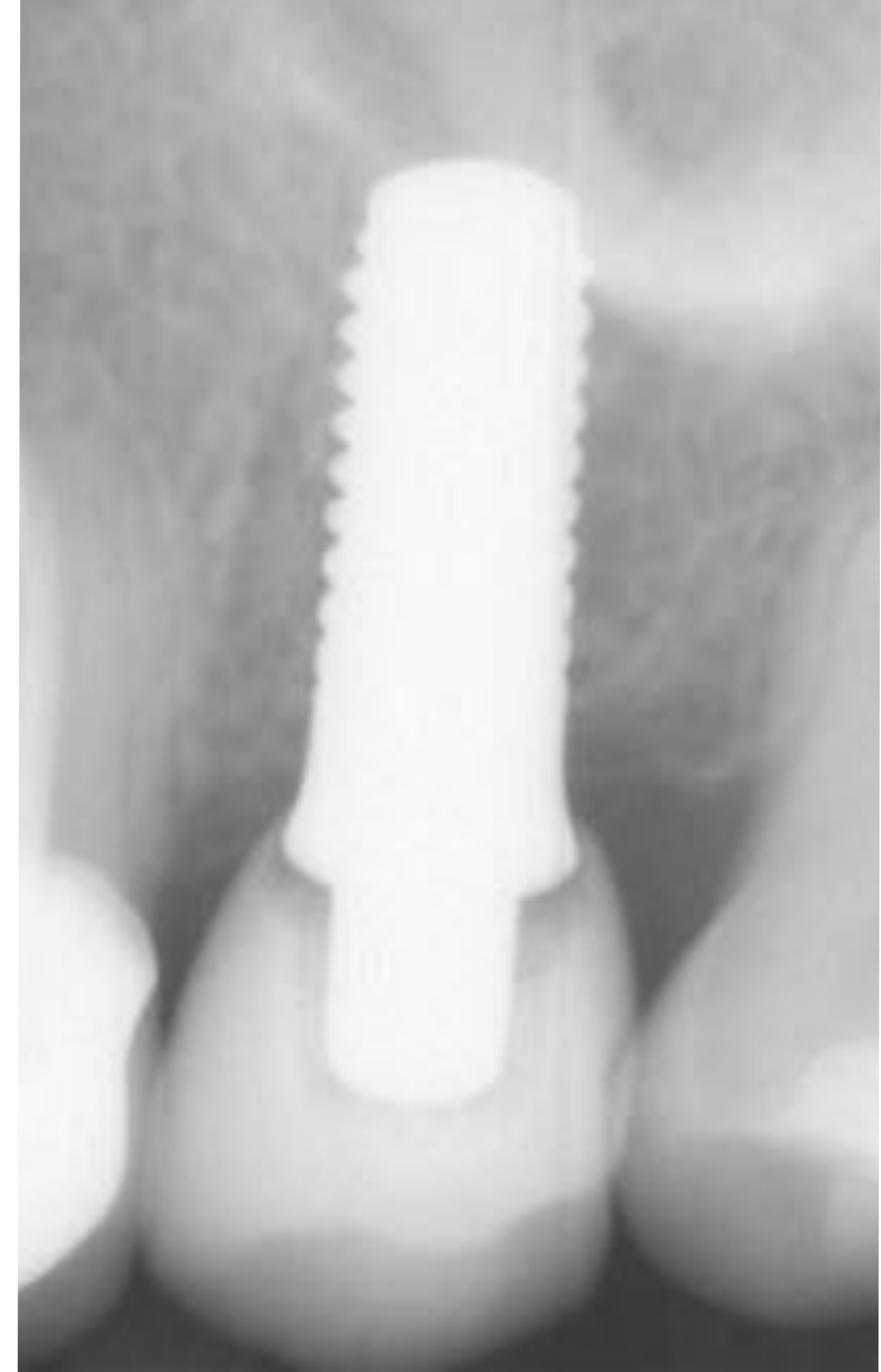
prosthetic



ZIRCONIA IMPLANTS LIMITATIONS

- cement-retained
- mesial and distal margin control
- emergence profile
- **DO NOT PREP/MODIFY**
- fixed/tooth borne provisional preferred

prosthetic



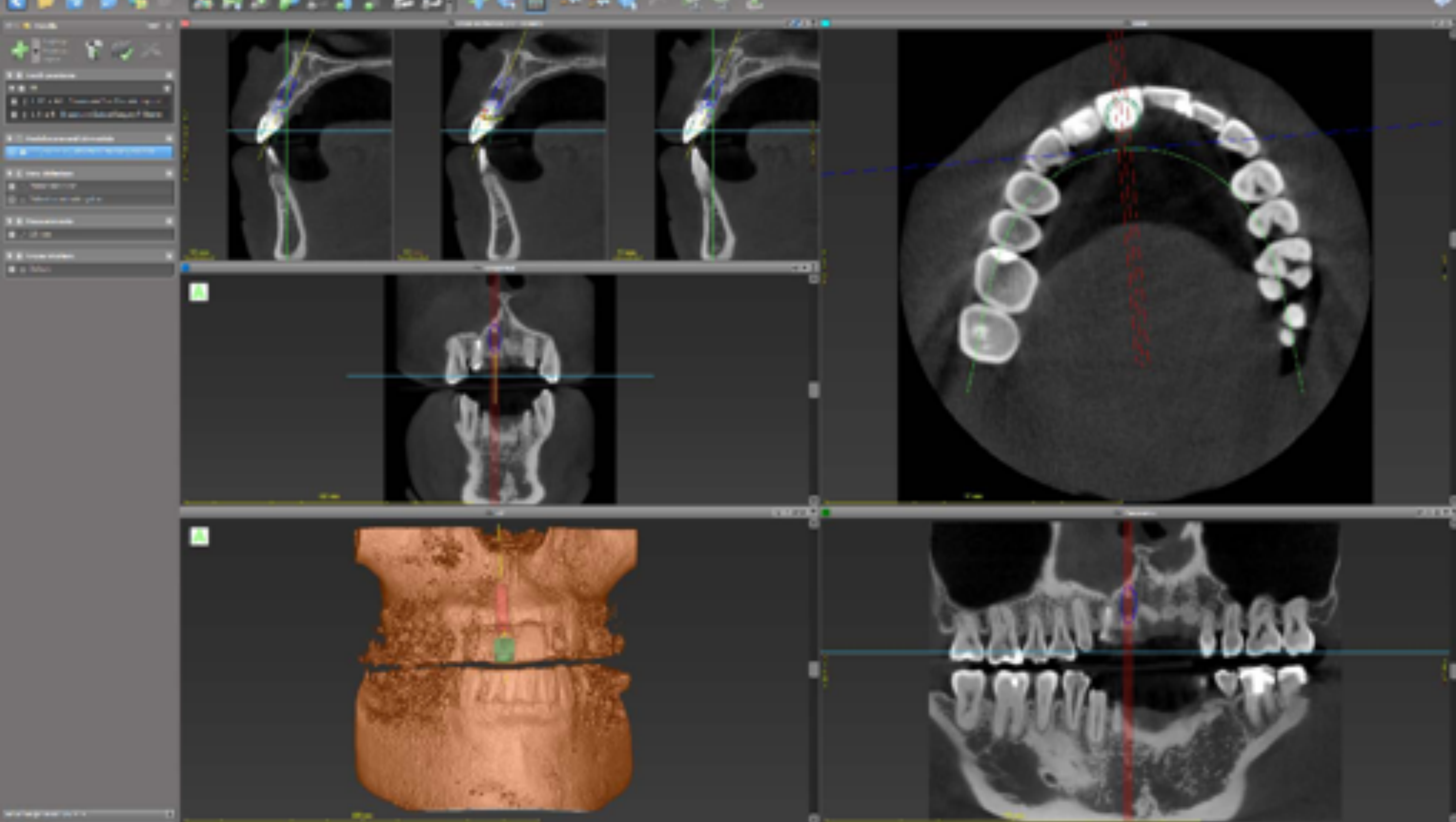


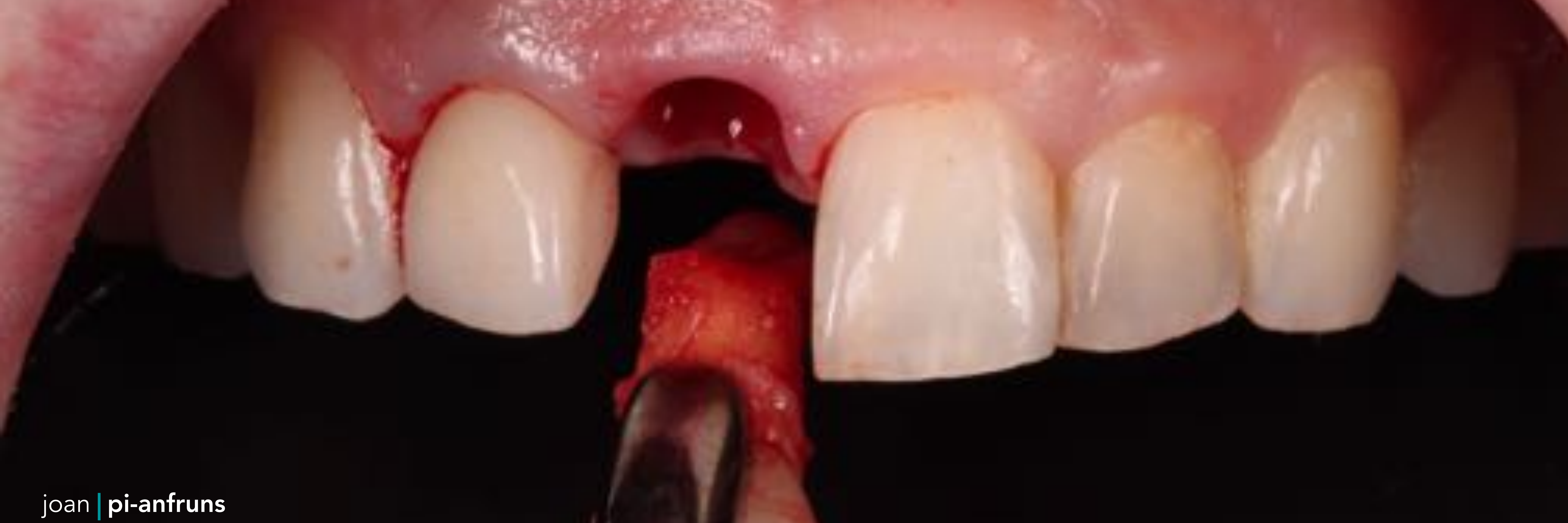


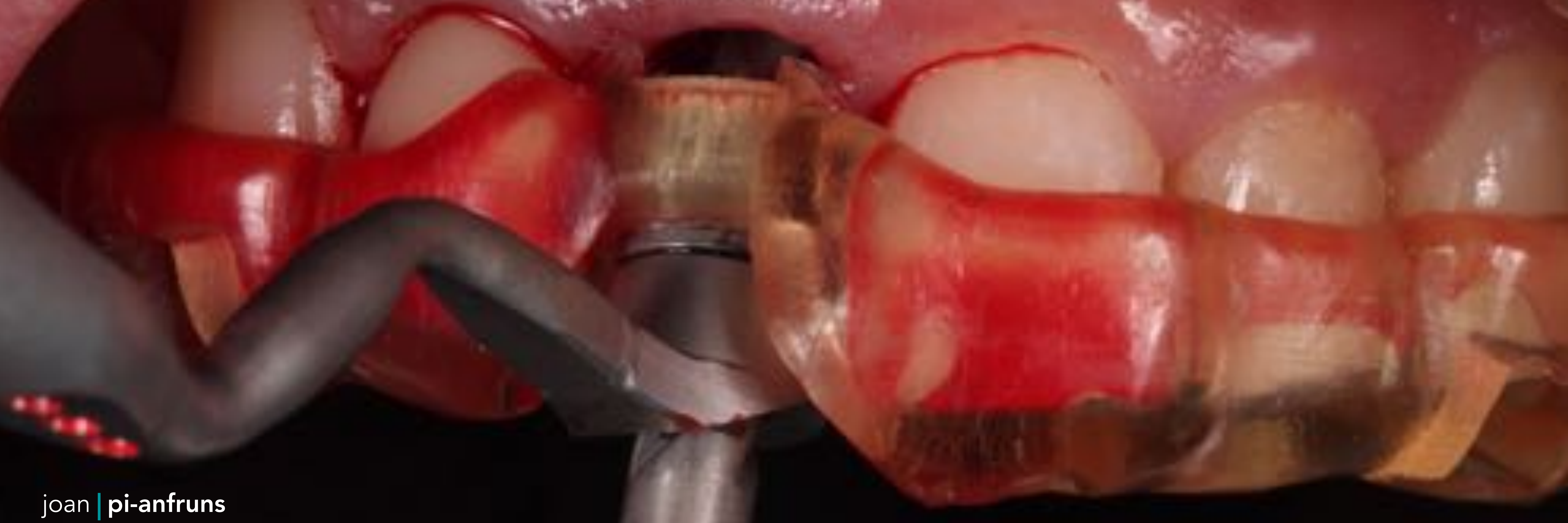
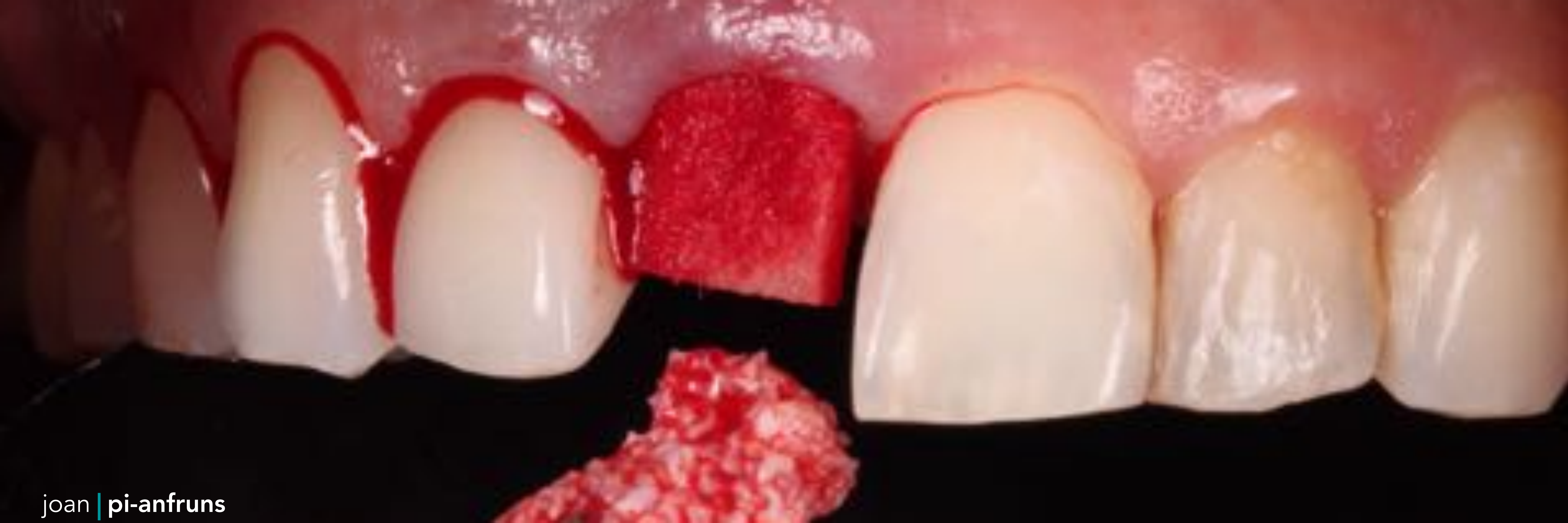
tim cook

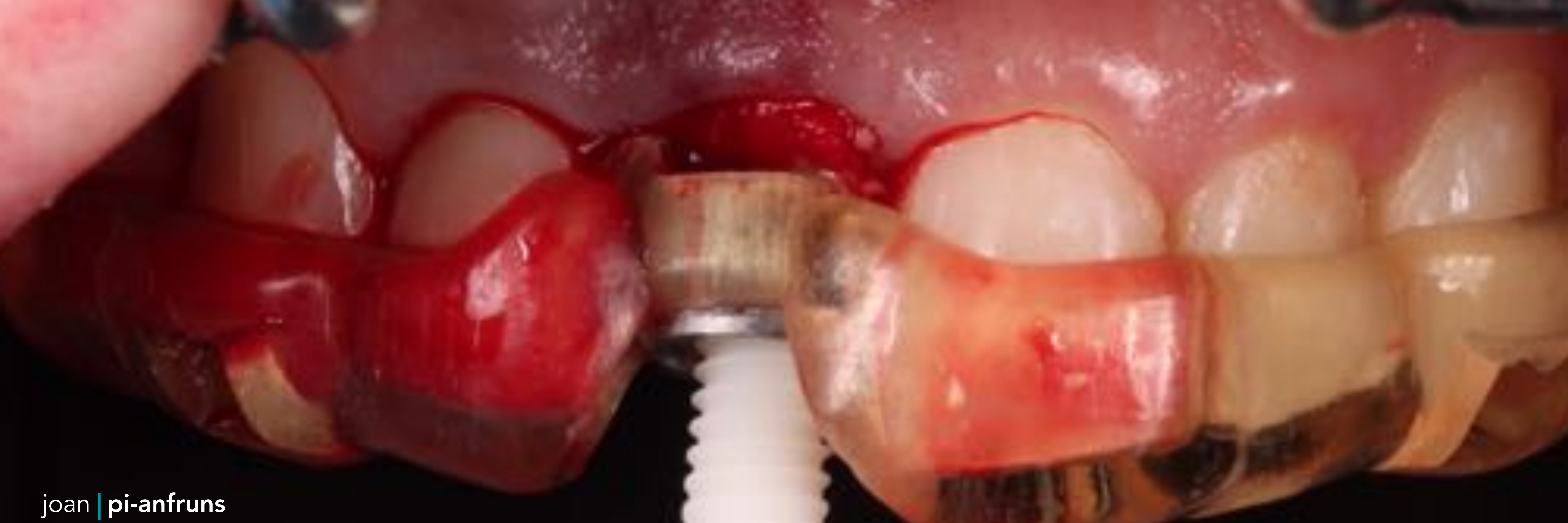


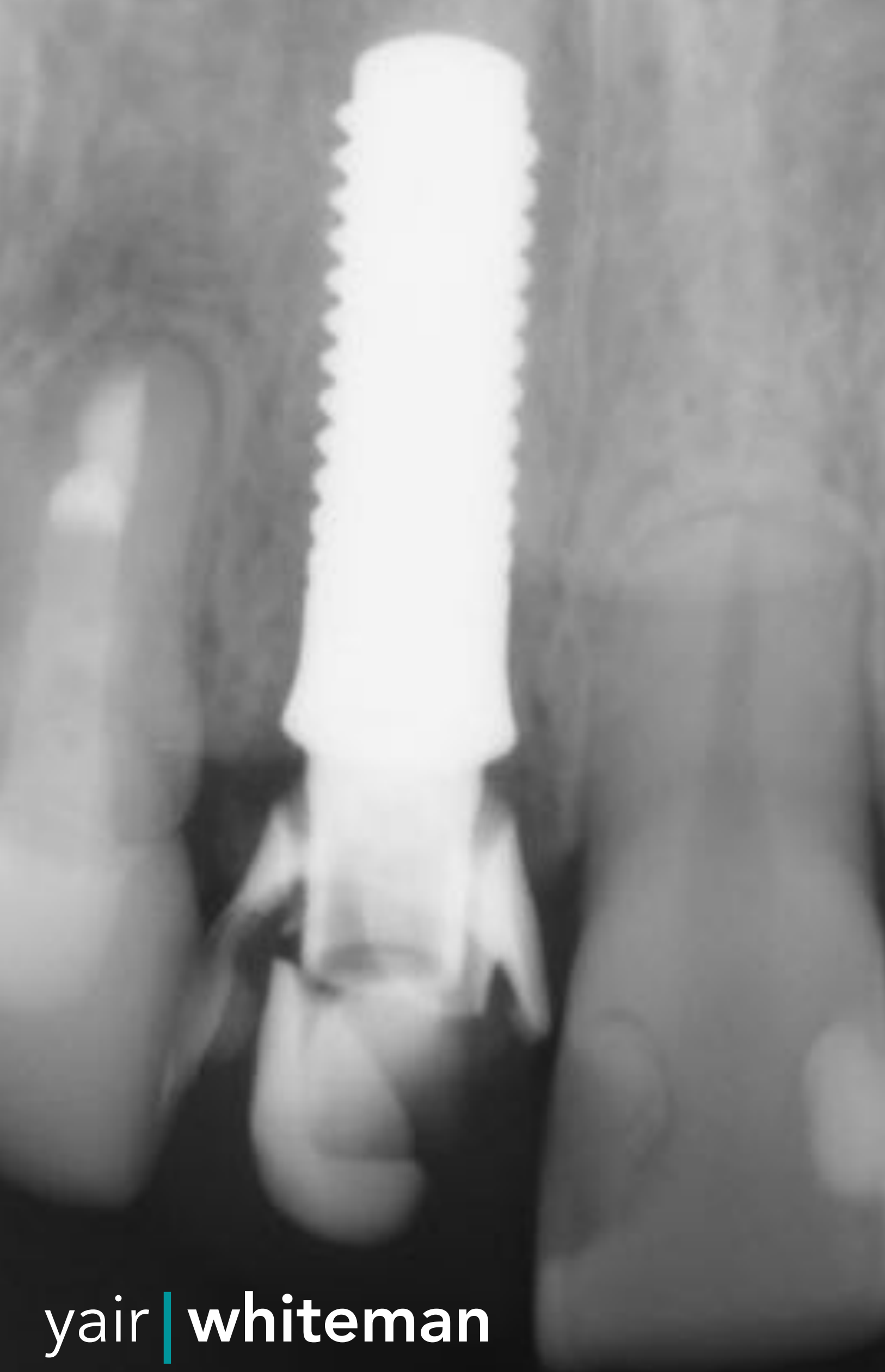




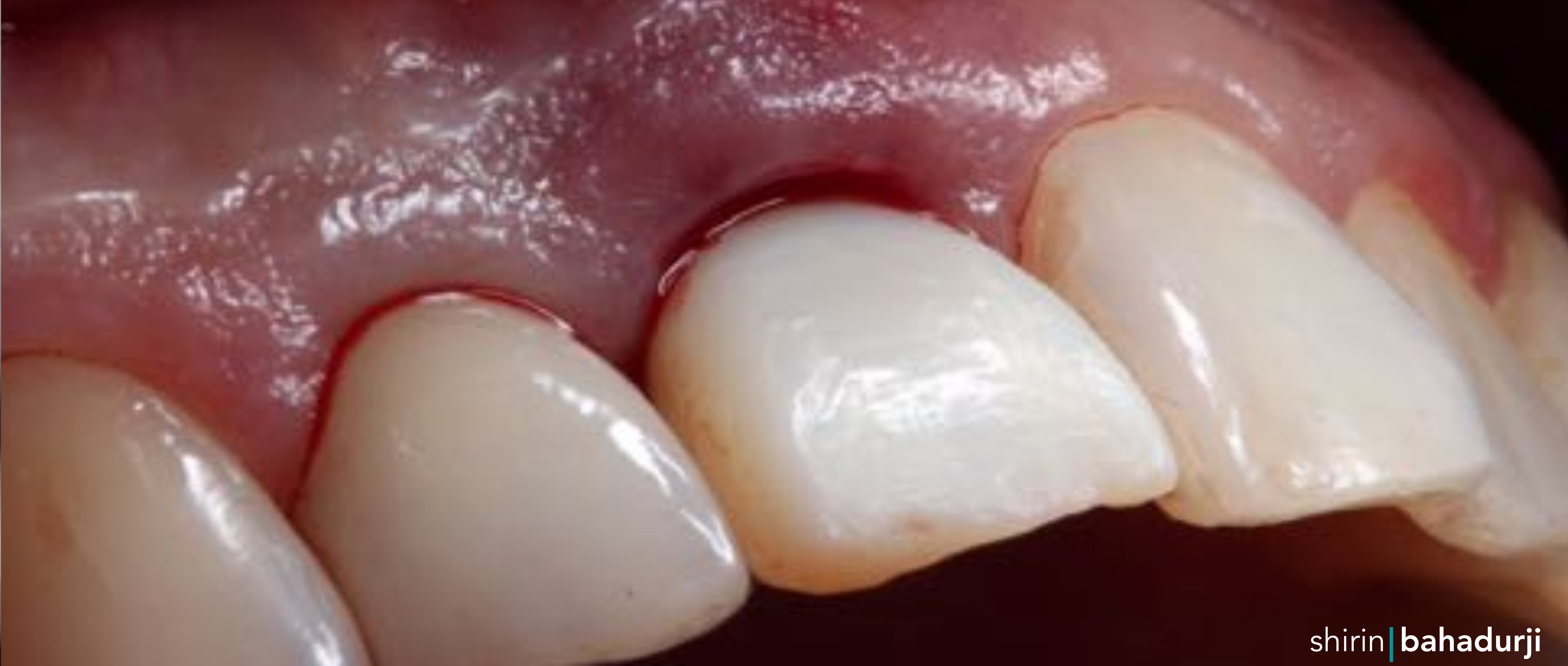



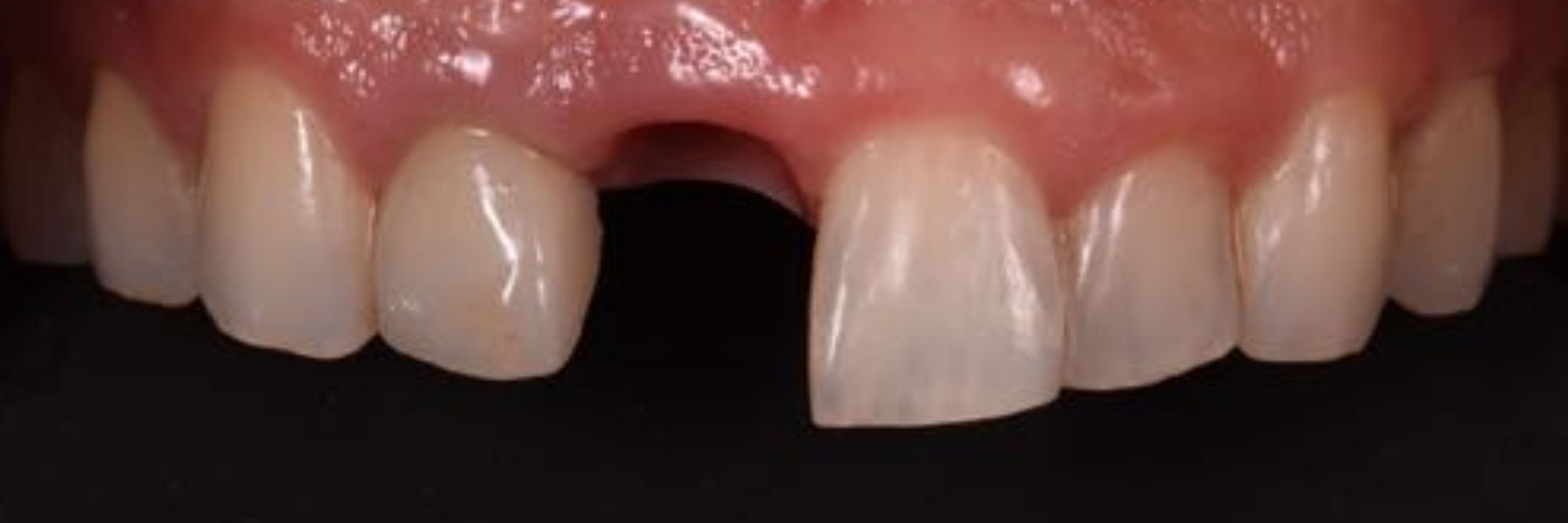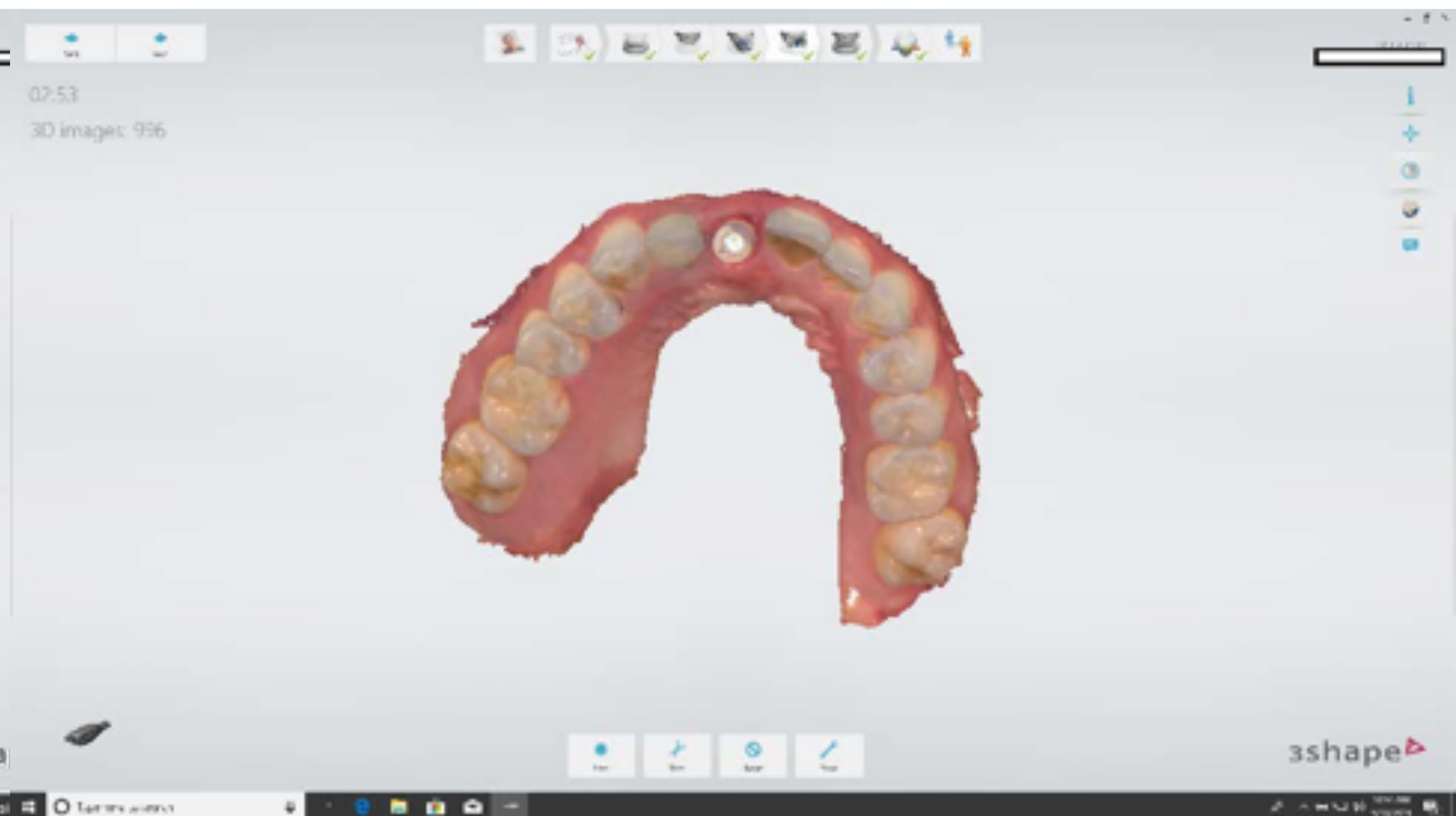
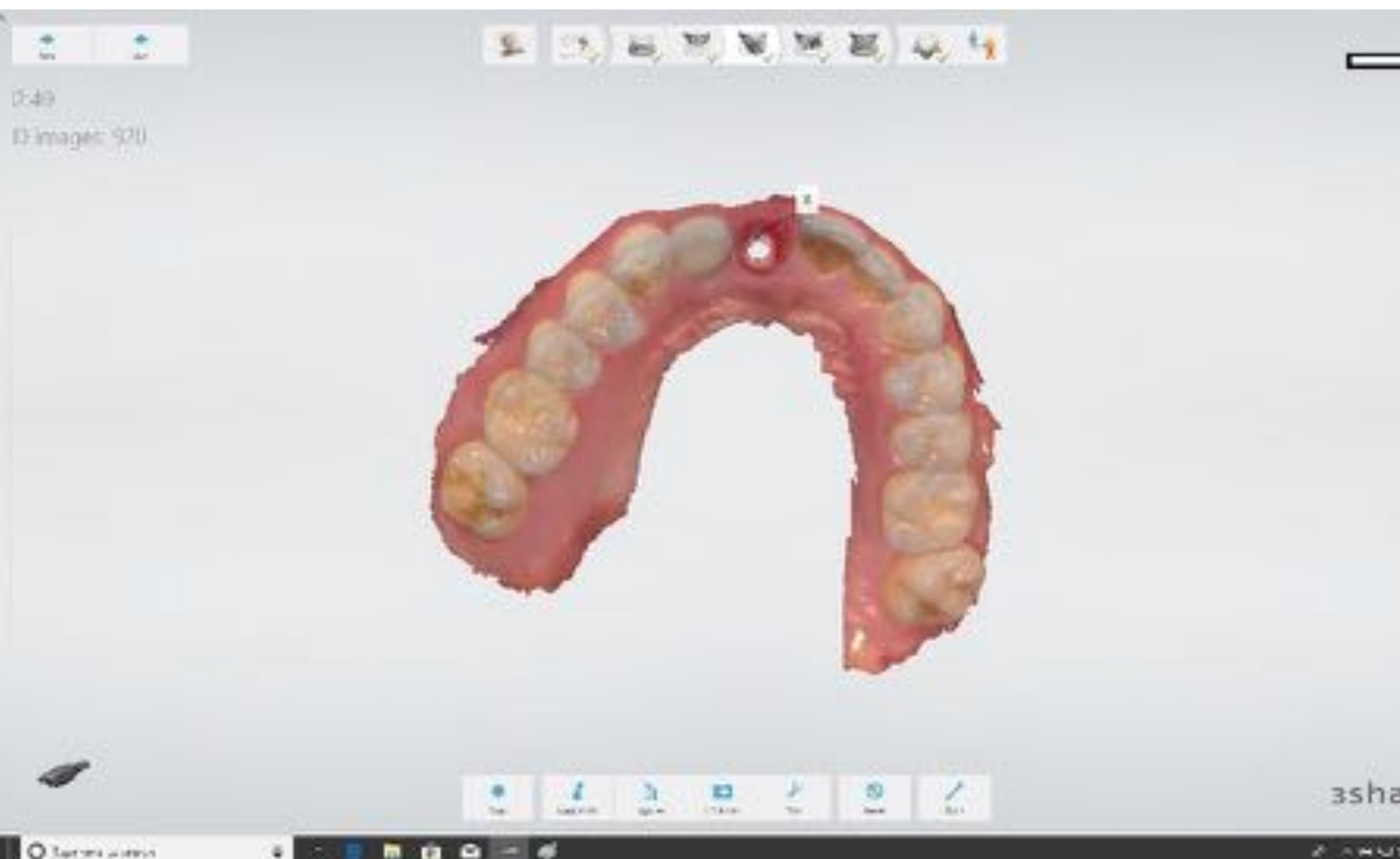
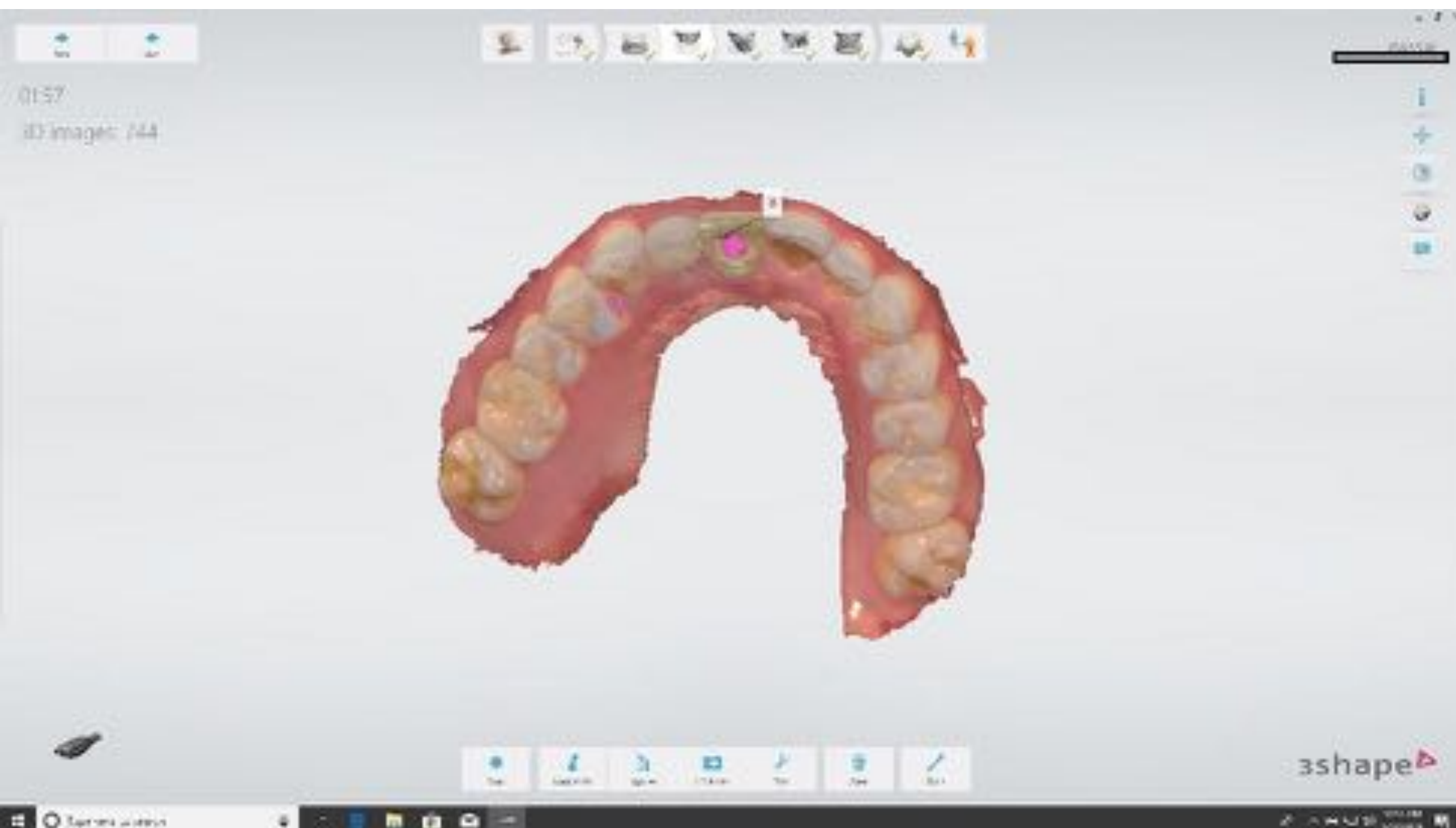


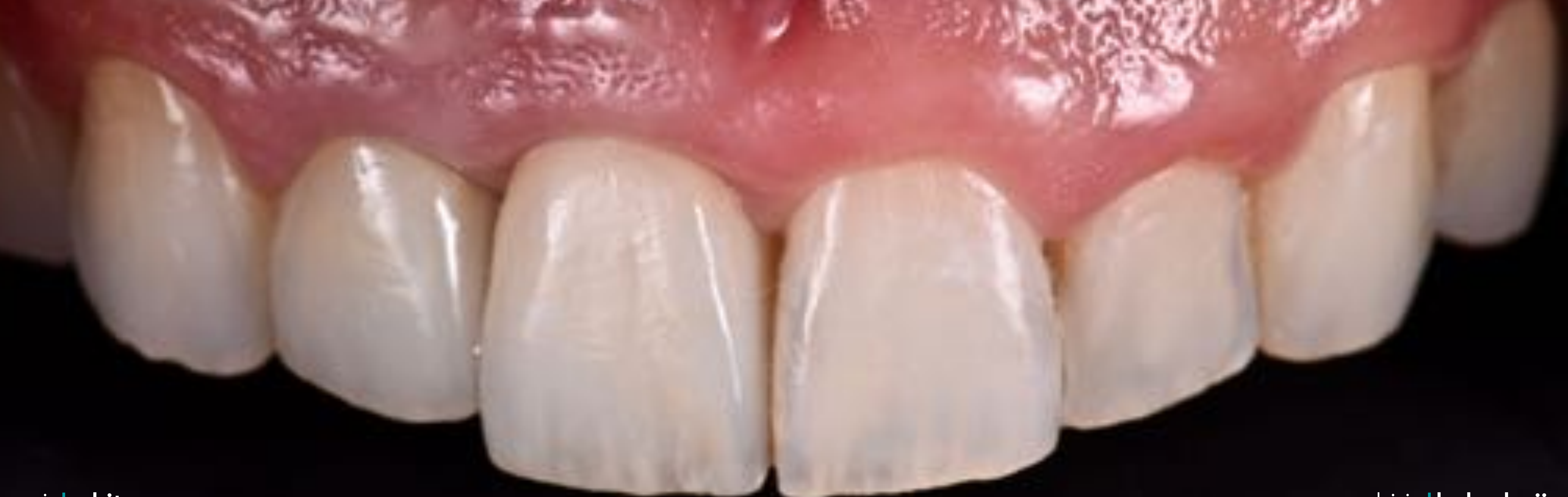yair | whiteman



shirin | bahadurji











ZIRCONIA IMPLANTS

UCLA

	TOTAL PLACED	FAILURES	COMPLICATIONS	OBSERVATION PERIOD
	16	1	1	6 YEARS
	25	1	0	3 YEARS
	4	0	0	1 YEAR
	6	0	0	6 mo

59

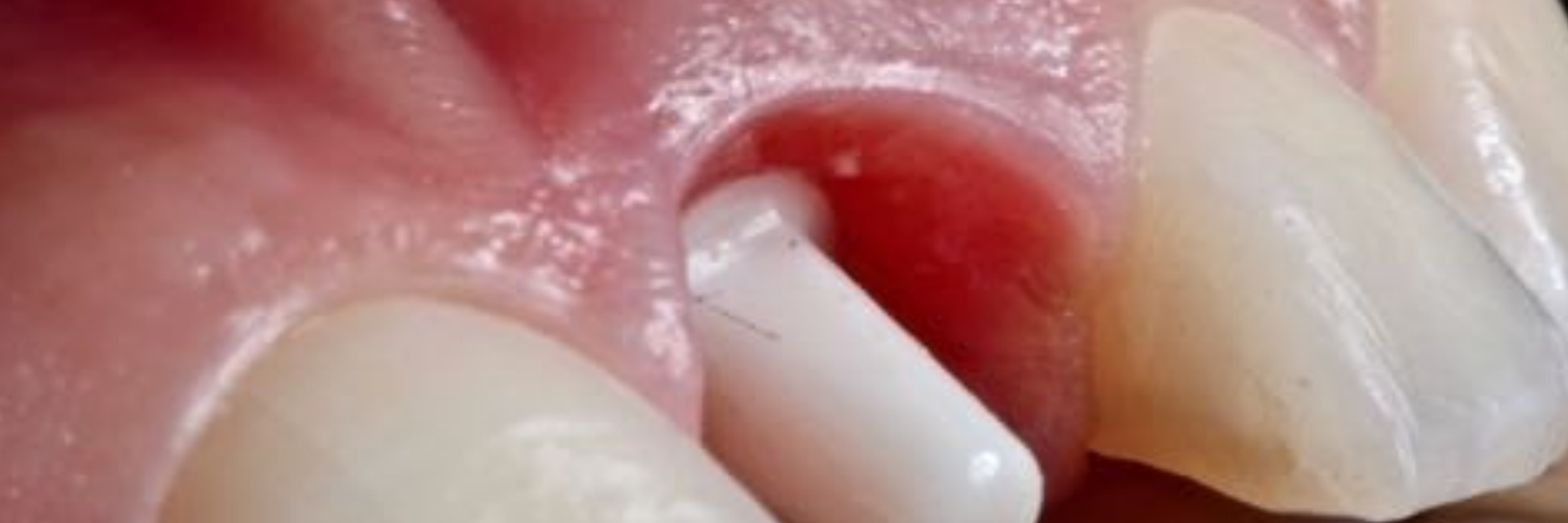ZIRCONIA IMPLANTS

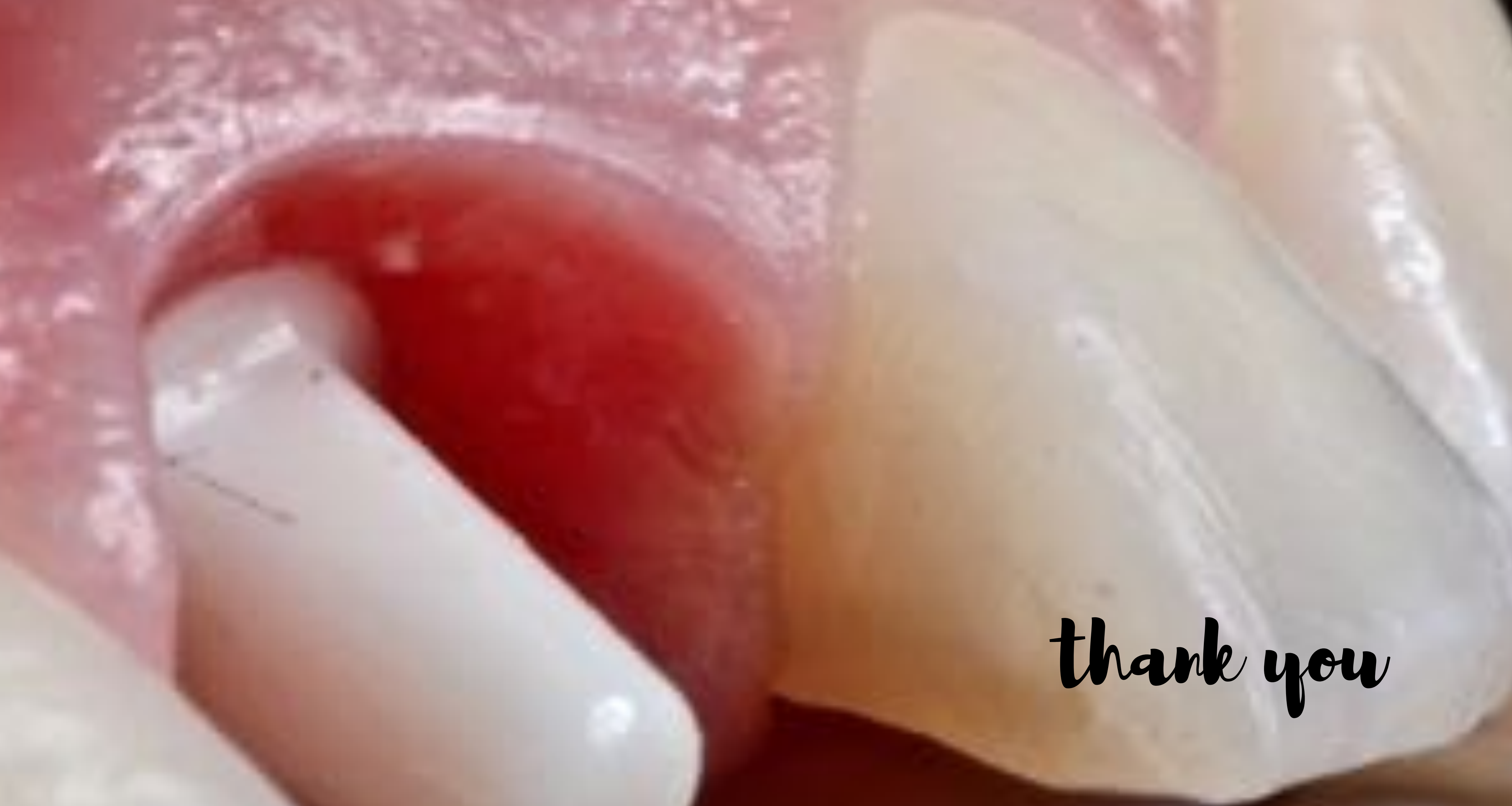
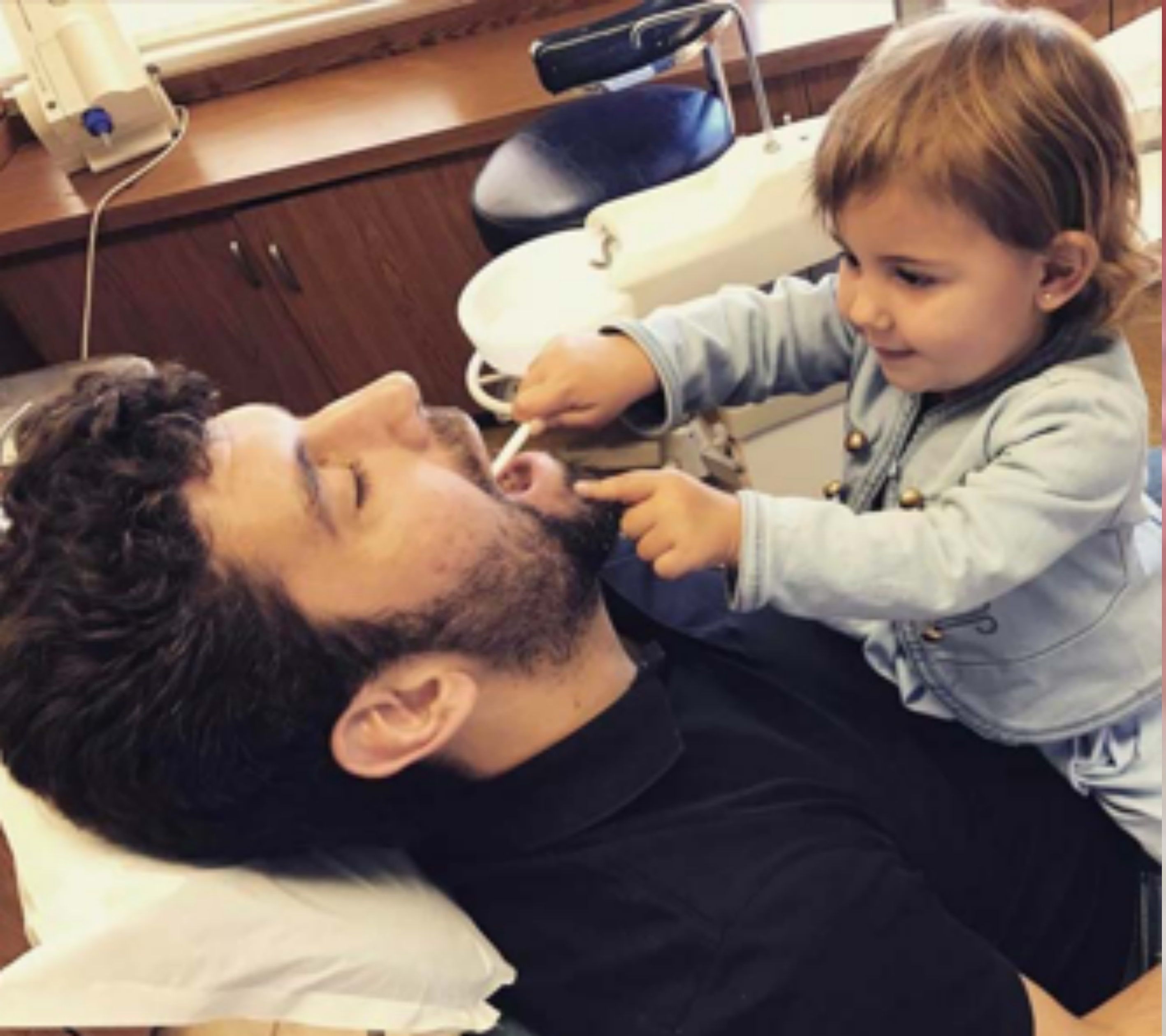
	TOTAL PLACED	FAILURES	COMPLICATIONS	OBSERVATION PERIOD
	16	1	1	6 YEARS
	25	1	0	3 YEARS
	4	0	0	1 YEAR
	6	0	0	6 mo

59

MBL of 0.59mm ± 0.34mm





thank you