



2016 CDA Presents in Anaheim

Anatomy of the Masticatory System

Henry A. Gremillion, DDS
M. Franklin Dolwick, DMD, PhD

Thursday, May 12, 2016

9:30 a.m.–noon

and continues 1:30–4 p.m.

Please visit the C.E. Pavilion to validate your course attendance

Or

“If There’s a Line – Go Online”

@ cdapresents.com

Please record your course code here _____.

Official Disclaimer

The California Dental Association’s CDA Presents is an educational and scientific meeting. No speaker or product has any endorsement, official or otherwise from the California Dental Association.

California Dental Association

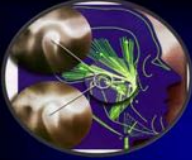
1201 K Street, 14th Floor
Sacramento, CA 95814

916.443.0505


800.232.7645

916.443.2943 fax

cda.org



Anatomy of the Head and Neck with Clinical Application




Henry A. Gremillion, DDS, MAGD
LSU School of Dentistry
May 16, 2014

Goals of Comprehensive Dentistry

- Optimum oral health
- Anatomic harmony
- Functional harmony
 - TM joints
 - musculature
 - occlusion
- Orthopedic stability

Chief concern


- bitemporal headache
- pain with jaw function
- sore teeth upon waking
- neck pain



Key Questions

- Should I treat this patient?
- What is/are the diagnosis(es)?
- How should I treat this patient?
- What factors are important in this case?

The Puzzle



Pain Pathways



The Many Faces of Pain

What We See

What We Don't See/Know!!!



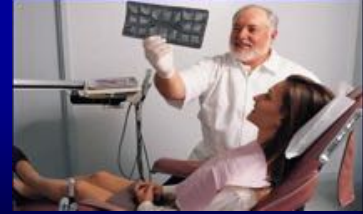Differential Diagnosis

The systematic consideration of the patient's signs and symptoms in order to distinguish one disease from another.



Differential Diagnosis

- Teeth
- Paranasal sinuses
- Otic
- Joint
- Muscle
- Vascular
- Neurogenous



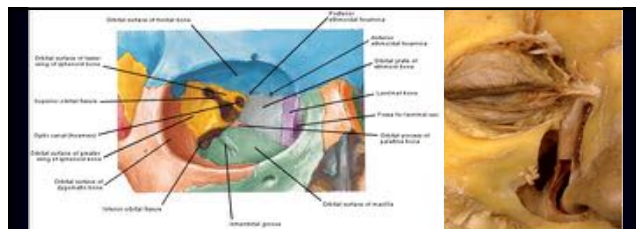
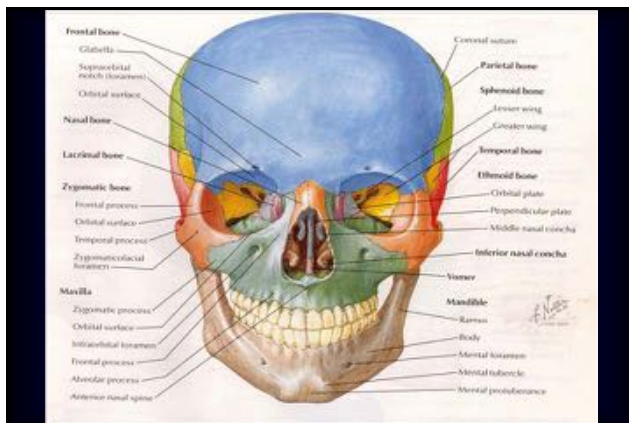
DIAGNOSIS IS THE KEY!

Must Consider:

- anatomy
- physiology
- neurology
- psychology



Osteology Anatomy of the Skull

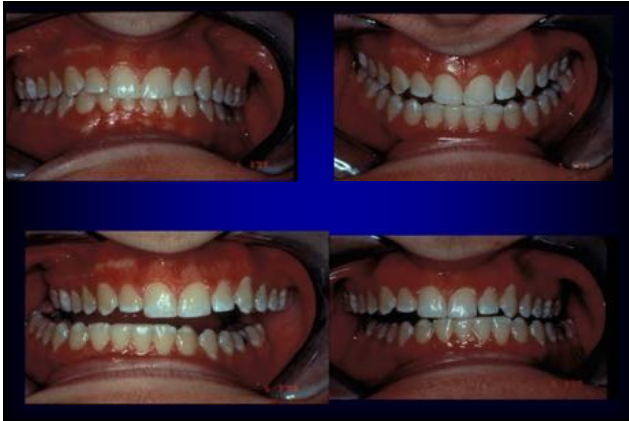

Supraorbital foramen- supraorbital nerve and vessels

Optic canal- optic nerve, ophthalmic artery

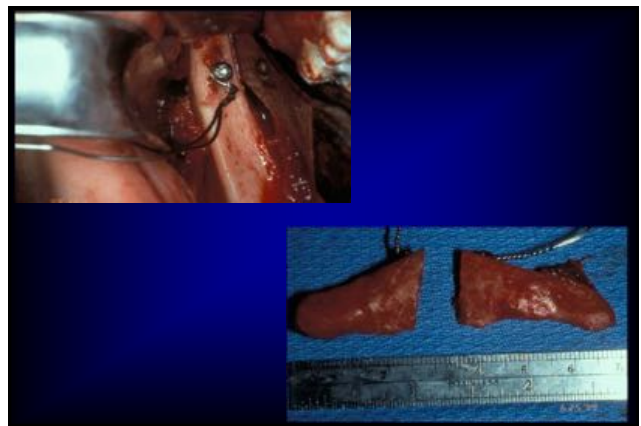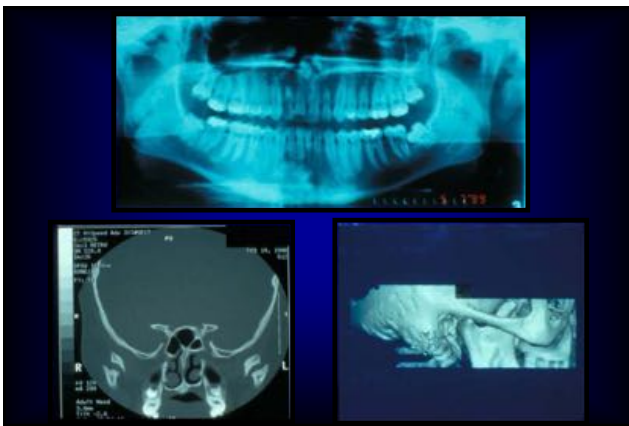
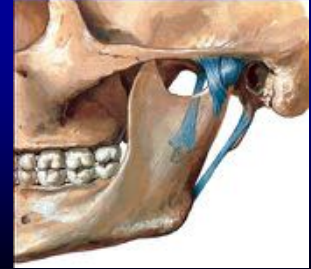
Superior orbital fissure- nasociliary, frontal, and lacrimal branches of V1, oculomotor nerve, trochlear nerve, abducens nerve, superior and inferior ophthalmic veins

Inferior orbital fissure- V2, zygomatic nerve, infraorbital vessels

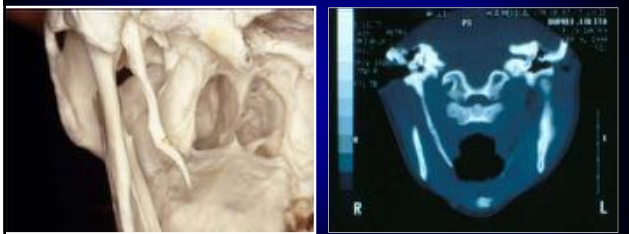

CORONOID HYPERTROPHY

- Limited range of motion (gradually developing)
- May be painless
- Most common in adolescent males

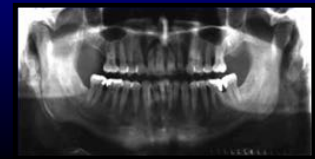
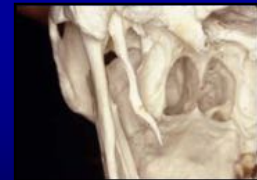

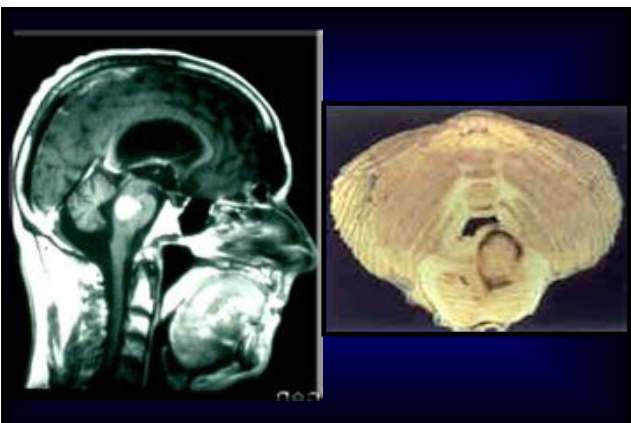
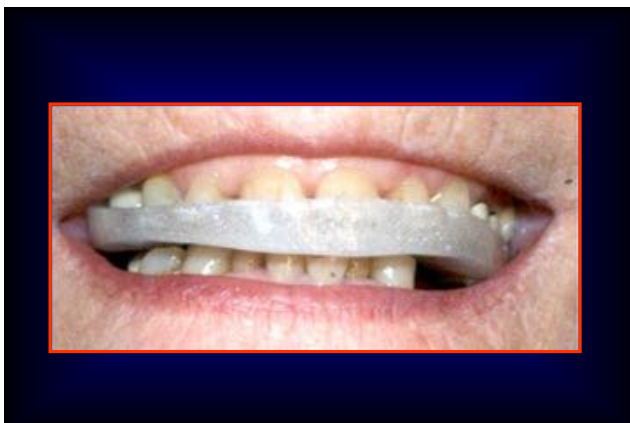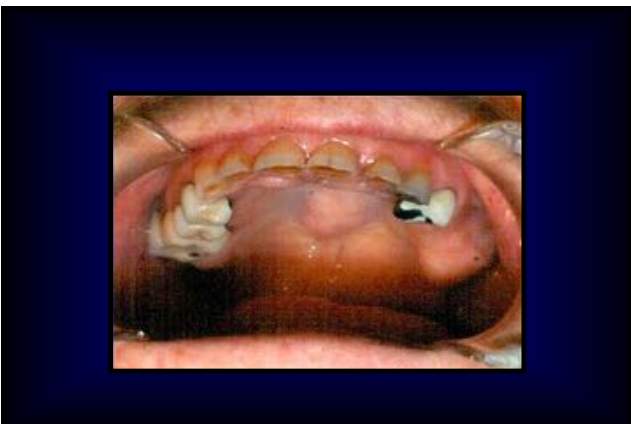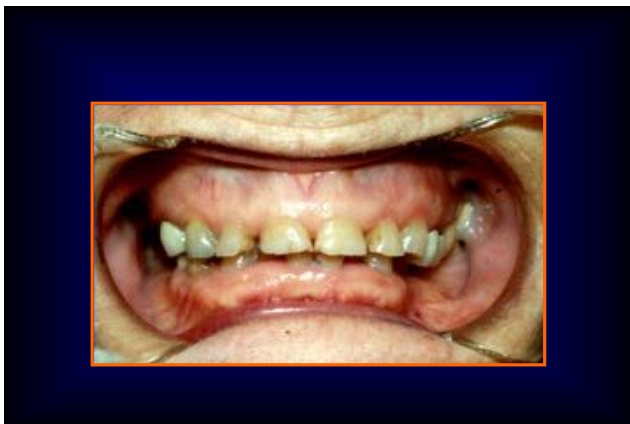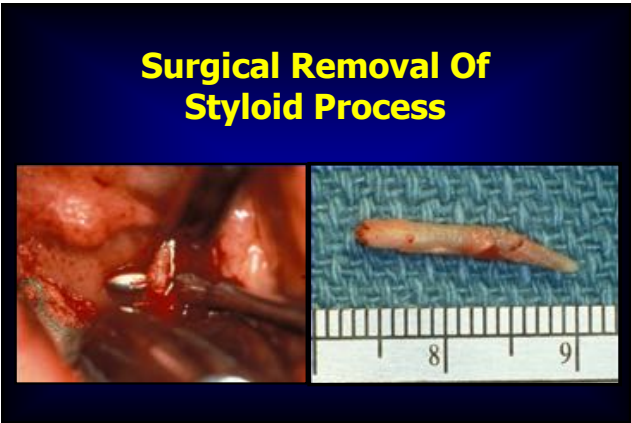
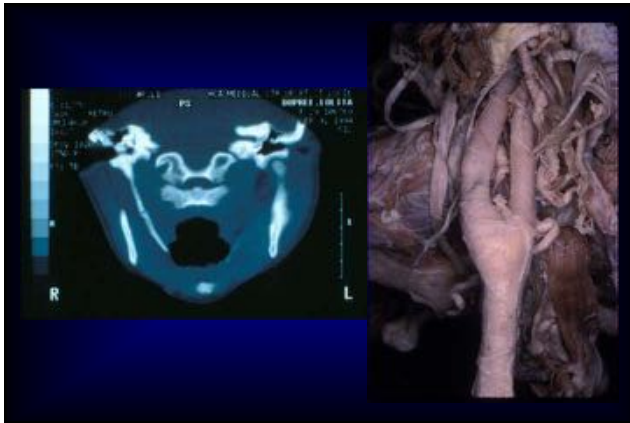EAGLE'S SYNDROME ELONGATED STYLOID PROCESS

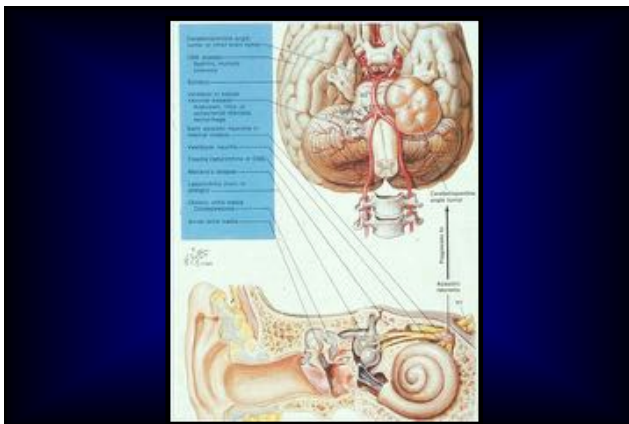
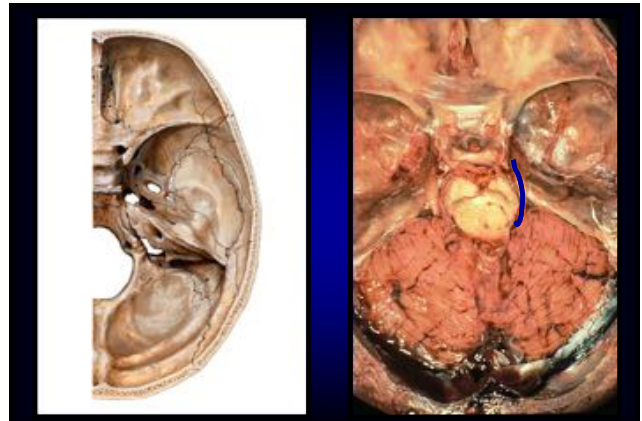
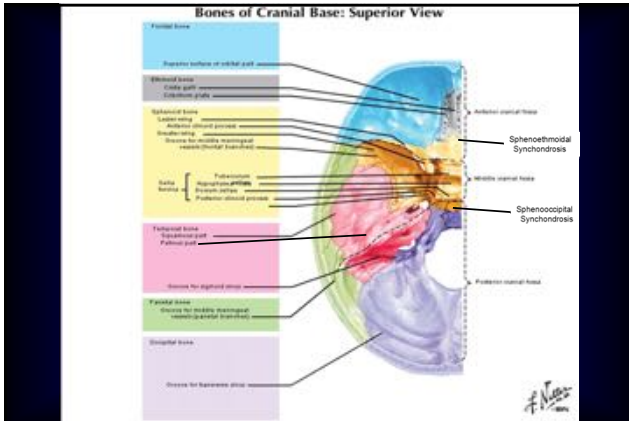


EAGLE'S SYNDROME

- Pain on swallowing
- Pain upon palpation of lateral pharyngeal wall
- Pain on turning head (associated dizziness?)



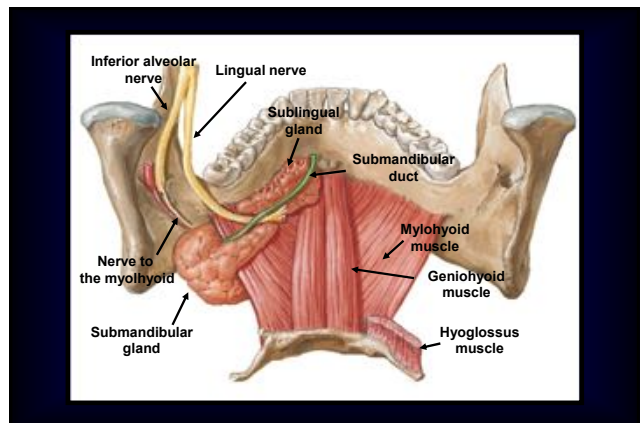


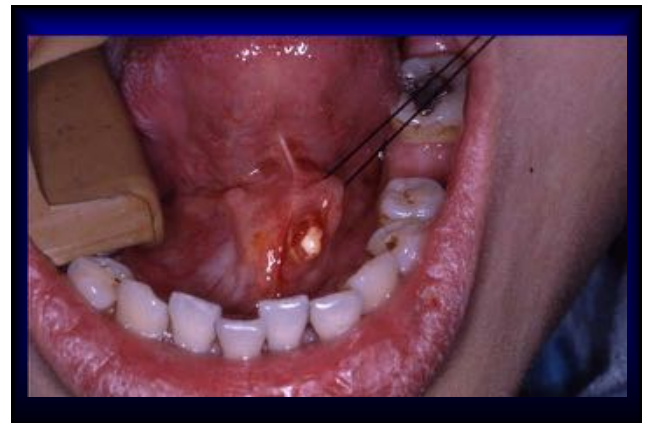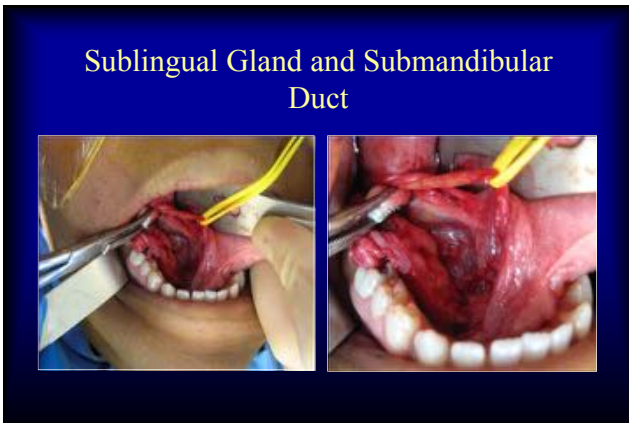
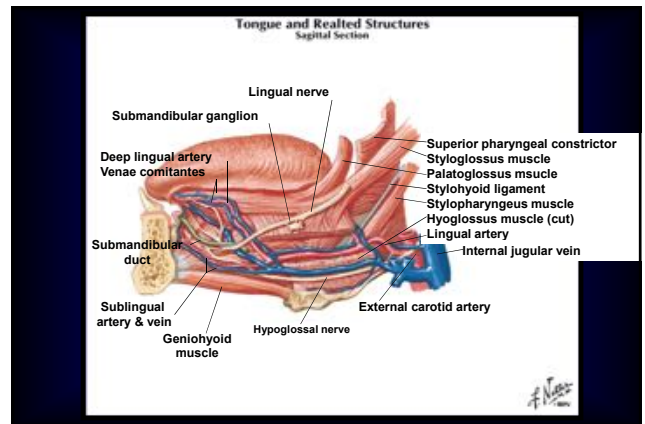
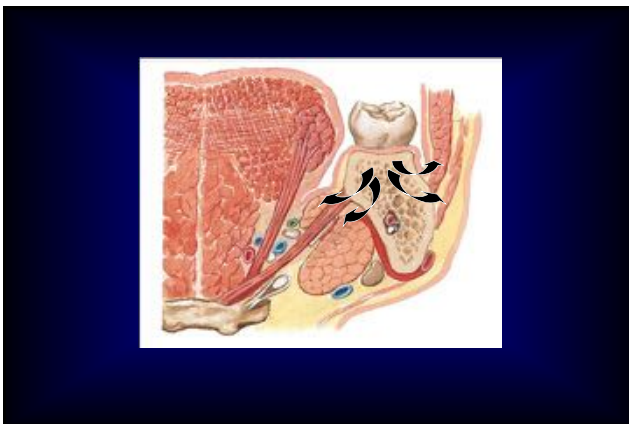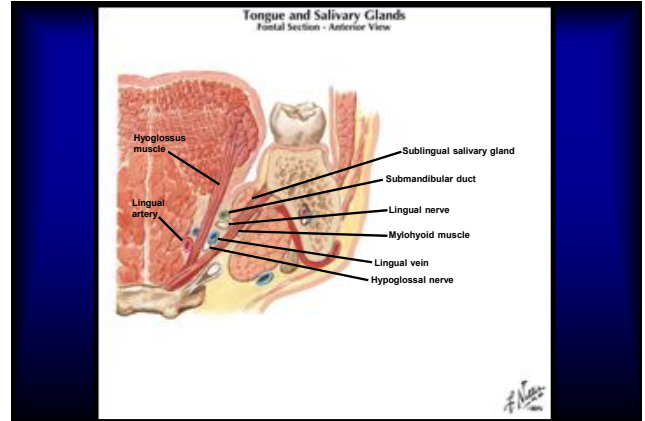


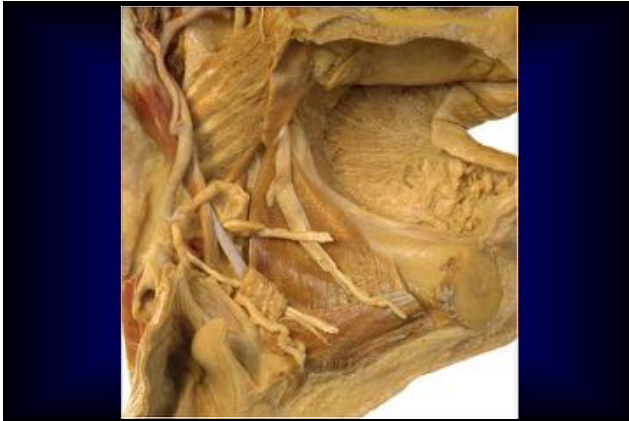SYMPTOMS & SIGNS OF ORGANIC DISEASE

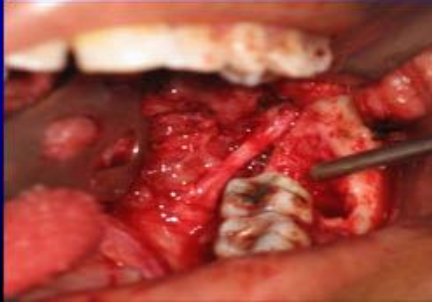- 👂 Sudden onset of headache
- 👂 Meningeal irritation ("stiff neck")
- 👂 Altered consciousness or cognition
- 👂 Papilledema or hemorrhage of the ocular fundus
- 👂 Pupils equal and/or poorly reactive
- 👂 Visual loss

ANATOMY OF THE ORAL CAVITY and FLOOR of MOUTH

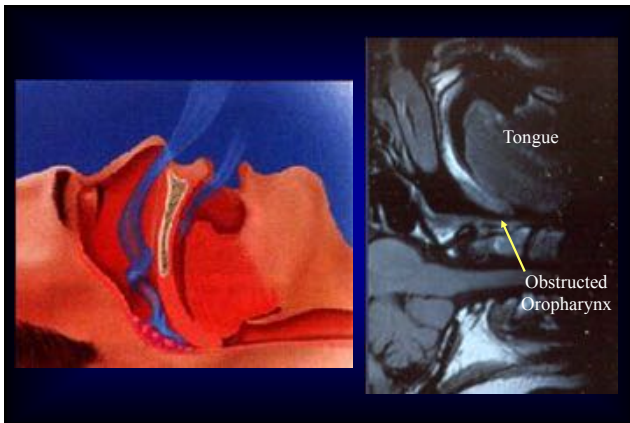
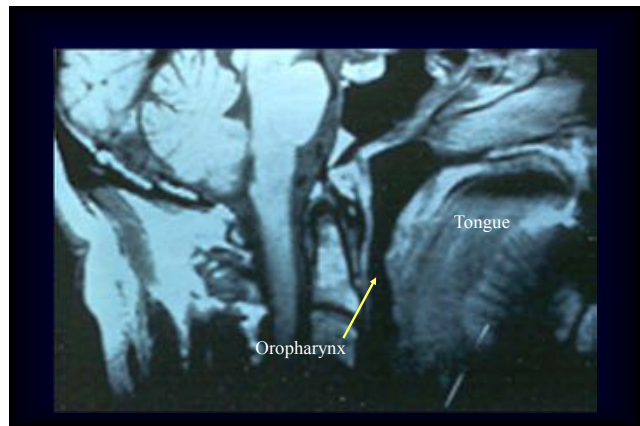
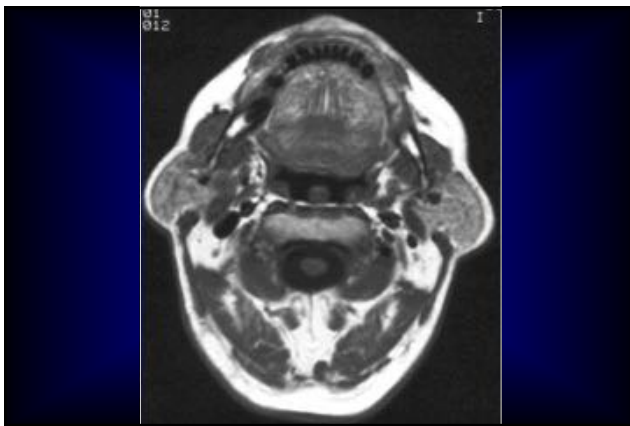
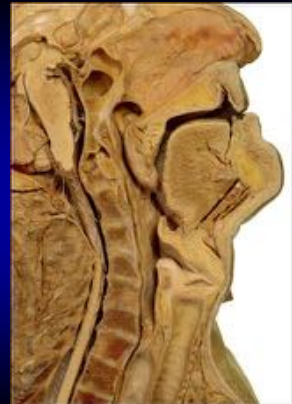



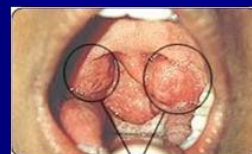Lingual Nerve



**Tongue position
and its relationship
to sleep-related
breathing disorders
such as sleep apnea...
genioglossus activity**

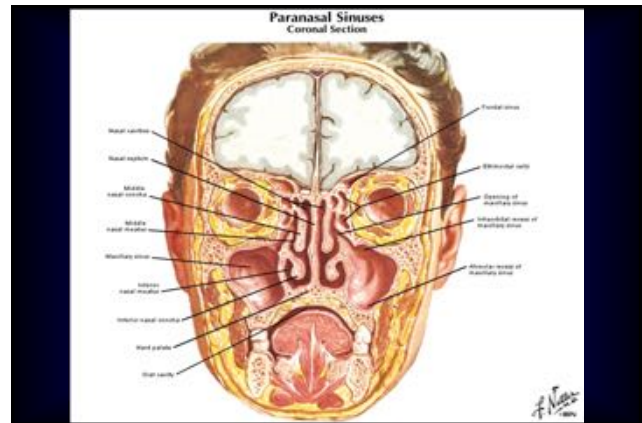
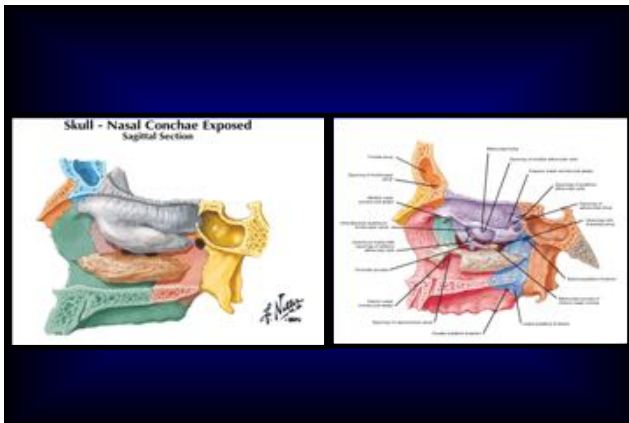
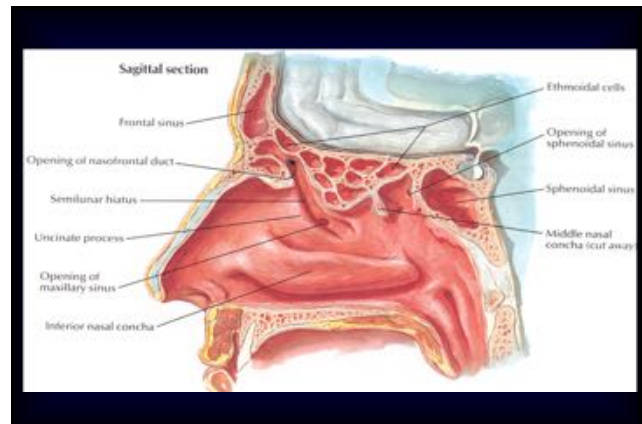
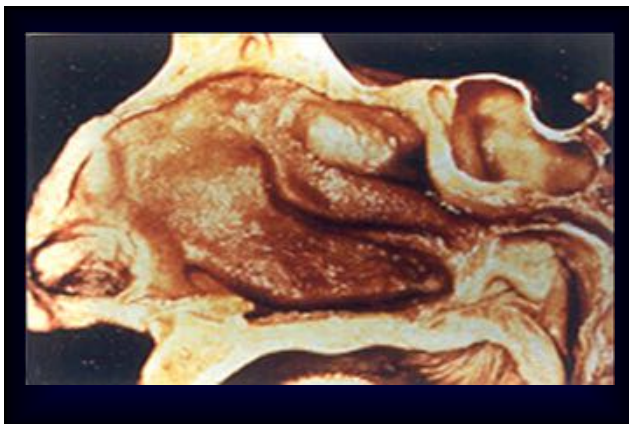
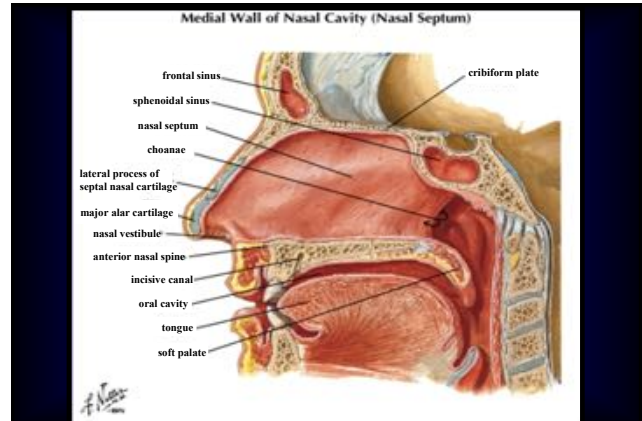
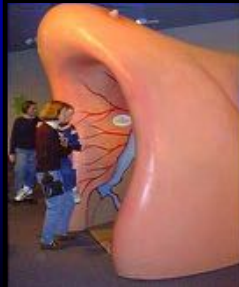

SLEEP-RELATED BREATHING DISTURBANCES



Enlarged & Inflamed Tonsils

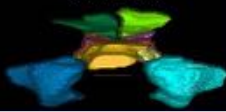
Nasal Cavity & Paranasal Sinuses



Paranasal Sinuses

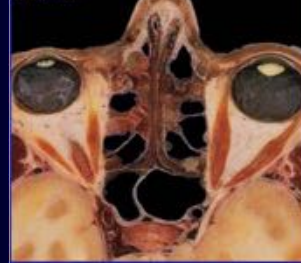
- Recesses of nasal mucosa growing into bones
- starts in late fetal period – after birth
- considerable variations: (interindividual & intraindividual)
 - onset and continuation of growth
 - size
 - shape
 - tiny cristae
 - small recesses

3D-reconstruction

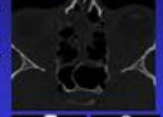


Ethmoid cells + sphenoid sinus

Axial section



Bone CT



Images of the Visible Human male

soft-tissue CT

pd - MRI

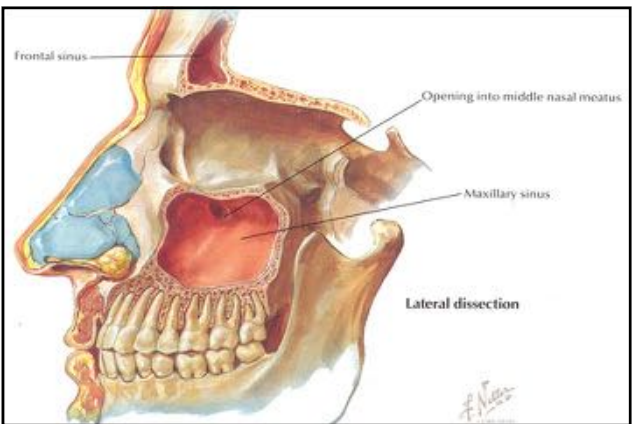
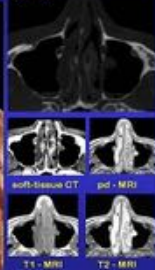
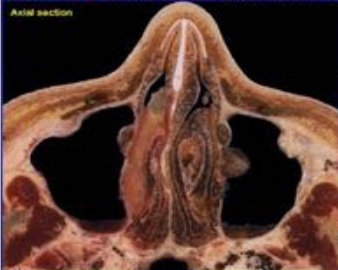T1 - MRI

T2 - MRI

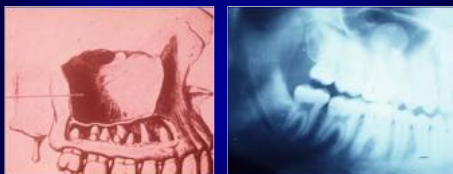Maxillary Sinus

Images of the visible human male

Bone CT

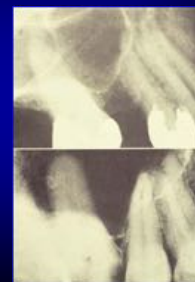


Mucous Retention Cyst

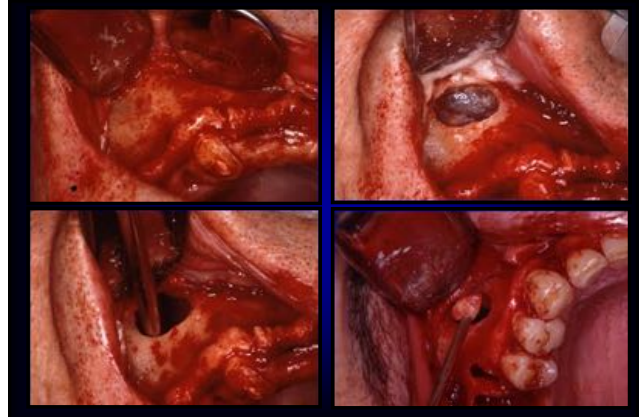
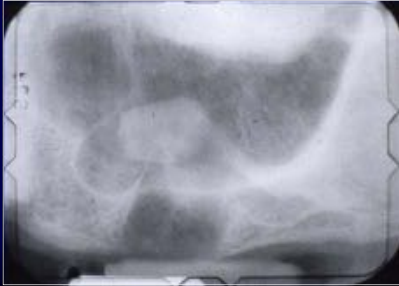


DISPLACED ROOT / TOOTH

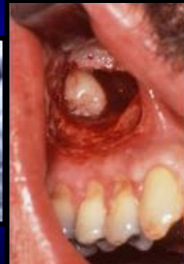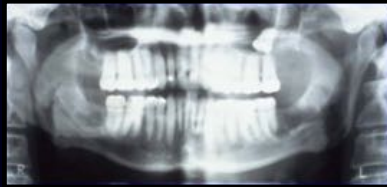1. Under flap
2. Sinus
3. Infratemporal Fossa



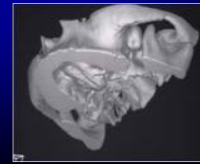
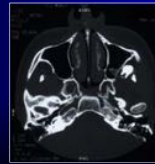
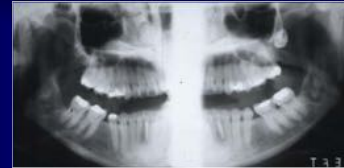
Root Tip in Maxillary Sinus



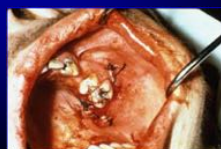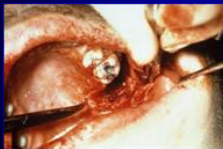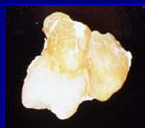Third Molar Displaced into Maxillary Sinus



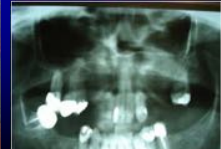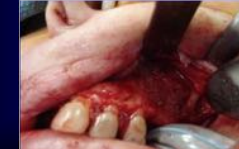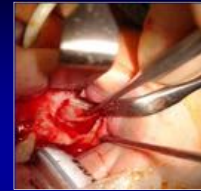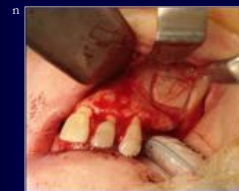Third Molar Displaced into Infratemporal Foss



Fractured Tuberosity with Maxillary Sinus Exposure



Sinus Lift with Iliac Bone Graft



PARANASAL ORIGINS OF PAIN

Paranasal Sinuses

Headache and facial pain are commonly related to infection, inflammation, and/or obstruction of the outflow of the tracts of the paranasal sinuses.

Acute / Chronic Sinusitis: PAINFUL COMPLICATIONS

- Mucosal inflammation and thickening in cases of acute sinusitis
- Partial or complete obstruction of sinus ostia
- Pressure sensation
- Maxillary mucoceles
- Osteomyelitis

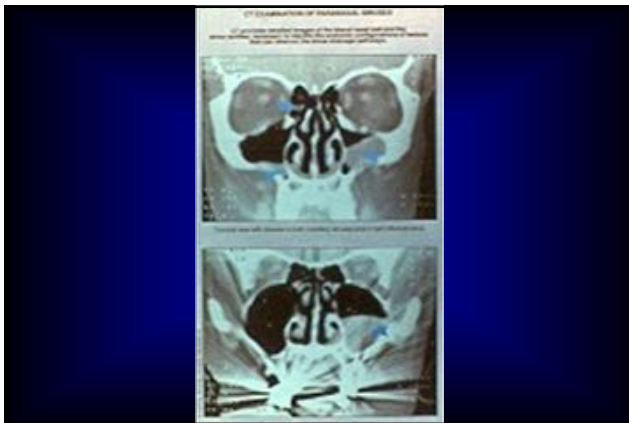
Acute / Chronic Sinusitis:

Sinus involved

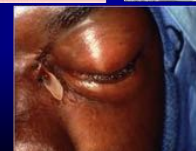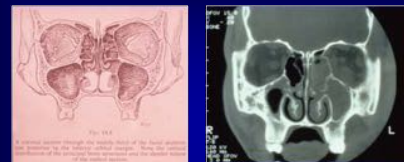- Sphenoid sinus
- Frontal sinus
- Ethmoid sinus
- Maxillary sinus
- Pansinusitis

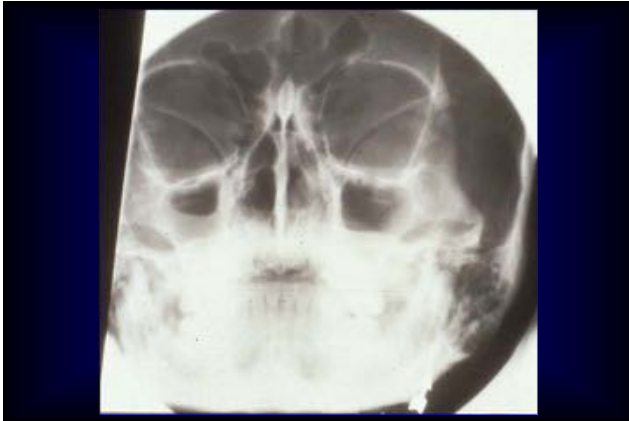
Site(s) of referral

- Vertex, other parts of the cranium
- Frontal region
- Between the eyes
- Maxilla, dental structures
- Pain may be coalescent, less localized, associated with frontal headaches, constant pressure



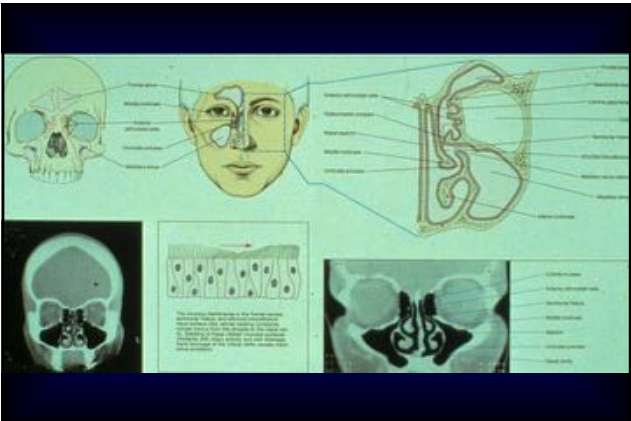
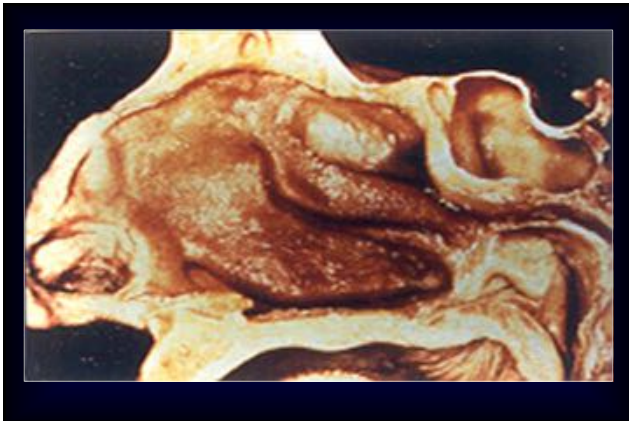
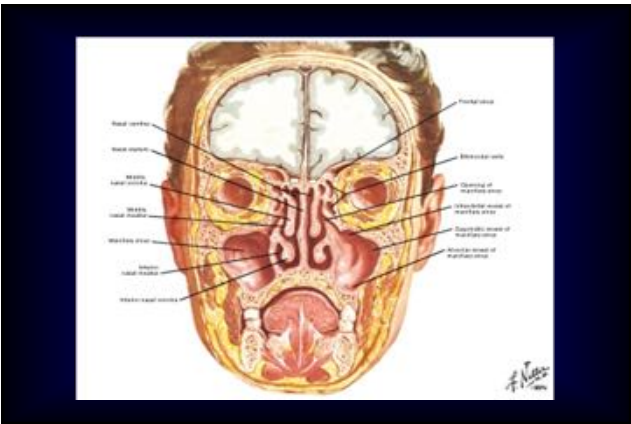
Pansinusitis

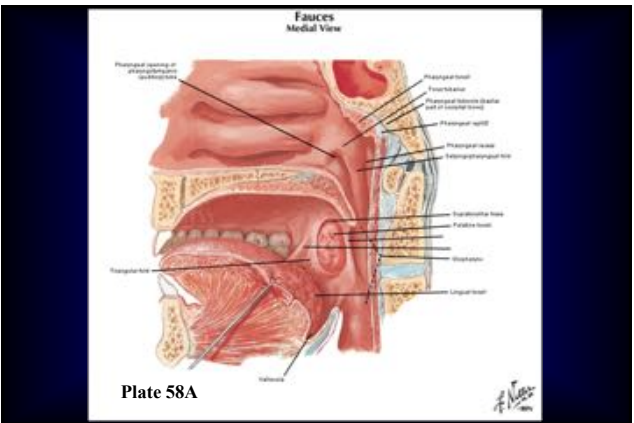

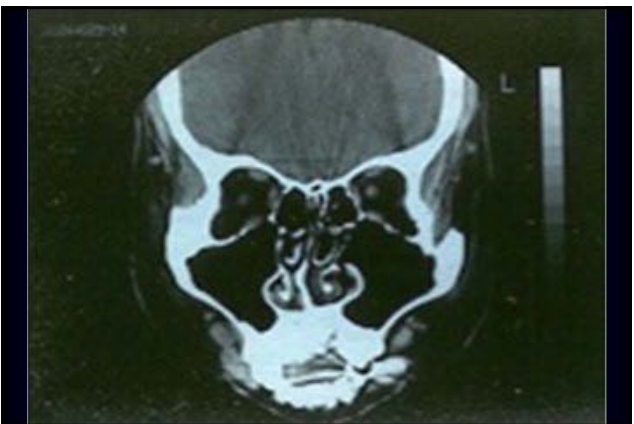
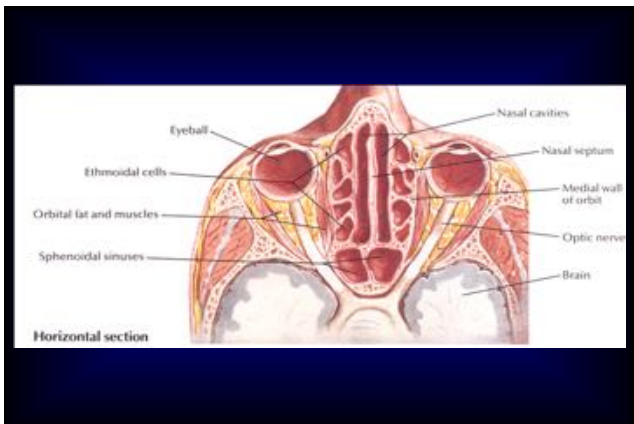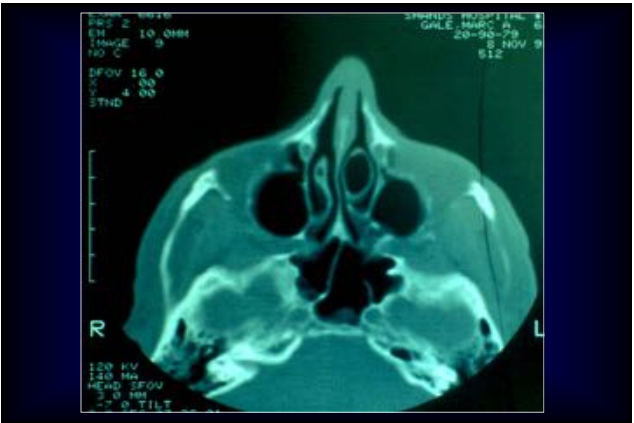
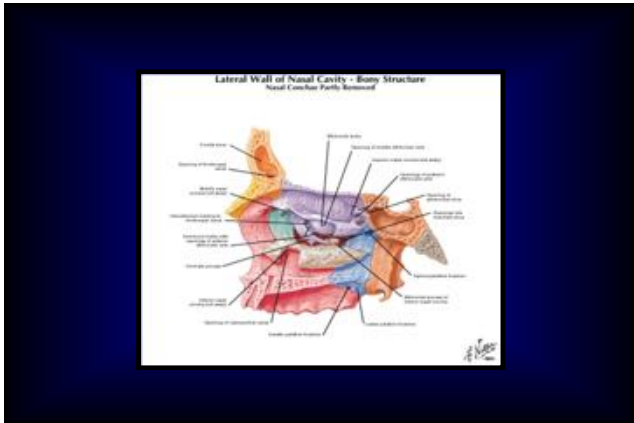


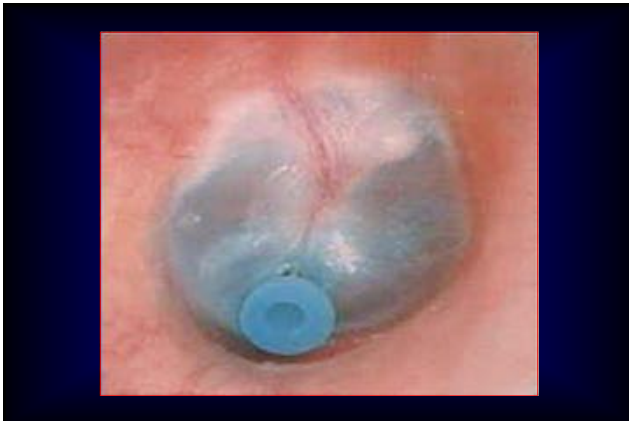

MUCOSAL CONTACT HEADACHE

- ## Mucosal Contact Headache
- Dull and aching
 - Diffuse peri-/retro-ocular, supraorbital pain
 - History of chronic maxillary sinusitis
 - Allergy prone
 - Associated with upper respiratory tract infection
 - Impedance of normal mucosal activity

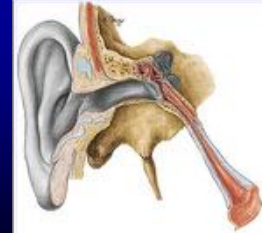





Ear Symptoms and TMJ

- Ear pain (Otalgia)
- Hearing changes-
stiffness most likely related to ET dysfunction.
- Tinnitus (ringing in ear)
- Dizziness



Tonic Tensor Tympani Phenomenon

- Hypertonia of medial pterygoid produces a concomitant reflex hypertonia of the tensor tympani muscle
- Tonic tensor tympani cannot initiate the reflex that increases the tonus of the tensor veli palatini muscle
- Failure of the eustachian tube to open during deglutition

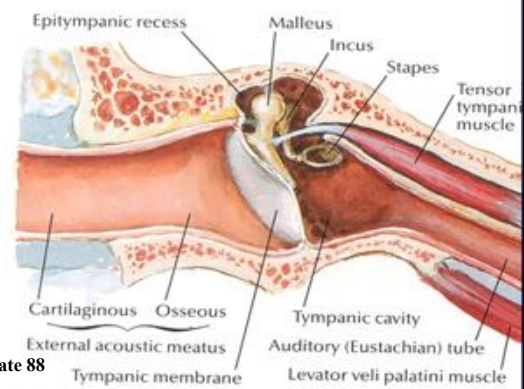


Plate 88

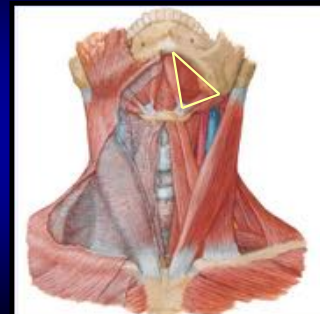
Otomandibular Syndrome

1 or more of the following without pathology in ENT exam plus 1 or more muscles symptomatic

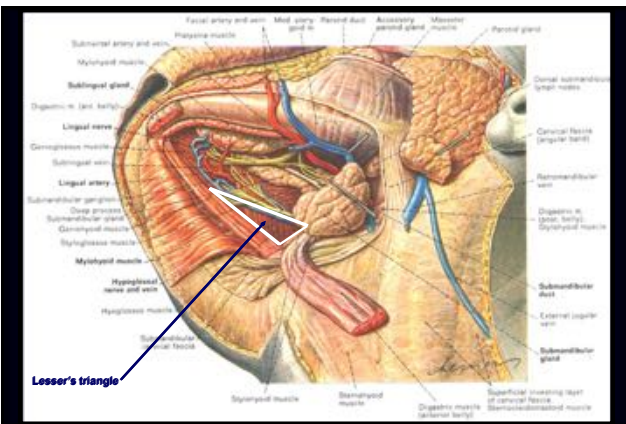
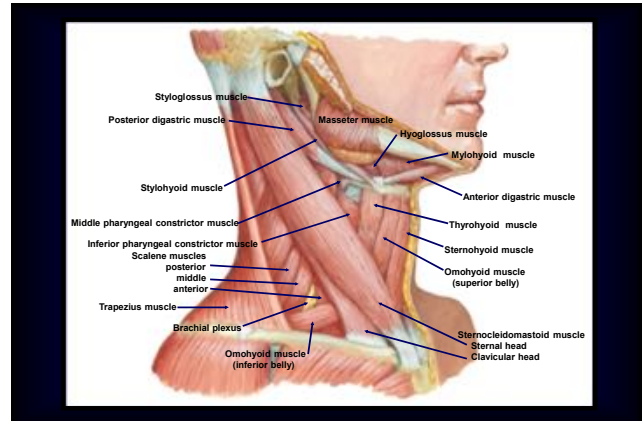
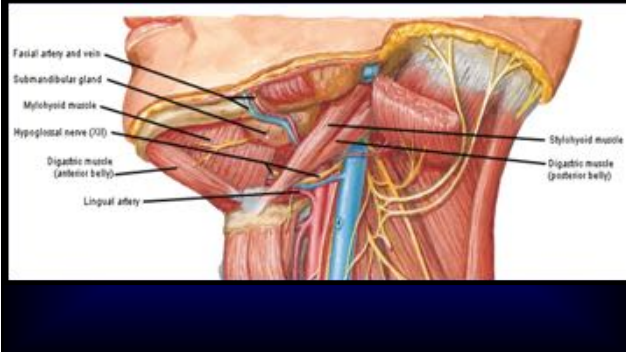
- Pain / fullness in and around ear
- Hearing loss
- Tinnitus
- Loss of equilibrium

Submandibular (Digastric) Triangle

- Superior
 - Inferior border of mandible
- Anterior
 - Superior border of anterior belly of digastric
- Posterior
 - Superior border of posterior belly of digastric



Digastric Triangle

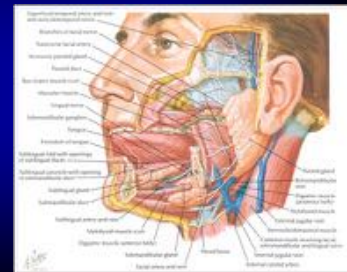


Major Salivary Glands

Parotid gland
-pure serous

Submandibular gland
-primarily serous

Sublingual gland
-primarily mucous



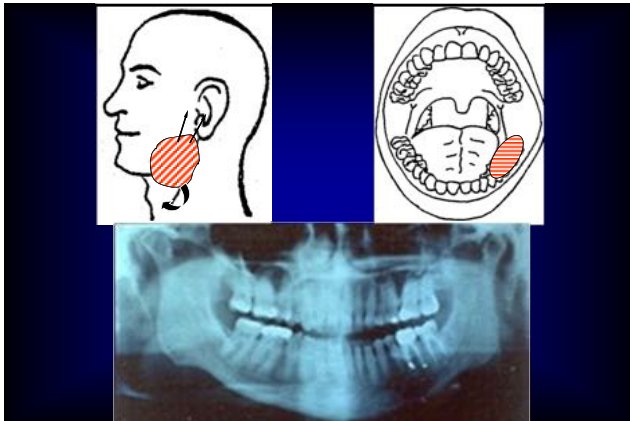
Patient: Betty

- 51 year old Caucasian female
- Medical history significant for:
 - left temporomandibular surgery X2
 - hypothyroidism



Patient: Betty

- Chief pain concern:
 - “I have pain in my jaw and throat when I eat. The pain radiates to my ear. It feels like a toothache.”



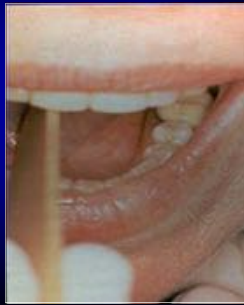Patient: Betty

- Aggravating factors:
 - chewing and drinking
 - certain aromas
- Alleviating/relieving factors:
 - none identified

Sialolithiasis

Diagnosis

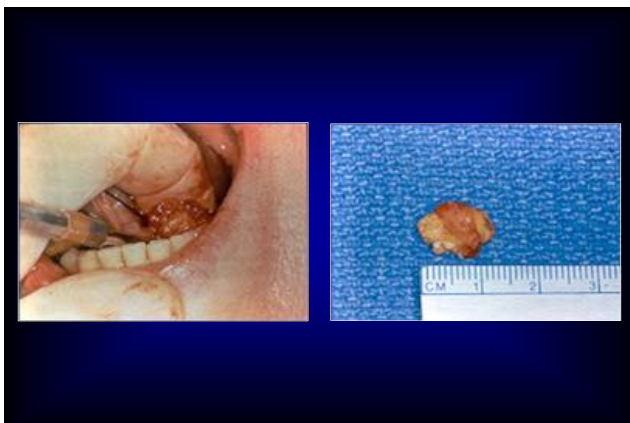
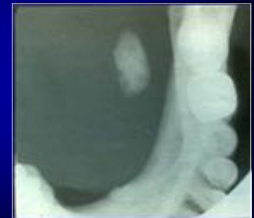- History
 - pain with salivation
- Inspection
- Palpation



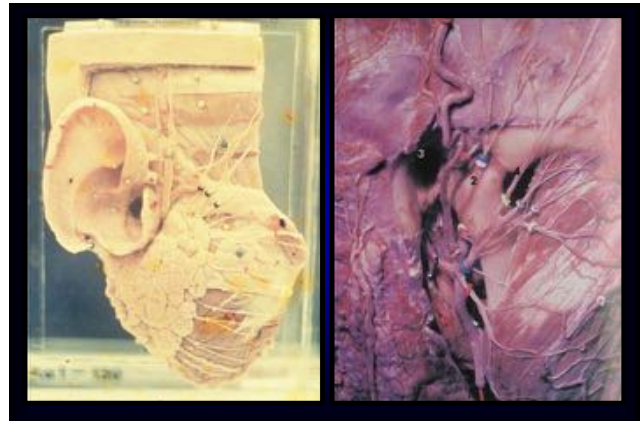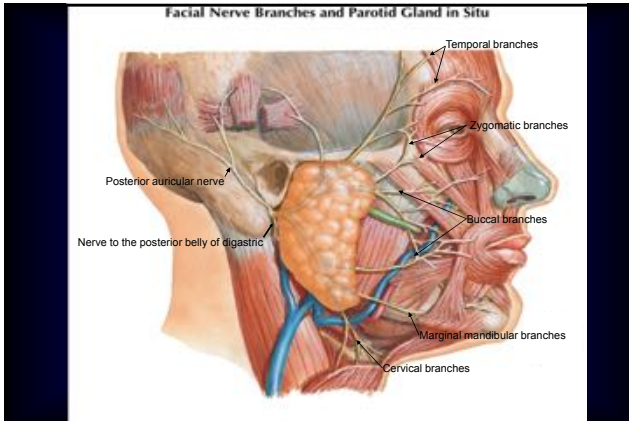
Sialolithiasis

Diagnosis


- Imaging
 - occlusal
 - lateral jaw
 - panoramic
 - sialogram



Superficial Face




BELL'S PALSY



- Cranial nerve VII paralysis
- May occur post-dental procedure
- Usually unilateral
- Gradual or sudden onset
- Viral relationship???

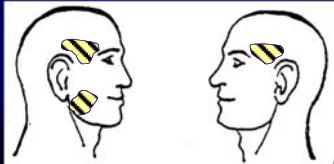
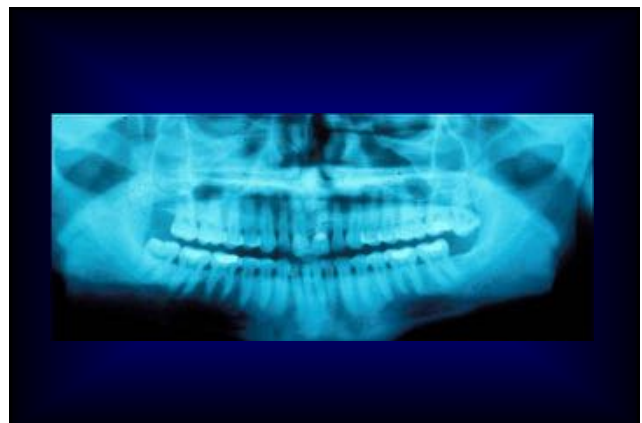
Patient: Juan

- 28 year old Hispanic male
- Medical history:
 - unexplained intermittent facial swelling and lymphadenopathy
 - previously treated with Pen VK 500 mg



Patient: Juan

- Chief pain concern(s):
 - “pain on the right side of my face; headaches in the temples; clicking in my right jaw; face feels numb and tingles on the right side; throbbing when I eat”

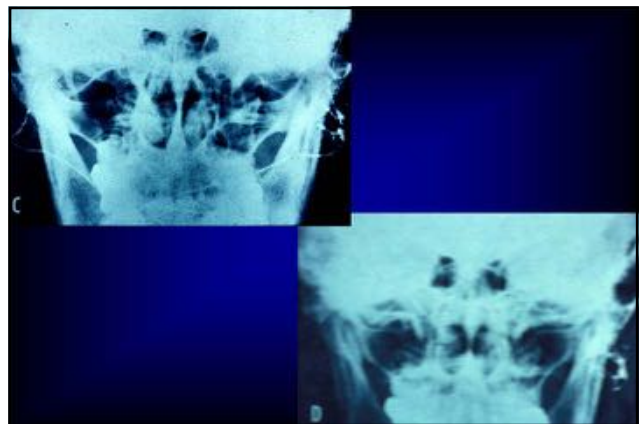
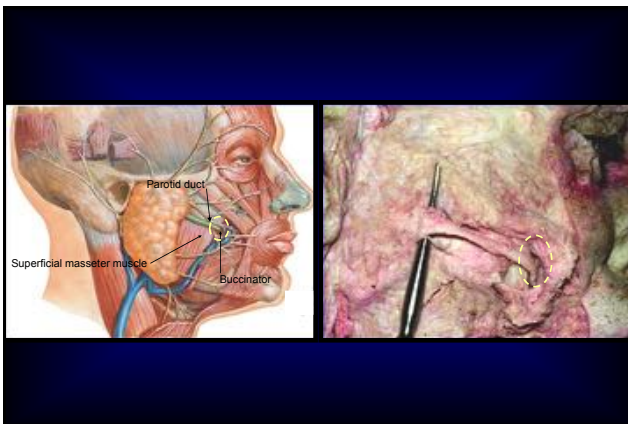


Patient: Juan

- Aggravating factors:
 - eating
 - opening wide
 - yawning
- Alleviating/relieving factors:
 - antibiotics (Pen VK 500)
 - analgesics (Ibuprofen)-- “takes the edge off”

Parotido-Masseteric Hypertrophy Traumatic Occlusion Syndrome

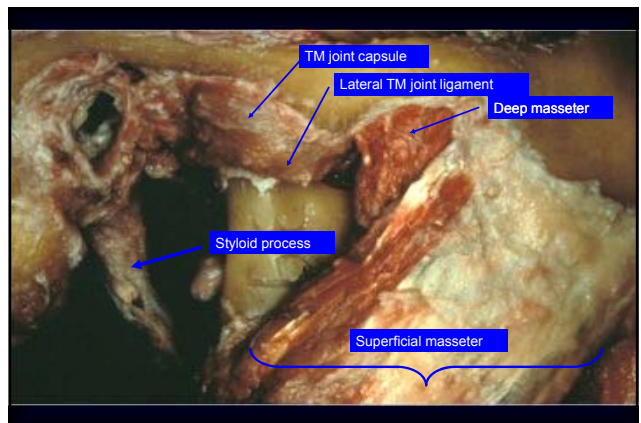
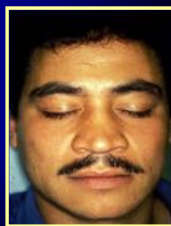- Parotid swelling
 - duct obstruction
 - pain
- Sialdochitis
 - bacterial infection due to retrograde travel of organisms from the oral cavity
- Traumatic occlusion

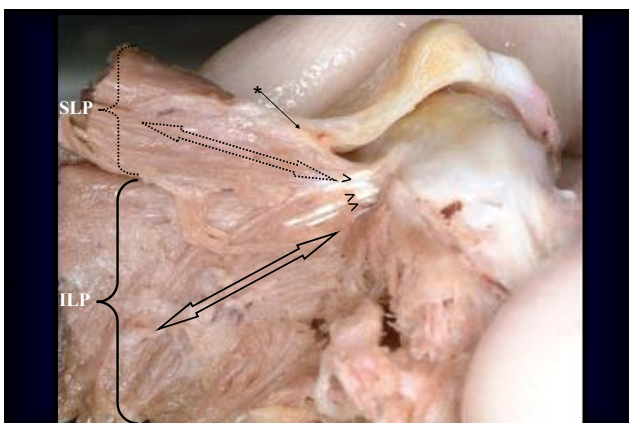
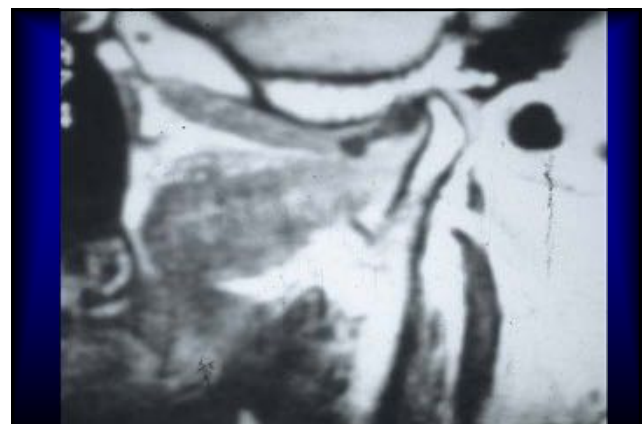
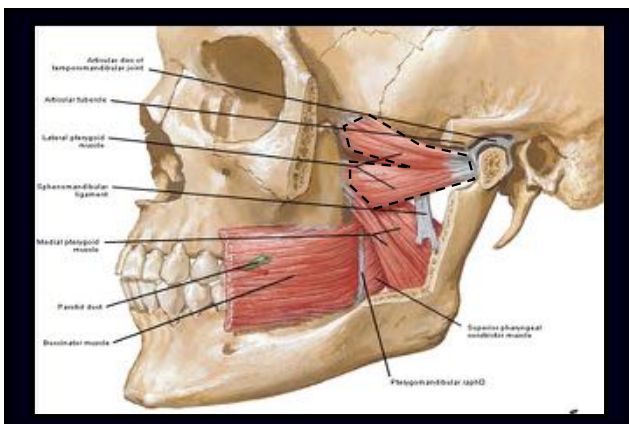
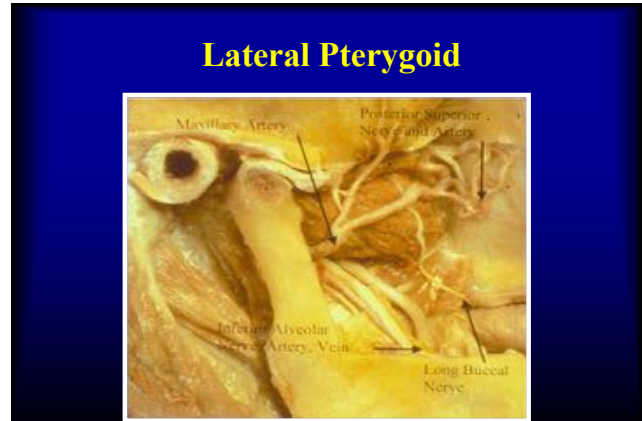
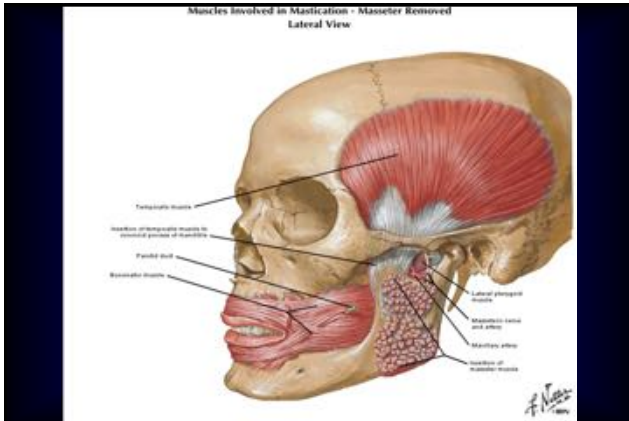


Parotido-Masseteric Hypertrophy Traumatic Occlusion Syndrome

Treatment

- Antibiotic therapy
- Analgesics
- Occlusal therapy
- Control parafunctional habits



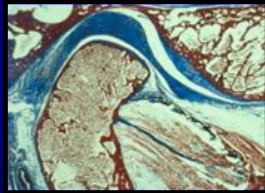


IMPORTANT ASSOCIATED STRUCTURES

Muscles involved in joint function

1. Muscles active on jaw opening-lateral pterygoid (inferior belly), suprahyoid and digastric muscles
2. Muscles active on jaw closure-temporalis, masseter, medial pterygoid muscles, lateral pterygoid (superior belly)
3. Excursive movements-lateral pterygoid

Functional Anatomy/Biomechanics of the Masticatory System



Temporomandibular Joint

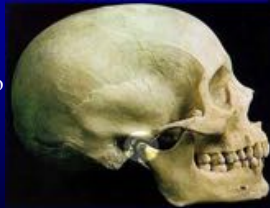Masticatory System: Unique Features

- Right and left function as one unit
- Articulating surfaces are fibrocartilaginous
- Articular disc separates the joint into two compartments
- Ginglymoarthrodial joint (hinge-gliding)



Masticatory System: Unique Features

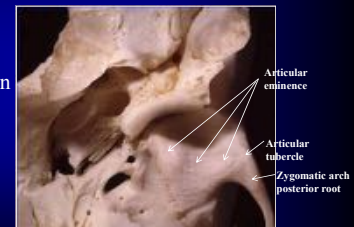
- Right and left function as one unit
- Articulating surfaces are fibrocartilaginous
- Articular disc separates the joint into two compartments
- Ginglymoarthrodial joint (hinge-gliding)
- Articulation has a rigid end point on closure of the teeth



OSSEOUS STRUCTURES

Glenoid fossa and articular eminence

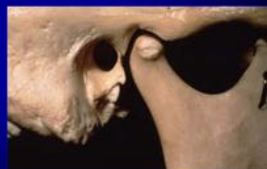1. Part of temporal bone
2. Glenoid fossa is concave structure covered with thin layer of fibrocartilage
3. Articular eminence is convex, posterior slope has an average angle of 60°



OSSEOUS STRUCTURES

Condyle

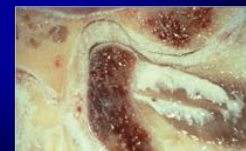1. Adult condyle is elliptical
2. Mediolateral dimension is about 20 mm and is twice the size of its antero-posterior width
3. Articular surface is covered by a layer of fibrocartilage



SOFT TISSUES

Articular Disk (Meniscus)

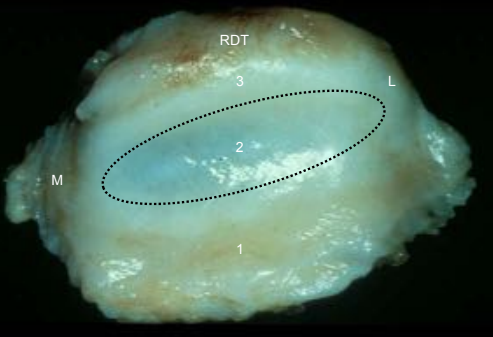
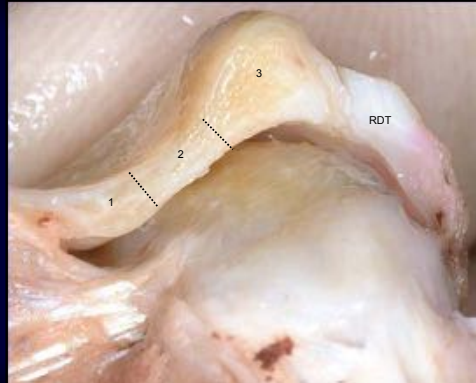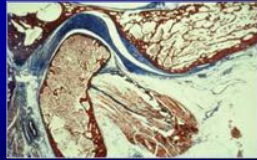
1. Bioconcave structure, divided the joint space into superior and inferior spaces
2. Attachments
 - a. Anterior-capsule and superior belly lateral pterygoid
 - b. Posterior-bilaminar zone (retrodiskal tissues)
 - c. Medial/lateral condyle



SOFT TISSUES

Articular Disk (Meniscus)

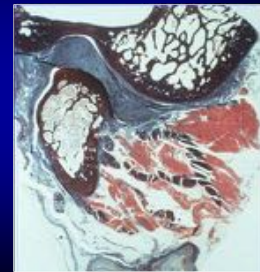
3. Made up of three zones
 - a. Posterior band – 3 mm thick
 - b. Intermediate zone – 1 mm thick
 - c. Anterior band – 2 mm thick
4. Consists of avascular connective tissue with some cartilaginous elements



SOFT TISSUES

Articular Disk (Meniscus)

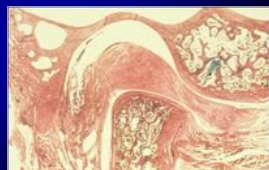
5. Functions
 - a. Load adapter
 - b. Fluid distribution
 - c. Divides joint space into two compartments allowing complex movements consisting of rotation and translation



JOINT SPACES

Synovial Membrane

1. Lines all non-loaded surfaces
2. Made up of intimal layer of cells 1-4 deep
 - a. Type A – phagocytic
 - b. Type B - secretory
3. Functions of synovial fluids
 - a. Lubrication
 - b. Nutrition
 - c. Maintains and protects articular cartilage



TM Joint Surfaces

Without lubrication

- relatively smooth
- have high surface energy
- may shear and rupture

TM Joint Biomechanics

The role of lubricant

- Reduces area of contact
- Reduces surface energy
- Reduces shearing



TM Joint Biomechanics

Lubrication

- Boundary
- Surface (weeping)

Synovial Organ

Functions

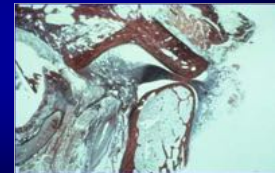
- Semi-permeable membrane which allows for adjustment of pressures within the TM joint.

Bauer W, et al. Physiological Rev 1940; 20:272-312

JOINT SPACES

Intra-articular Joint Pressures

1. Resting (-4 mm Hg)
2. Opening (-54 mm Hg)
3. Closing (+64 mm Hg)



Synovial Fluid

As the intra articular pressure increases, the viscosity of the synovial fluid decreases.

This may impair the lubricating ability of the fluid... thus increasing the frictional resistance.

TM Joint Mechanical Stress

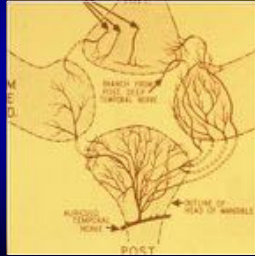
Increased sustained TM joint pressures result in:

- impaired diffusion
- local ischemic changes
 - may lead to cell death
 - free radical formation
- decreased lubrication
 - increased frictional resistance

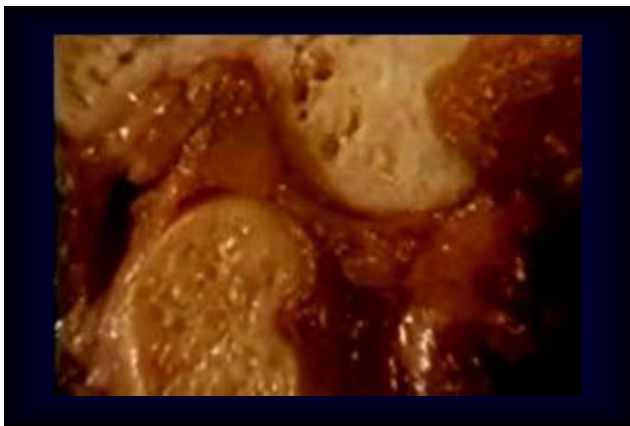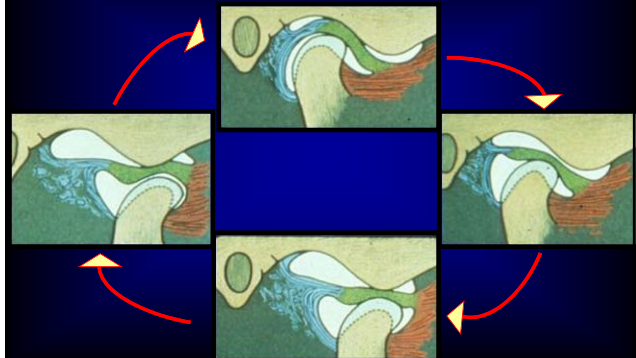
IMPORTANT ASSOCIATED STRUCTURES

Sensory Innervation of the TMJ

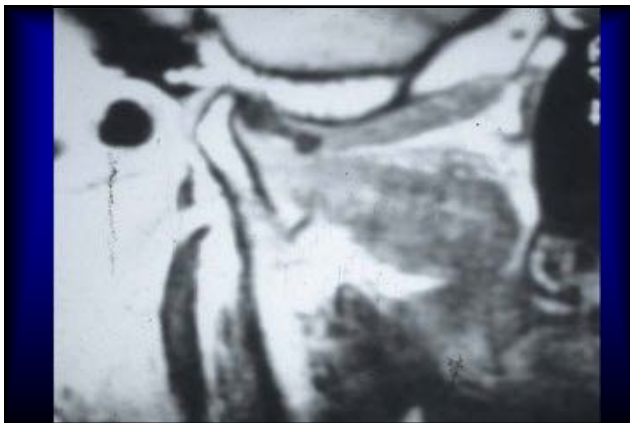
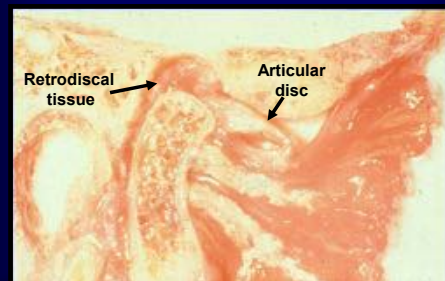1. Branches of the 3rd division of the trigeminal nerve
 - a. Auriculotemporal
 - b. Masseteric
 - c. Deep temporal
2. Fibers for pain and proprioception are mainly located in the bilaminar zone and capsule



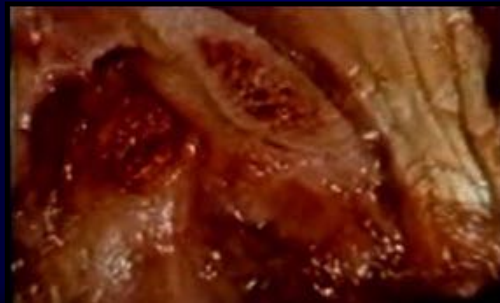TM Joint: Normal Biomechanics



Articular Disc Displacement



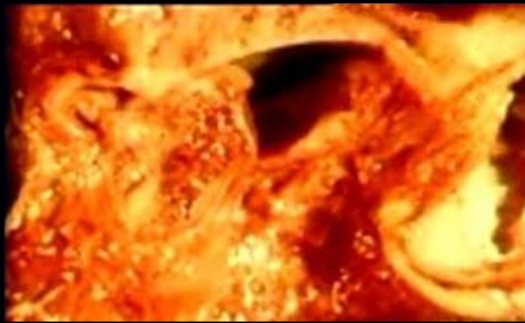
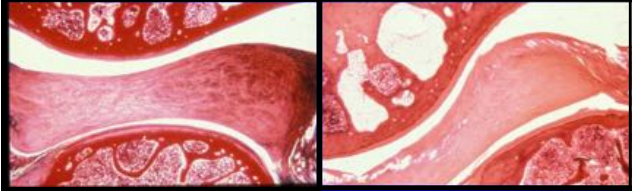
Articular Disc Displacement With Reduction



Degenerative temporomandibular joint disease is the result of maladaptation to increased joint loading.



Westesson, Rohlin 1984
Axelson, et al. 1992, 1993
Stegenga, et al. 1992
deBont, Stegenga 1993



Thank you!

hgremi@lsuhsc.edu

Henry A. Gremillion, DDS
1100 Florida Avenue
New Orleans, LA 70119

